

Cleidocranial Dysplasia- A Case Report

Akhilanand Chaurasia

Department of Oral Medicine & Radiology, Faculty of Dental Sciences, King George Medical University, Lucknow
E-mail: chaurasiaakhilanand49@gmail.com

ABSTRACT

Cleidocranial dysplasia is a rare congenital disease. It is characterized by autosomal dominant inheritance pattern which is caused due to mutations in the Cbfa1 gene (Runx2) located on chromosome 6p21. It primarily affects bones which are formed by intra-membranous ossification and have equal sex distribution. It is also known as Marie and Sinton disease, Mutational dysostosis and cleidocranialdysostosis. The skeletal deformities of cleidocranial dysplasia are characterized by partial or complete absence of clavicles, late closure of the fontanels, presence of open skull sutures and multiple wormian bones. This rare syndrome is of utmost importance in dentistry due to presence of multiple supernumerary teeth, facial bones deformities and deranged eruption patterns. We are reporting a classical case of cleidocranial dysplasia in 20 year old patient.

Keywords: *Cleidocranial dysplasia, Marie and Sinton disease, Mutational dysostosis, Cleidocranialdysostosis, Autosomal dominant*

Access this article online	
Quick Response Code:	Website: www.innovativepublication.com
	DOI: 10.5958/2395-6194.2015.00009.0

INTRODUCTION

Cleidocranialdysostosis is a rare congenital defect primarily affecting bones which undergo intra-membranous ossification i.e. calvarial bones and clavicles^{1,2,3}. This rare entity follows an autosomal dominant inheritance caused by mutations in the Cbfa1 gene also called Runx2 (Runt related transcription factor 2) located on the short arm of chromosome 6p21. The Cbfa1 is essential for osteoblast and odontoblast differentiation as well as for bone and tooth formation⁴. In 1898, Pierre Marie and Paul Sinton were the first to describe this rare anomaly⁵. Since the first report in 1898 more than 1000 cases have been reported in English Literature. Cleidocranialdysostosis is also known as Marie and Sinton disease, Mutational dysostosis and Cleidocranial dysplasia⁶. Cleidocranialdysostosis is a relatively uncommon disorder with a prevalence of 0.5 per 100,000 live births⁷. The skeletal abnormalities commonly include clavicular aplasia or hypoplasia, bell-shaped thorax, enlarged calvaria with frontal bossing and open fontanelles, wormian bones, brachydactyly with hypoplastic distal phalanges, hypoplasia of the pelvis with widened symphysis pubis, enlargement of the frontal and occipital bones, supernumerary teeth, delayed eruption of permanent dentition and short stature^{8,9}. Shortened or absent nasal bones, paranasal sinus abnormalities, thickening of some segments of the calvaria, small maxillae and delayed union of the

mandibular symphysis are less common findings of cleidocranial dysostosis^{1,10,11}.

Dental findings in cleidocranialdysostosis are characterized by a decreased eruptive force of both primary and permanent dentition, prolonged retention of primary teeth¹² and an increase in odontogenesis leading to an excessive number of supernumerary teeth¹³. The clinical findings of cleidocranialdysostosis although present at birth are often either missed or diagnosed at a much later time. Cleidocranialdysostosis may be identified by family history, excessive mobility of shoulders and radiographic pathognomonic findings of the chest, skull and jaws. Here we are presenting a case of classical case of cleidocranialdysostosis.

CASE REPORT

A 24-year-old patient (**Fig.1**) reported to Department of oral medicine and radiology with presenting complaint of fabrication of prosthesis for missing teeth. The patient had a missing anterior tooth which was causing social embarrassment to him. There was no significant past medical and dental history. The patient had normal gait and posture. He had normal intelligence and well oriented to surroundings. His vitals were normal. There was no sign of pallor, cyanosis and lymphadenopathy noted. He was thin, poorly built and short stature. On extra-oral examination brachycephalic head, frontal bossing, underdeveloped maxilla, depressed nasal bridge (**Fig.1**) was noted with concave facial profile with competent lips (**Fig.2**).

He had shrugged shoulders with more than normal mobility of the shoulder girdle i.e. shoulder could be brought to the midline of chest (**Fig.3**). On intra-oral examination there was missing teeth from right maxillary canine region to left maxillary canine region (**Fig.4**) while mandibular canine and second premolar was missing in left side (**Fig.5**). There was class III malocclusion with underdeveloped maxilla and prognathic mandible (**Fig.2**). On the basis of clinical

findings a provisional diagnosis of cleidocranial dysplasia has been suggested. The patient is advised for radiological investigations by panoramic radiograph, PA skull, PA chest, Lateral cephalogram, PA pelvis, hand-wrist radiograph and CT of Head. The panoramic radiograph (Fig.6) shows multiple impacted teeth along with supernumerary teeth and rounded gonial angles. PA skull (Fig.7) shows widened anterior fontanel and posterior fontanels with presence of wormian bones, top of the metopic suture, sagittal suture and large mandible. PA chest (Fig.8) radiograph shows thinning and hypoplasia of the clavicles and bell shaped rib-cage. Lateral cephalogram (Fig.9) shows widened anterior and posterior fontanel with presence of wormian bones, nonfusion of sagittal, coronal and lambdoid suture of skull bones, persistent metopic sutures and large mandible with impacted teeth and supernumerary teeth. Radiograph of pelvis (Fig.10) with both hips shows delayed ossification of bones forming symphysis pubis with diastasis of pubic symphysis, hypoplastic iliac bones, bilateral short femoral neck causing coxovera deformity. Radiograph

of both hands (Fig.11) shows a bilaterally elongated second metacarpal bone, short hypoplastic distal phalanges of hand bilaterally and pointed terminal tufts. CT of head shows multiple abnormal intra sutural bones are noted typically around lambdoid suture suggestive of wormian bones (Fig.12). The sagittal suture is widened (Fig.13) however coronal suture is fused (Fig.14). Anteriorfontenelle (Fig.15) and posterior fontenelle (Fig.12) are seen opened up and widened. Bilateral zygomatic arch is hypoplastic. The palate is high arched and multiple supernumerary teeth were noted with broad mandible. There was persistent metopic suture with agenesis of frontal sinuses (Fig.16). The nasal bridge is flattened and nasal septum is deviated towards right side with convexity to right with spur formation (Fig.16). There was decreased pneumatization of bilateral mastoid air cells (Fig.16). On the basis of clinical and radiological findings a final diagnosis of cleidocranial dysplasia has been reached. A multidisciplinary approach has followed involving oral and maxillofacial surgeon, orthodontists and prosthodontics for the management of this patient.

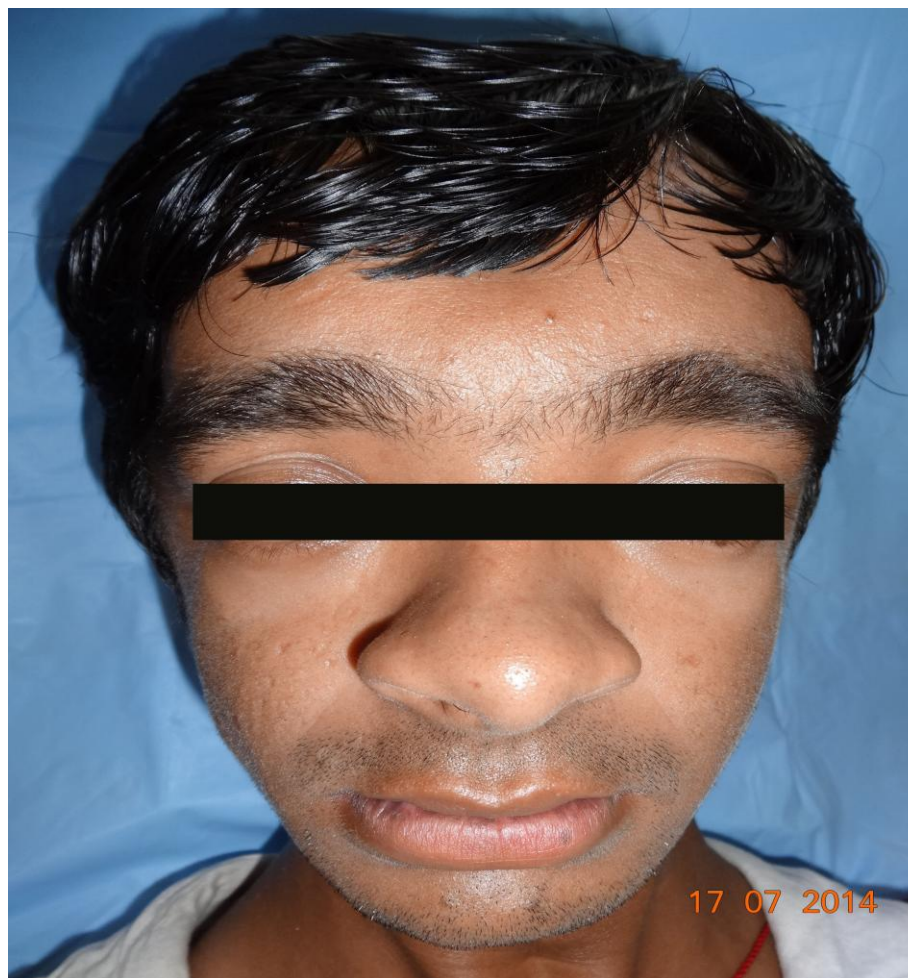

Fig. 1: Profile photograph of patient showing brachycephalic head, frontal bossing, underdeveloped maxilla and depressed nasal bridge

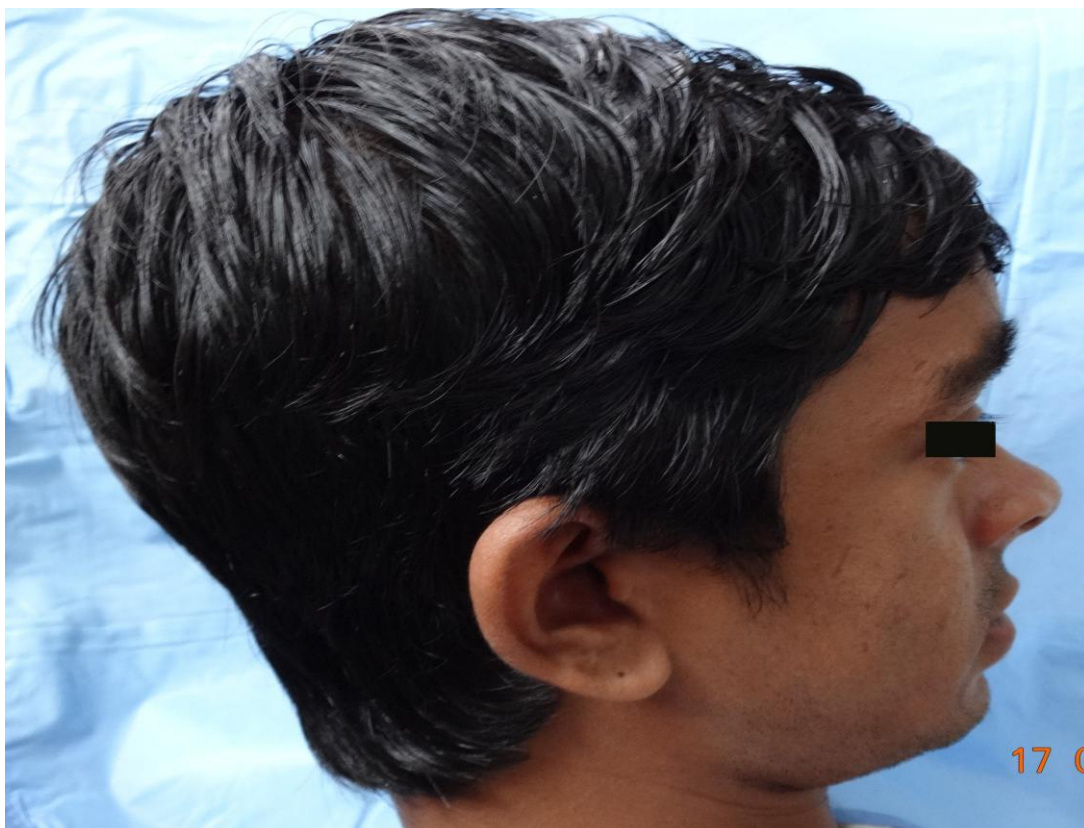

Fig. 2:Lateral view of patient showing concave facial profile with competent lips

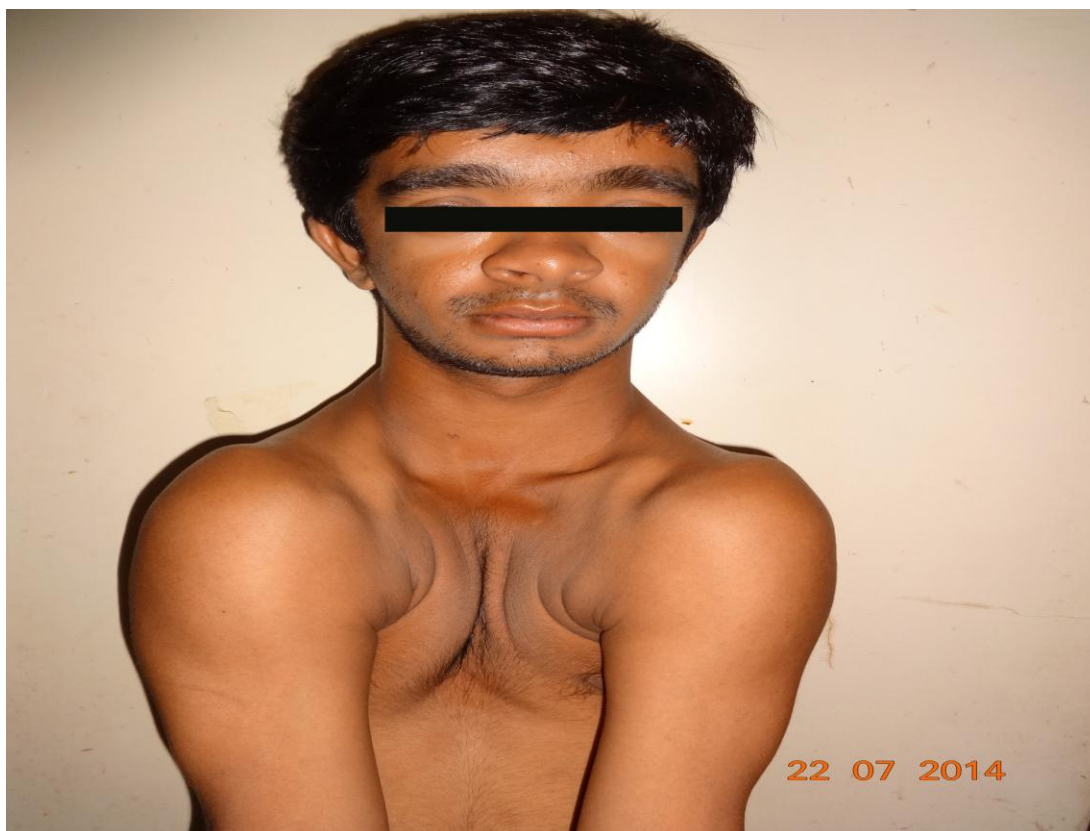

Fig. 3: Frontal view of patient showing shrugged shoulders with more than normal mobility of the shoulder girdle i.e. shoulder could be brought to the midline of chest

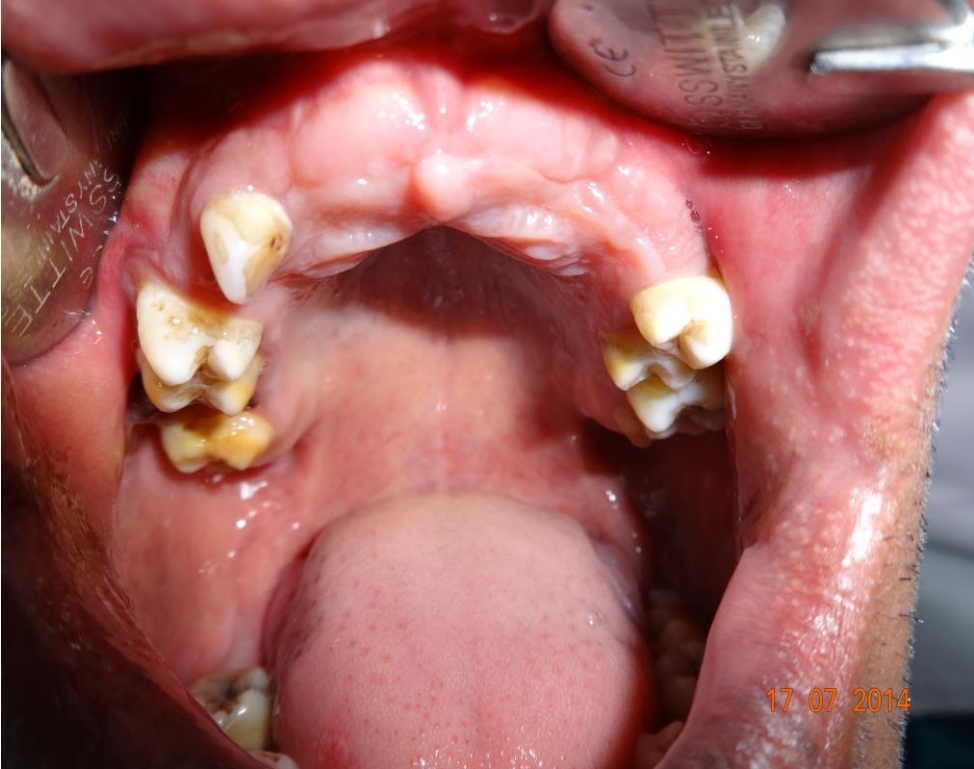

Fig. 4: Intra-oral view showing missing teeth from right maxillary canine to left maxillary canine region

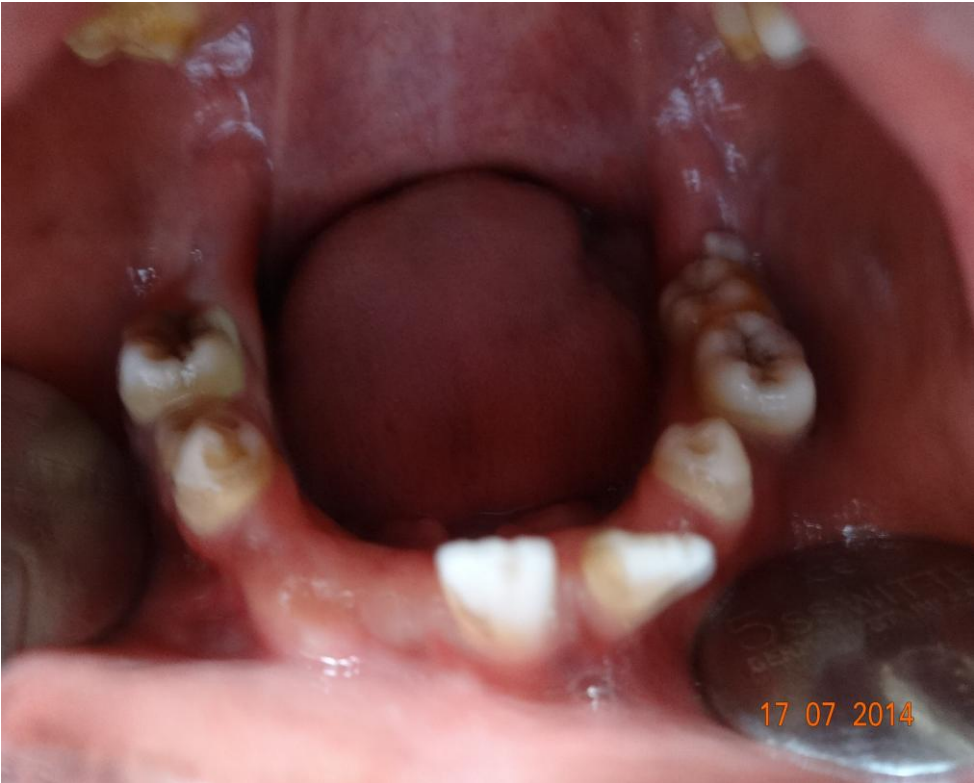

Fig. 5: Intra-oral view showing missing mandibular canine and second premolar in left side

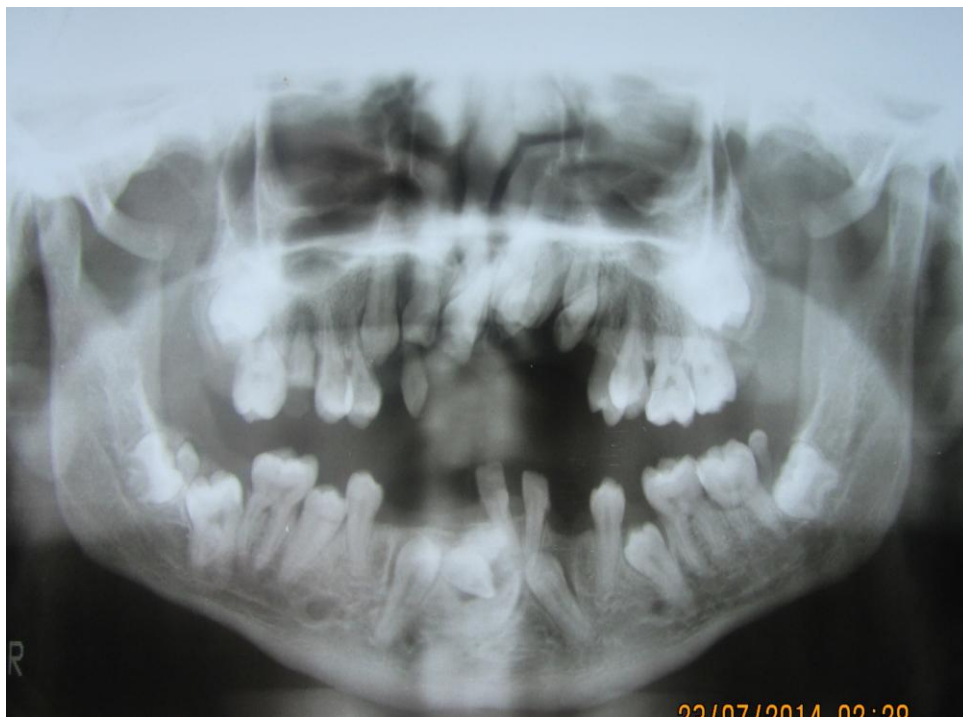

Fig. 6: Orthopantomogram showing multiple impacted teeth along with supernumerary teeth and rounded gonial angles

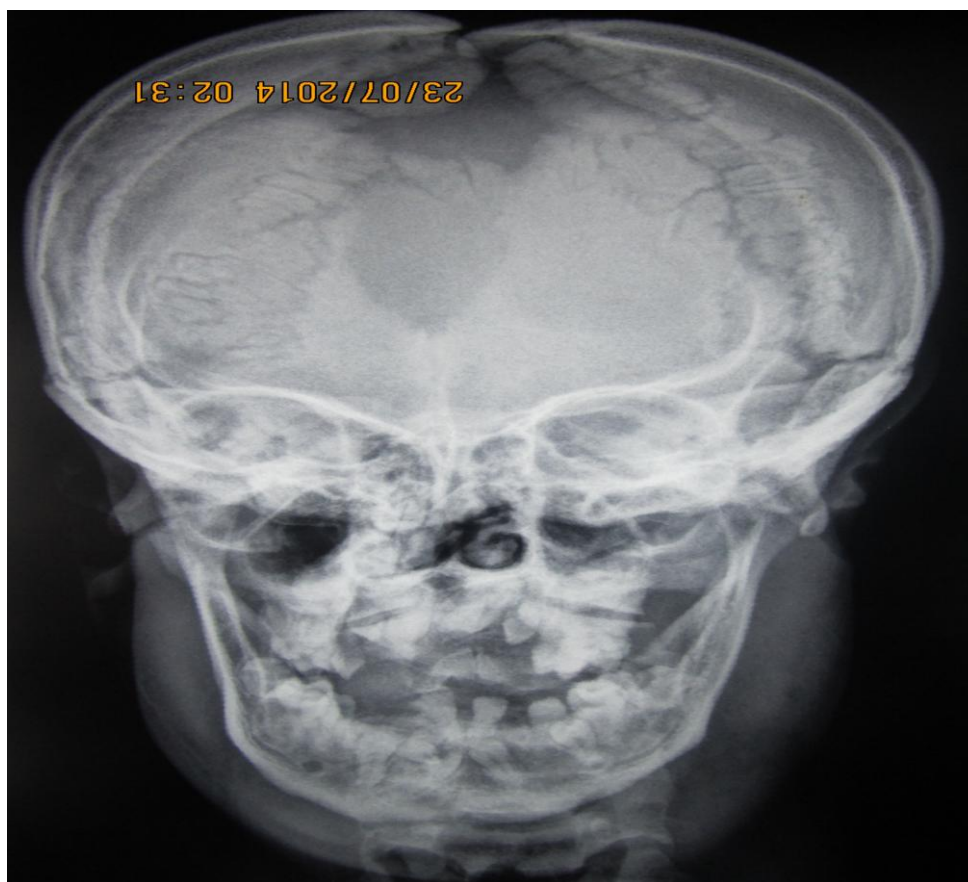


Fig. 7: PA skull showing widened anterior fontanel and posterior fontanelles with presence of wormian bones, top of the metopic suture, sagittal suture and large mandible

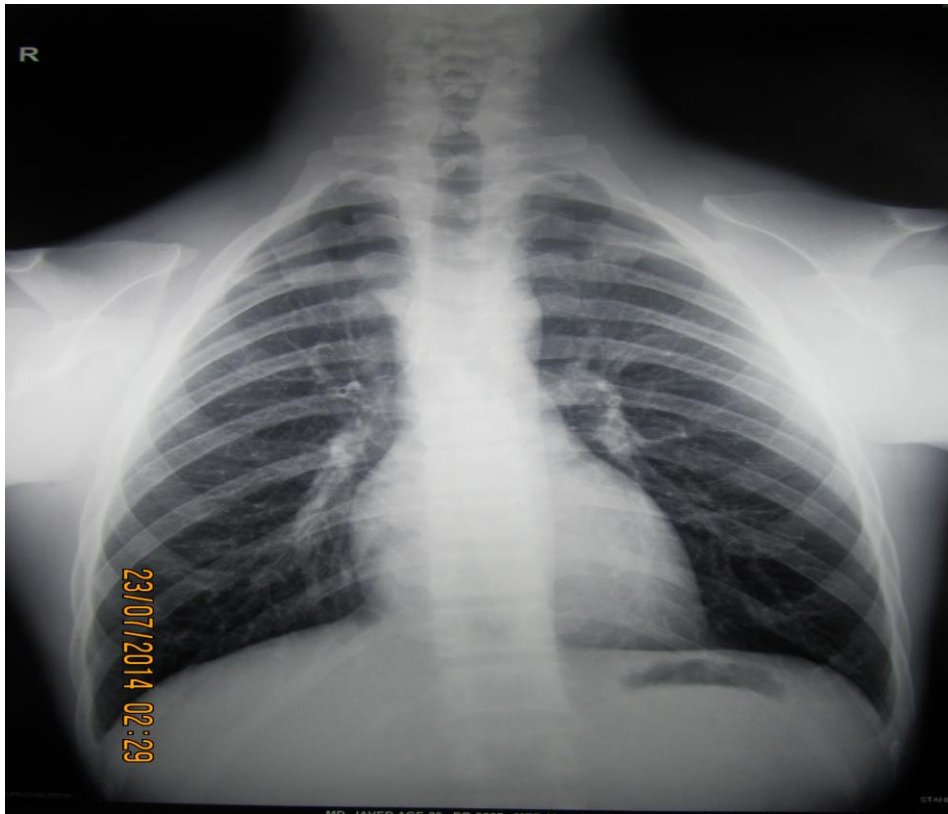


Fig. 8: PA Chest radiograph showing thinning and hypoplasia of the clavicles and bell shaped rib-cage

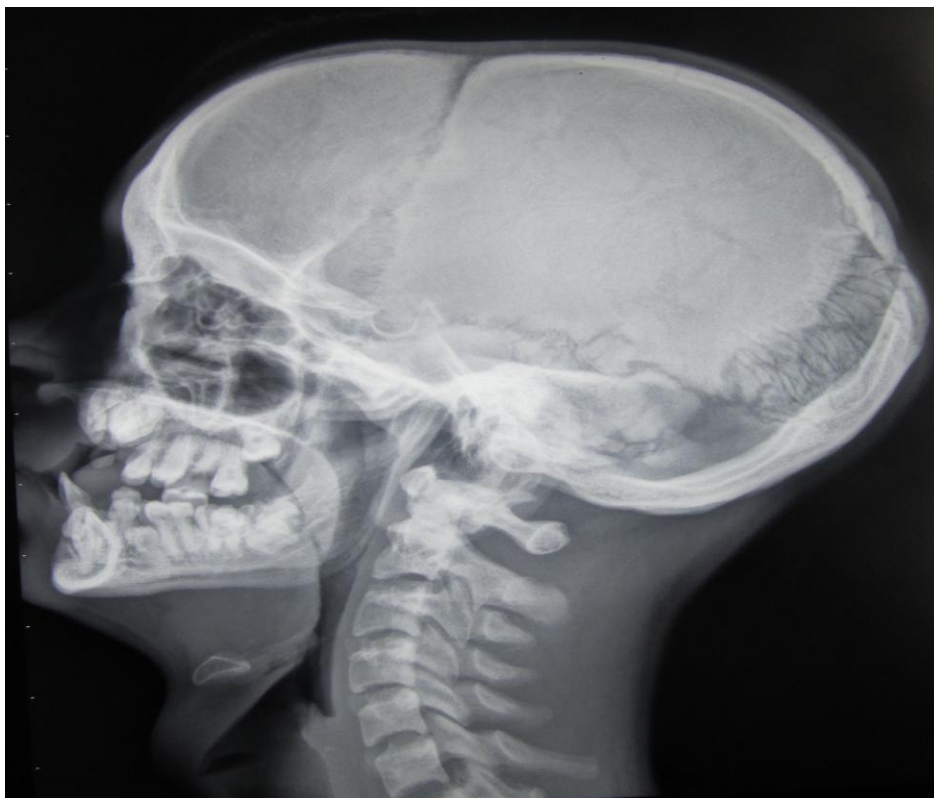

Fig.9:Lateral ceph showing widened anterior and posterior fontanel with presence of wormian bones, nonfusion of sagittal,coronal and lambdoid suture of skull bones, persistent metopic sutures and large mandible with impacted teeth and supernumerary teeth

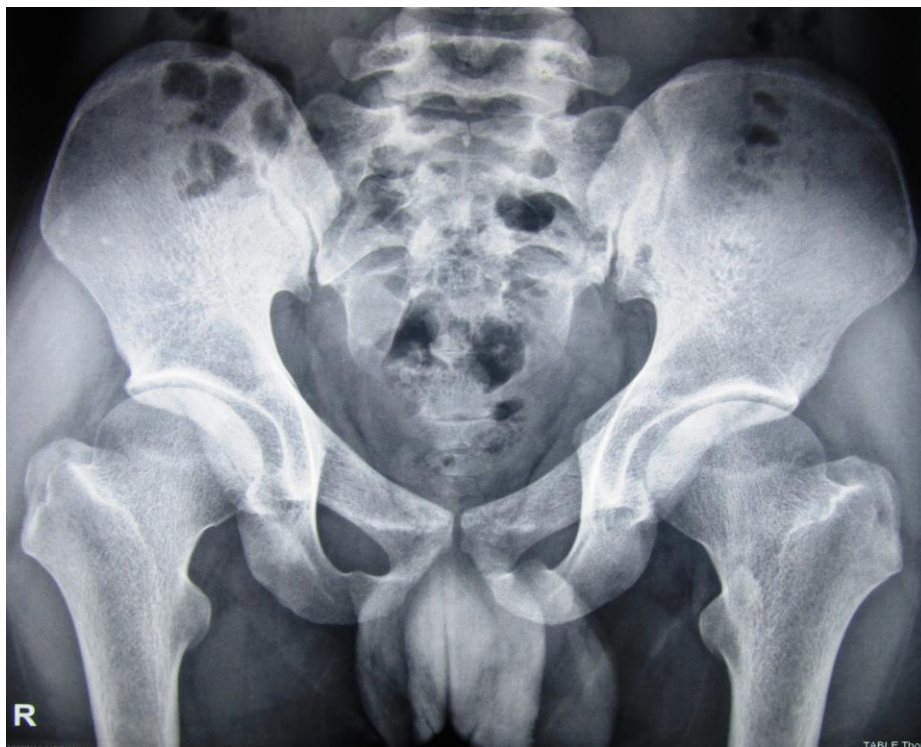

Fig. 10: PA Radiograph of pelvis with both hips showing delayed ossification of bones forming symphysis pubis with diastasis of pubic symphysis, hypoplastic iliac bones, bilateral short femoral neck causing coxavera deformity

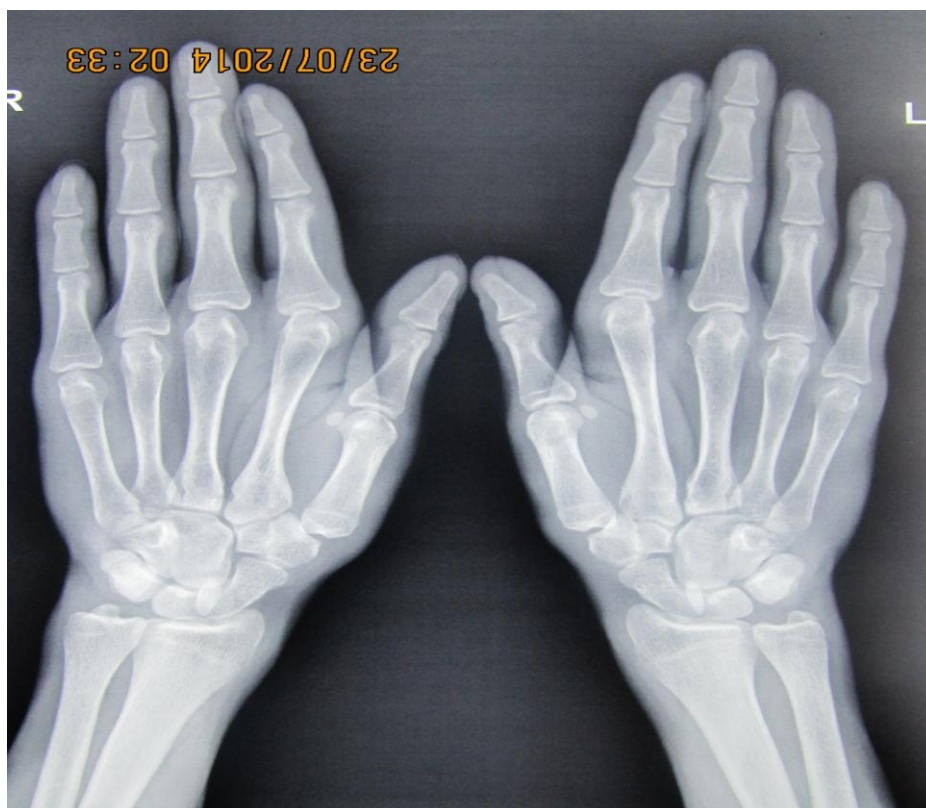

Fig. 11: Radiograph of both hands showing a bilaterally elongated second metacarpal bone, short hypoplastic distal phalanges of hand bilaterally and pointed terminal tufts

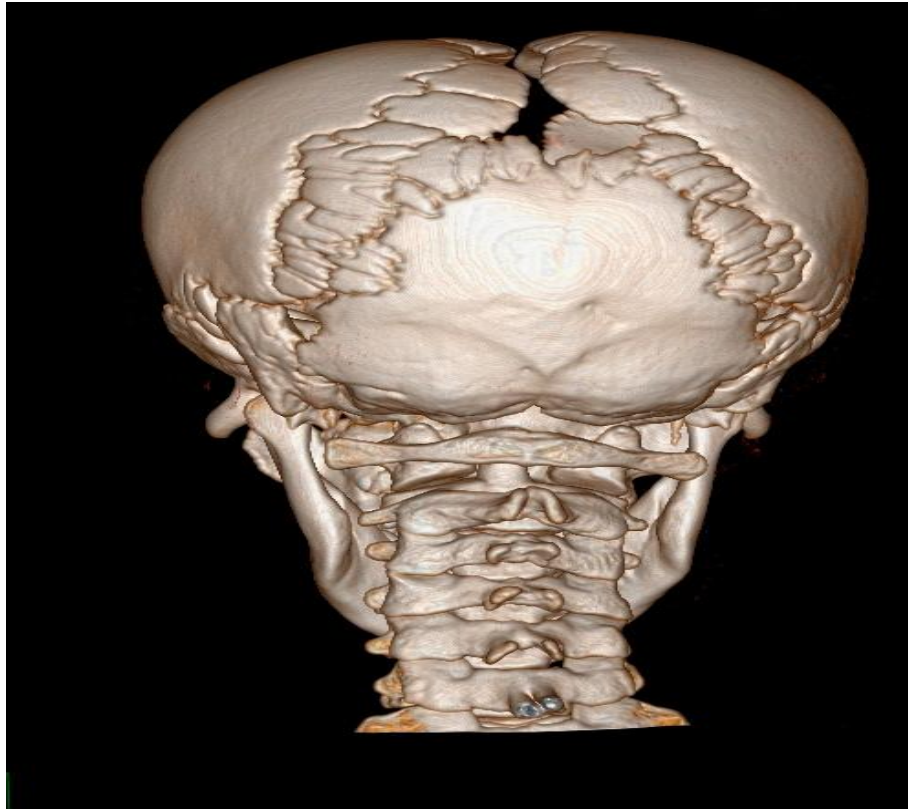

Fig.12: 3D CT showing multiple abnormal intra sutural bones typically around lambdoid suture suggestive of wormian bones and opened up and widened posterior fontanelle

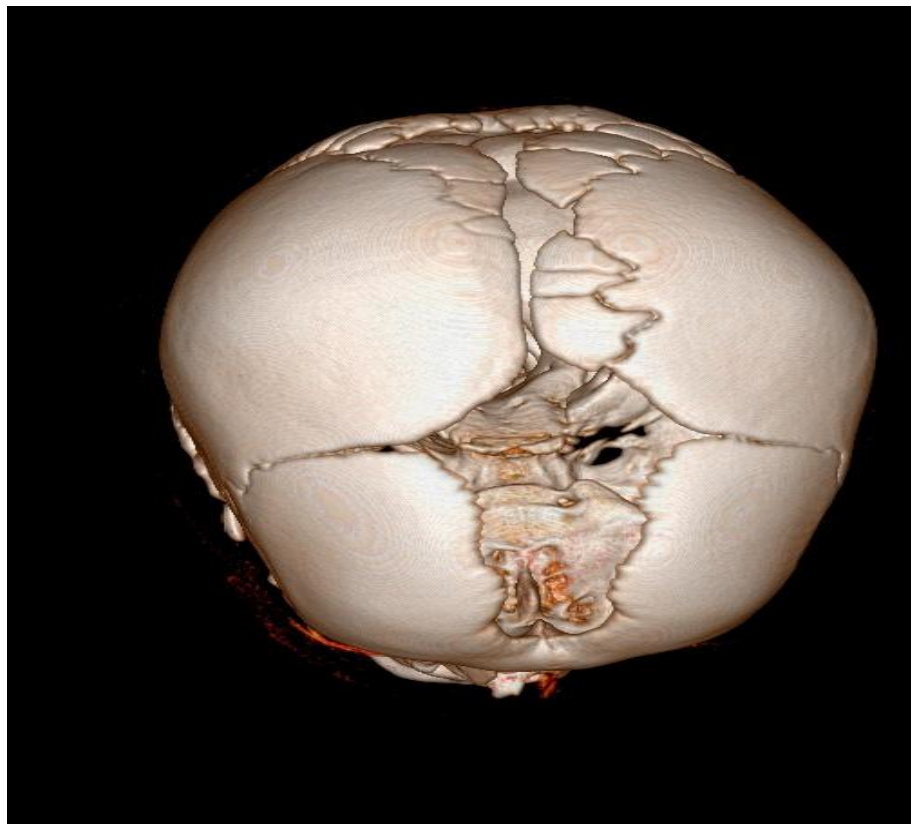


Fig.13: 3D CT showing the widened saggital suture

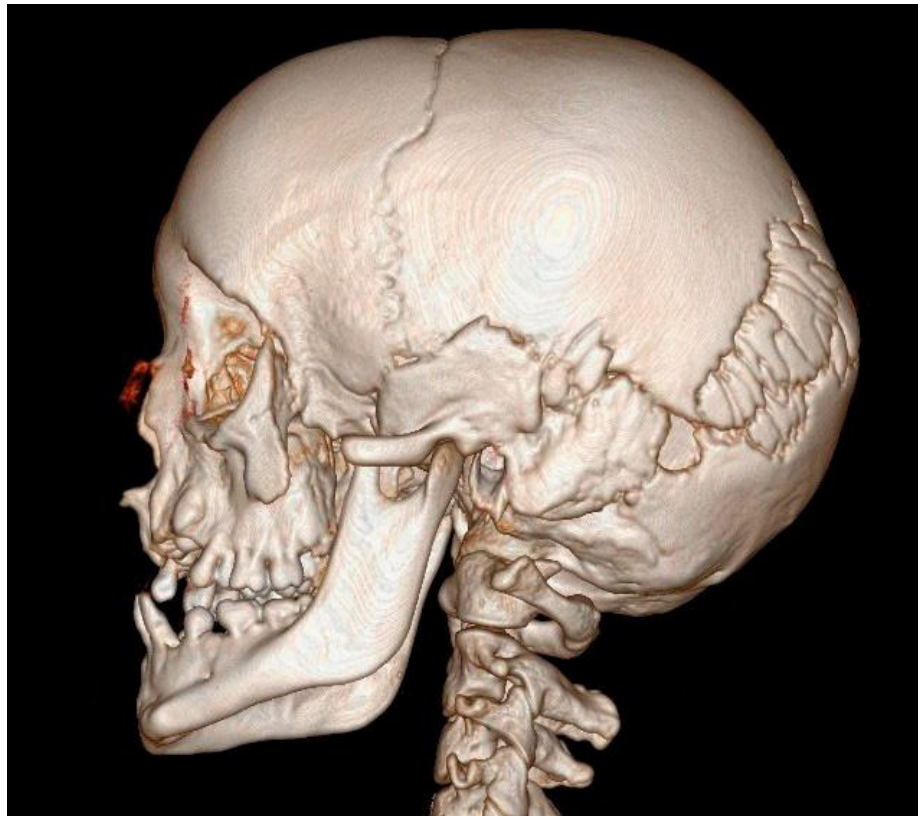


Fig.14:3D CT showing fused coronal suture

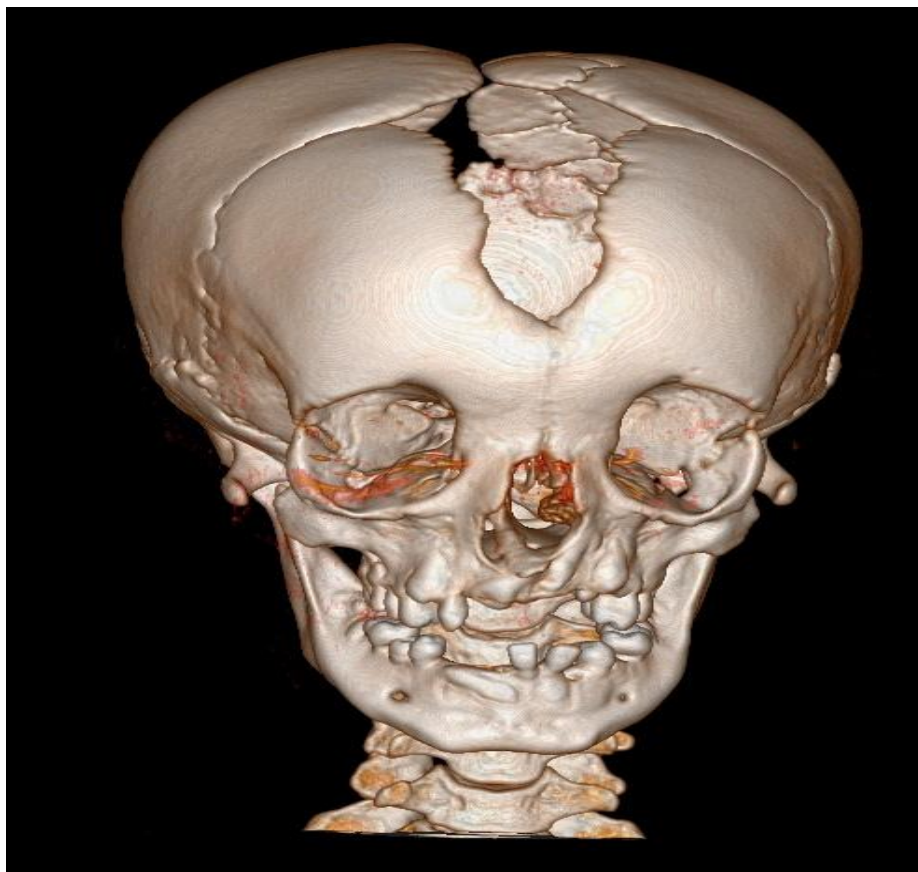


Fig.15: Anterior fontanelle seen opened up and widened

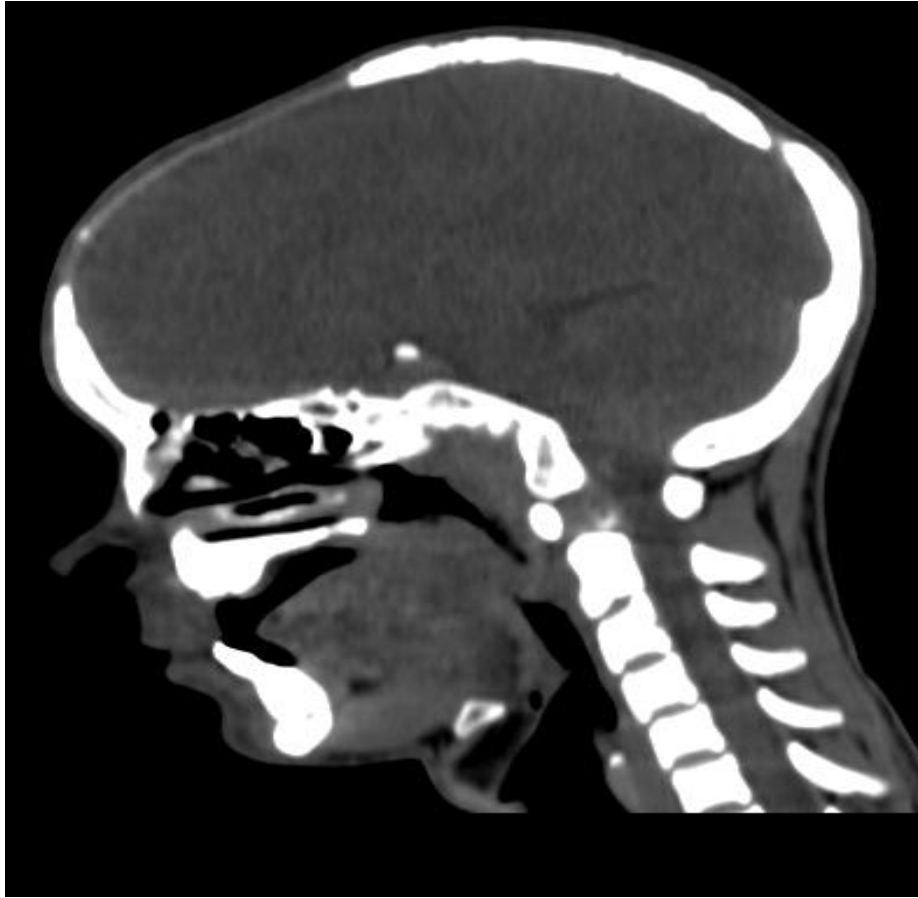

Fig.16: The sagittal CT There was persistent metopic suture with agenesis of frontal sinuses. The nasal bridge is flattened and nasal septum is deviated towards right side with convexity to right with spur formation. There was decreased pneumatization of bilateral mastoid air cells

DISCUSSION

Cleidocranial dysplasia is an autosomal dominant polymorphic skeletal disorder primarily affecting bones formed by intramembranous ossification with variable expressivities. Cleidocranial dysplasia results from mutation in the transcription factor *Runx2/Cbfa1* located on chromosome 6p21¹⁴. It is characterized by retarded cranial ossification, patent sutures and fontanelles, supernumerary teeth, short stature and a number of other skeletal abnormalities¹⁵. Cleidocranial dysplasia is first described by Marie and Sinton in 1898. It is also known as Marie-Sainton disease, mutational dysostosis, and cleidocranial dysostosis¹⁶. The first case of clavicular defects was reported by Martin in 1765. Another case with both clavicles and the skull affected was reported in 1871 by Scheuthauer. In 1897 Marie and Sinton coined the descriptive term cleidocranial dysostosis. It is a rare disorder with a prevalence of 0.5 per 100000 live births¹⁷. Due to generalized involvement of bone the term dysostosis is replaced by dysplasia¹⁸. Cleidocranial dysplasia primarily involves the bones derived from endochondral and intramembranous ossification like cranium and clavicles¹⁹. The oral manifestations of cleidocranial dysplasia are delayed exfoliation of

primary teeth, delayed eruption of permanent, multiple impactions of the permanent teeth, multiple impacted supernumerary teeth, class III skeletal malocclusion and bilateral posterior crossbite^{20,21}. Dental anomalies are very characteristic of cleidocranial dysplasia and found in almost all cases frequently. The multiple supernumerary teeth (up to 30 supernumerary teeth reported in some cases) are one of the most striking features of cleidocranial dysplasia. Early diagnosis and removal of supernumerary teeth is highly recommended to avoid impedance in normal eruption of permanent teeth²¹. There is delayed root development in permanent dentition and a lessened but not entirely absent eruptive potential²². The failure in tooth eruption may be due to the absence of cellular cementum and excessive amount of acellular cementum of the roots of the affected teeth²³. The skull base is dysplastic with stunted growth characterized by increased skull width leading to brachycephaly and hypertelorism which are usually associated with frontal and biparietal bone bossing²¹. Brachycephaly and hypertelorism occur due to delayed closure of anterior fontanel and metopic sutures and reduced growth of dysplastic skull base²⁴. In 10% of cases clavicles are completely absent however in other cases can clavicles shows variable degrees of

underdevelopment²⁵. A diagnosis of cleidocranial dysplasia is usually based on the clinical and radiological examinations. The panoramic radiograph usually shows multiple unerupted teeth in both the jaws. Skull radiograph (lateral view) demonstrates open skull sutures, delayed closure of fontanels and multiple wormian bones. The chest radiograph (PA View) usually shows the clavicular hypoplasia and bell shaped rib-cage along with poorly formed paranasal sinuses and zygomatic complex²⁶. The differential diagnosis of cleidocranial dysplasia includes Apert syndrome, Dubowitz syndrome, Russell-silver syndrome, Down's syndrome and Crouzon syndrome²⁷. The complications associated with cleidocranial dysplasia is pesplanus, genu valgum, shoulder and hip dislocation, recurrent sinusitis, upper airway complications, recurrent ear infection, hearing loss, dental caries, osteomyelitis of the mandible or maxilla, respiratory distress in early infancy²⁸. Treatment of cleidocranial dysplasia involves a multidisciplinary approach which is focused on correction of skeletal deficiencies, dentofacial deformity and correction of malocclusion and extraction of supernumerary teeth.

REFERENCES

1. Tanaka JL, Ono E, Filho EM, Castilho JC, Moraes LC, Moraes ME: Cleidocranial dysplasia: importance of radiographic images in diagnosis of the condition. *J Oral Sci* 2006, 48(3):161-166.
2. Brueton LA, Reeve A, Ellis R, Husband P, Thomson EM, Kingston HM: Apparent cleidocranial dysplasia associated with abnormalities of 8q22 in three individuals. *Am J Med Genet* 1992, 43(3):612-618.
3. Dard M: Histology of alveolar bone and primary tooth roots in a case of cleidocranial dysplasia. *Bull Group IntRechSciStomatolOdontol* 1993, 36(3-4):101-107.
4. Chen S, Santos L, Wu Y, Vuous R, Gay I, Schulze J, Chuang HH, MacDougall M: Altered gene expression in human cleidocranial dysplasia dental pulp cells. *Arch Oral Biol* 2005, 50:227-236.
5. Marie P, Sainton P: Sur la dysostose cleidocranienne hereditaire. *Rev Neurol* 1898, 6:835-838.
6. Kalliala E, Taskinen PJ: Cleidocranial dysostosis: report of six typical cases and one atypical case. *Oral Surg Oral Med Oral Pathol* 1962, 14:808.
7. T. R. Yochum and L. J. Rowe, *Essentials of Skeletal Radiology*, Williams and Wilkins, Baltimore, Md, USA, 2nd edition, 1996.
8. B. S. Gonzalez Lopez, C. Ortiz Solalinde, T. Kubodera Ito, E. Lara Carrillo, and E. Ortiz Solalinde, "Cleidocranial dysplasia: report of a family," *Journal of Oral Science*, vol. 46, no. 4, pp.259-266, 2004.
9. V. Gombra and S. Jayachandran, "Cleidocranial dysplasia: report of four cases and review," *Journal of Indian Academy of Oral Medicine and Radiology*, vol. 20, pp. 23-27, 200.
10. McNamara CM, O'Riordan BC, Blake M, Sandy JR. Cleidocranial dysplasia: radiological appearances on dental panoramic radiography. *Dentomaxillofac Radiol* 1999; 28:89-97.
11. Garg RK, Agrawal P. Clinical spectrum of cleidocranial dysplasia: a case report. *Cases Journal* 2008;1:377.
12. Dard M: Histology of alveolar bone and primary tooth roots in a case of cleidocranial dysplasia. *Bull Group IntRechSciStomatolOdontol* 1993, 36(3-4):101-107.
13. Quinn PD, Lewis J, Levin LM: Surgical management of a patient with cleidocranial dysplasia: a case report. *Special Care Dent* 1992, 12(3):131-133.
14. Yoshida T, Kanegane H, Osato M, Yanagida M, Miyawaki T, Ito Y, et al. Functional analysis of RUNX2 mutations in Japanese patients with cleidocranial dysplasia demonstrates novel genotype-phenotype correlations. *Am J Hum Genet*. 2002;71(4):724-38.
15. Jensen BL. Cleidocranial dysplasia: Craniofacial morphology in adult patients. *J Craniofacial Genet Dev Biol*. 1994;14:163-76.
16. Kalliala E TP. Cleidocranial dysostosis: report of six typical cases and one atypical case. *Oral Surg Oral Med Oral Pathol*. 1952;4:808-22.
17. Mundlos S. Cleidocranial dysplasia: clinical and molecular genetics. *J Med Genet*. 1999;36(3):177-82.
18. Rimoin DL. International nomenclature of constitutional diseases of bone. *J Pediatr*. 1978;93:614-8.
19. Zhou G, Chen Y, Zhou L et al. CBFA1 mutation analysis and functional correlation with phenotypic variability in cleidocranial dysplasia. *Hum Mol Genet*. 1999;8(2311-6).
20. Golan I, Baumert U, Wagener H, Dauwse J, Preising M, Lorenz B, et al. Atypical expression of cleidocranial dysplasia: clinical and molecular-genetic analysis. *Orthodontics & craniofacial research*. 2002. p. 243-9.
21. Golan I, Baumert U, Hrala BP, Müßig D. Early craniofacial signs of cleidocranial dysplasia. *Int J Paediatr Dent*. 2004;14(1):49-53.
22. Jensen BL, Kreiborg S. Development of the dentition in cleidocranial dysplasia. *J Oral Pathol Med*. 1990;19(2):89-93.
23. Counts AL, Rohrer MD, Prasad H, Bolen P. An Assessment of Root Cementum in Cleidocranial Dysplasia. *Angle Orthod*. 2001;71(4):293-8.
24. Golan I, Baumert U, Hrala BP, Müßig D. Dentomaxillofacial variability of cleidocranial dysplasia: Clinicoradiological presentation and systematic review. *Dentomaxillofac Radiology*. 2003. p. 347-54.
25. Tanaka JLO, Ono E, Filho EM, Castilho JCM, Moraes LC, Moraes MEL. Cleidocranial dysplasia: importance of radiographic images in diagnosis of the condition. *Journal of oral science*. 2006. p. 161-6.
26. Kulkarni VV, Prachi Shrigopal Baldawa, Snehal Ravindra Nahar, Sneha Pramod Desai JC. Cleidocranial Dysplasia: A Clinico-Radiological Illustration of a Rare Case. *Int J Oral Maxillofac Pathol*. 2014;5(2):18-20.
27. KL J smiths. *Recognizable Patterns of Human Malformation*. Philadelphia: Elsevier Saunders; 2006. 872-873 p.
28. Cooper SC, Flaitz CM, Johnston DA et al. A natural history of cleidocranial dysplasia. *Am J Med Genet* 2001. 2001;104:1-6.