

Unilateral Condylar Hyperplasia Causing Facial Asymmetry – A Case Report

Lekshmy.J^{1*}, Padmashree.S², Rachna Kaul³, Rema Jayalekshmy⁴, Shilpa Sastry⁵

¹Post Graduate Student, ²Professor & HOD, ³Reader, ⁴Professor, ⁵Senior Lecturer,
Dept. of Oral Medicine and Radiology, Vydehi Institute of Dental Sciences & Research Centre,
82, Nallurahalli, Near BMTC 18th Depot, Whitefield, Bangalore - 560066

***Corresponding Author**

E-mail: dr.lekshmyj@gmail.com

Abstract

Mandibular condylar hyperplasia is a relatively rare condition with uncertain etiology affecting the condylar head, neck and many a times body and ramus of mandible. The condition causes facial asymmetry, deviation of the jaw, occlusal derangements and articular dysfunction. Radiographic examination plays a critical role in establishing a correct diagnosis. Bone scintigraphy scan has been found to be effective in direct assessment of condylar activity which aids in proper treatment planning. Here, we report a case of unilateral condylar hyperplasia in a 19year old female patient which was diagnosed and corrected with the help of appropriate radiographic examination.

Key words: Bone scintigraphy, Condylar hyperplasia, Facial asymmetry.

Access this article online	
Quick Response Code:	Website: www.innovativepublication.com
	DOI: 10.5958/2395-6194.2016.00005.9

of condylar hyperplasia is primarily surgical, with or without orthodontics and it depends on the degree of severity and status of condylar growth [6]. Here we are reporting a case of unilateral condylar hyperplasia in a 19year old female patient which was of esthetic concern to the patient, clinical features and radiographic features in detail including radionuclide scan along with diagnosis and management.

Introduction

Mandibular condylar hyperplasia (CH) is a rare deformity of the mandible resulting in overdevelopment of mandible creating functional and esthetic problems. It was first described by Robert Adams in 1836^[1]. Etiology of the condition is uncertain and not well understood. Suggested theories include trauma, infection, hormonal disturbances, hypervascularity, arthrosis, increase in functional loading of temporomandibular joint and a possible genetic role^[1,2,3]. Obwegeser and Makek classified asymmetry associated with Condylar Hyperplasia into 3 categories: i) Hemimandibular hyperplasia causing asymmetry in vertical plane. ii) Hemimandibular elongation causing asymmetry in transverse plane iii) Hybrid form-combination of both [4]. Diagnosis of this condition is often a challenge to oral maxillofacial specialists. Clinical examination along with maxillofacial imaging modalities can be made use of to aid in accurate diagnosis. Panoramic view aid in comparing the difference in shape and size of the condyle with respect to left and right side. Assessment of condylar activity is an important step in managing such cases. Bone scintigraphy scan with technetium 99 methylene bisphosphonate forms an important tool. Increased radionuclide uptake by hyperplastic condyle is an indication of continuing abnormal growth [5]. Treatment

Case report

A 19 year old female patient came to dental outpatient department with chief complaint of elongation of face on left side lower one third of face since 5-6 months (Fig. 1). Patient reported to outpatient department of Vydehi Institute of dental sciences and research centre. Also complaints of associated pain on left side of face in front of ear. Patient was apparently normal 5-6 months back when she started noticing elongation of face on left side. After 3-4months, she started experiencing pain on left side of ear during eating. Pain was of dull type, mild intensity which increased on chewing food and decreased by itself after 15-20mins. Patient visited a local dentist who prescribed painkiller and referred the patient to a surgeon. Patient visited maxillofacial surgeon in her native who advised for a surgery, but patient refused the treatment. Patient started chewing food on right side to avoid pain on left side, but pain did not subside. Patient was later referred to our institute by her relatives.

On TMJ examination, mild tenderness on palpation irt left TMJ with prominence of condyle on intra auricular palpation. Mild deviation present to right side on opening the mouth. On extraoral examination, inspection, asymmetry noted irt left side. Fullness of face seen on right lower one third of face with flattening of left side. On extraoral examination

palpation, prominence of bone felt on left inferior border of mandible and angle of mandible. On intraoral examination, inspection, missing tooth noted irt 36 with mesial migration of 37. No derangement of occlusion detected. No gross increase in size of teeth or soft tissues noted irt left /right side. Based on history and clinical findings, a provisional diagnosis of Condylar hyperplasia in relation to left side was given. Differential diagnosis considered were Osteochondroma and Chondroblastoma as these are the most common benign tumours of temporomandibular joint region usually presented with preauricular swelling and limitation of motion of the joint.

Digital panoramic radiograph reveals increase in size of condylar head and neck irt left side when compared to right side (Fig. 2). Shallow sigmoid notch, increased ramal length, increase in superio inferio height of body of mandible appreciated on left side. Inferior alveolar canal lowered in position when

compared to right side. Missing tooth noted irt 36 with mesial migration of 37. (Fig. 3) Postero Anterior Cephalometric radiograph reveals a prominent left side irt mandible with increase in size of condylar head and neck. Three phase bone scintigraphy scan was done after I.V. injection of 70 MBq of Technitium 99m Methylene biphosphonate. Dynamic images were acquired immediately followed by static views after 3 hours. There is focus of increased tracer uptake involving the left condyle (Fig. 4). Bone scan appearance is suggestive of mandibular left condylar hyperplasia. Based on clinical and radiologic investigations, a final diagnosis of Condylar hyperplasia in relation to left side was given as final diagnosis. Treatment done was left high condylectomy through pre-auricular approach & recon touring of the left lower border of the mandible through intra-oral vestibular approach under GA. Patient is currently under follow up.

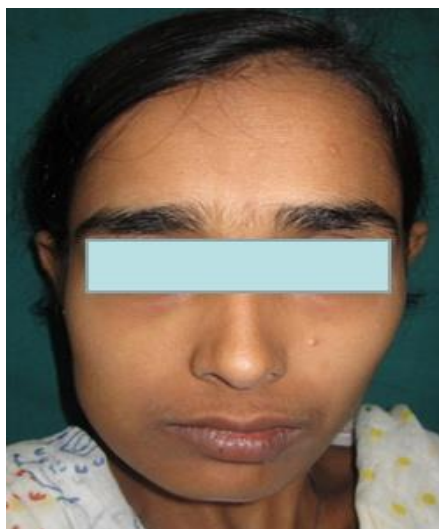

Fig. 1: Extraoral photograph of the patient

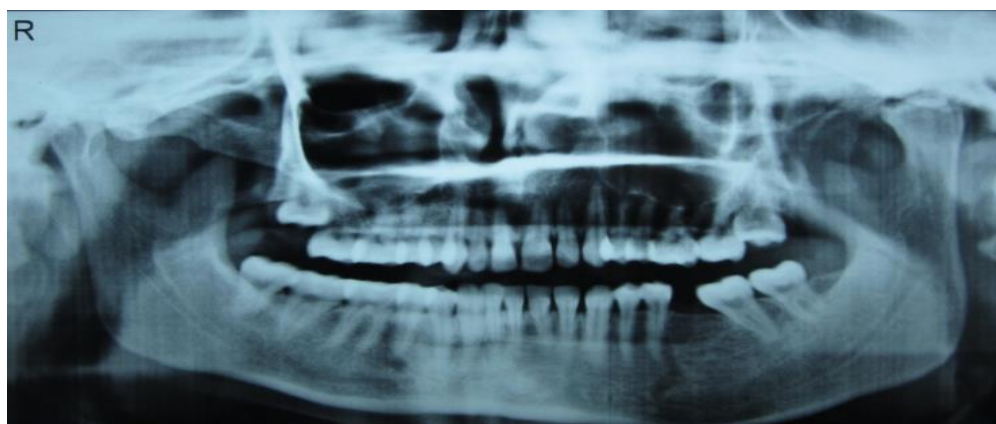


Fig. 2: Digital panoramic radiograph increase in size of condylar head and neck irt left side when compared to right side. Shallow sigmoid notch, increased ramal length, increase in superio inferio height of body of mandible appreciated on left side. Inferior alveolar canal lowered in position when compared to right side. Missing tooth noted irt 36 with mesial migration of 37

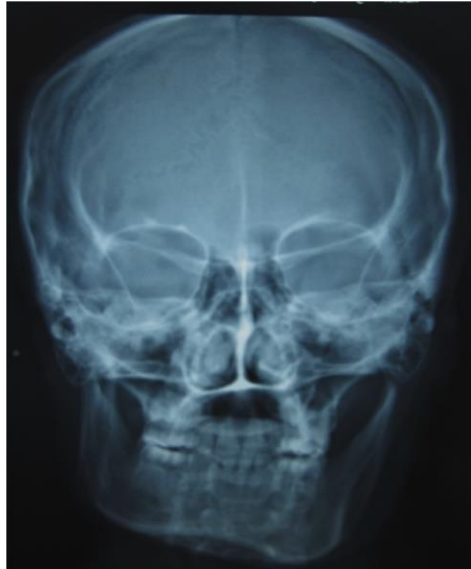

Fig. 3: Postero Anterior Cephalometric radiograph reveals a prominent left side of mandible with increase in size of condylar head and neck with slanting of the occlusal plane

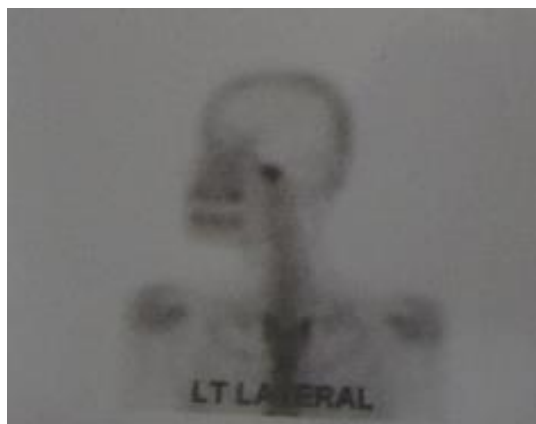

Fig. 4: Bone scintigraphy scan revealing focus of increased tracer uptake involving the left condyle.

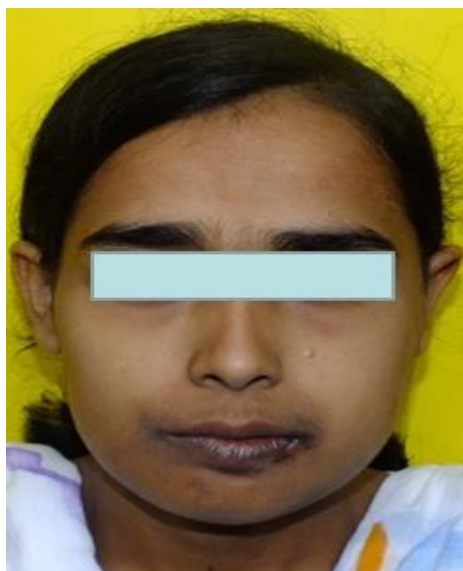

Fig.5: Extraoral post-operative photograph of the patient after 15days

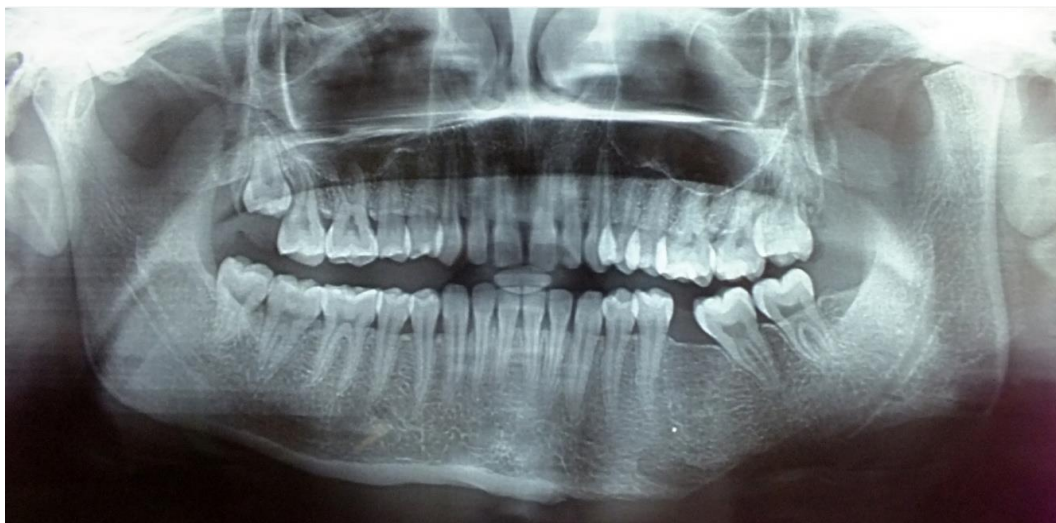

Fig. 6: Post-operative panoramic radiograph after 15days of surgery

Discussion

Mandibular condylar hyperplasia is an uncommon condition first described by Robert Adams in 1836 as an overgrowth of mandibular condyle, unilaterally or bilaterally, leading to facial asymmetry, mandibular deviation, malocclusion and sometimes articular dysfunction [7]. The condition is usually self limiting, but if it remains active, asymmetry and occlusal disturbances will be progressive. Rowe defined Mandibular condylar hyperplasia as an entity that produces an asymmetry of the mandible resulting from an enlargement of one side that is not due to neoplasia or dysplasia [8]. The etiology of condylar hyperplasia is not clearly understood. Plethora of presumed causes include trauma followed by excessive proliferation in repair, infection, hormonal influences, arthrosis, hypervascularity and a possible genetic role [1]. Obwegeser and Makek suggested that growth factors controlling generalised hypertrophy and elongation might be responsible for the condition [9]. Functional loading has also been taken into consideration as a possible cause but lacking substantial evidence. In our patient, it could be attributed to the hormonal variations as the patient has just crossed her puberty.

Age of onset of the condition has not been concluded yet, literature noted a female predilection, some studies found a male predilection [10]. It has been reported that there is an increase in the number of estrogen receptors in temporomandibular joint and this could be the cause for increased growth activity in females [11]. Condylar hyperplasia was also proposed to show laterality based on gender, with women affected frequently on right side and men on left side [12].

Clinical features in mandibular condylar hyperplasia include enlarged mandibular condyle, elongated condylar neck, downward growth of the body and ramus of mandible on affected side causing fullness of face on that side and flattening of face on the contralateral side [13]. All the above mentioned features

were present in our case which gave us a clear indication regarding provisional diagnosis.

Obwegeser and Makek in 1986 classified asymmetry associated with condylar hyperplasia in to 3 categories: i) Hemimandibular hyperplasia causing asymmetry in vertical plane ii) Hemimandibular elongation causing asymmetry in transverse plane and iii) hybrid variant which is a combination of the above two [14]. Type 1 is characterised by chin deviation towards the contralateral side and mandibular midline deviated to unaffected side. Radiologically, condyle appears enlarged, head is usually irregular and deformed, neck thickened and elongated with coarse trabeculae filling the condyle. Type 2 is characterised by an ipsilateral openbite or a compensatory vertical overdevelopment of the maxilla on the involved side with canting of occlusal plane, mandibular midline is straight and chin is less deviated. Radiographically, condyle can be of normal size and shape, neck can be normal or elongated with an elongated ascending ramus. Typical clinical features pertaining to any type were not present in our case, but can still be put under type 2 considering that mandibular midline is straight and chin is less deviated in addition to radiographic features.

Differential diagnosis that can be considered for the condition include: Hemifacial hyperplasia, condition with associated enlargement of soft tissues and teeth in relation to the associated side; In synovial chondromatosis, preauricular swelling with pain and limitation of joint function will be usually present. Chondroma and osteochondroma may produce similar symptoms and signs like condylar hyperplasia, but they are often localised, grow more rapidly and can cause greater asymmetry. However diagnosis of condylar hyperplasia can be made by a combination of clinical and radiologic findings.

Radiographic evaluation includes panoramic radiograph, posterior anterior radiographs, TMJ

radiographs, Bone scintigraphy scans and computed tomography images with 3D reconstruction. Panoramic and posteroanterior radiographs help in surveying the shape of mandibular condyles on both sides and also midlines of face and dentition can be recorded and evaluated^[6]. TMJ radiographs help to know abnormalities in size and shape of condylar head ^[1]. Computerised tomography helps to establish pathology, compare condylar morphology, and provide a three dimensional rendition of the bony structures. In order to establish a proper treatment plan, it is essential to distinguish active and inactive growth forms. Bone single photon emission computed tomography is an essential tool in visualising hyperactivity of condyle specially in unilateral cases ^[15]. Radioactive isotope employed is Technitium 99 methylene bisphosphonate, and increased uptake of the isotope indicates continuing growth activity. A difference in uptake of isotope of 10% or more between the two condyles is regarded as indicative of condylar hyperplasia ^[11]. It is not regarded as a main indicator of growth activity due to the false positive results in cases with TMJ inflammation ^[16].

Treatment plan for the condition is primarily surgical followed by orthodontic therapy. The common ground in treatment planning is in determining the condylar growth activity. Treatment plan should also consider the amount of asymmetry and malocclusion. Surgical treatment ranges from simple osteotomies to complex surgical procedures. Unilateral condylar hyperplasia can be corrected by high condylectomy (removal of 4-5mm of condyle) which is expected to arrest the excessive, disproportionate growth of the mandible on the affected side eliminating the need for additional surgical interventions in most cases ^[4]. Controversy still exists regarding the time of surgery, with some authors preferring surgery as soon as possible while others wait for cessation of excess activity to perform any intervention. As the present case had mild asymmetry of jaws without any occlusal derangements, high condylectomy of left side through preauricular approach along with recontouring of the left lower border of mandible through intraoral vestibular approach under general anesthesia was performed.

Conclusion

Mandibular condylar hyperplasia is a rare condition resulting in varying levels of facial asymmetry and malocclusion. Clinical presentation of the condition along with adequate history and radiographic investigations help reveal the true nature of the condition. More effective follow up studies are required to establish successful treatment methods.

Additional studies are required to probe into the etiology of the condition for earlier diagnosis.

Conflict of Interest: None

Source of Support: Nil

References

1. Laura Villanueva, Florencio Monje, Raul Gonzalez-garcia. Hyperplasia of the Mandibular condyle: Clinical, histopathologic and treatment considerations in a series of 36 patients. *J Oral Maxillofac Surg* 2010.
2. Neville, Damm, Allen and Bouquot. *Textbook of Oral & Maxillofacial pathology*, 2nd edition. Philadelphia: W.B.Saunders, 2001:16
3. Egyedi P: Aetiology of Condylar hyperplasia. *Aust Dent J* 14:12,1969
4. Samuel Porfirio Xavier, Thiago de Santana Santos, Erick Ricardo Silva, Ana Celia Faria, Francisco Verissimo de Mello Filho: Two stage treatment of Facial asymmetry caused by Unilateral Condylar Hyperplasia; *Brazilian Dental Journal* (2014) 25 (3): 257-260
5. Sirin Nevzatoglu, Evin Koc, Toros Alcan, Zeki Guzel. Short and Long term evaluation of a condylar hyperplasia : A Case report ; *Turkish J Orthod* 2013; 26:103-113
6. Everton Da Rosa, Julio Evangelista, De Souza Junior, Melina Spinosa Tiussi. *Hospital de Base do Distrito Federal, Brazil.*
7. Suma G N, Manisha Lakhpal Sharma, Dayashankar Rao JK, Sumit Goel, Siddharth Srivastava. Facial Asymmetry in Young adults with condylar hyperplasia- Unusual changes in Facial bones: *Journal of Clinical and Diagnostic Research*; 2015 Jan, vol-9(1)
8. Rowe NL: Aetiology, clinica features and treatment of mandibular deformity. (*Br Dent J* 108:41,1960).
9. Obwegeser H, Makek M: Hemimandibular hyperplasia-hemimandibular elongation. *J Maxillofac Surg*,1986 ,14:83
10. Nitzan D, Katsnelson A, Bermanis I. The clinical characteristics of condylar hyperplasia: Experience with 61 patients. *J Oral Maxillofac Surg* 2008;66:312-8
11. Ahmed Alyamani, Sondos Abuzinada. Management of patients with condylar hyperplasia: A diverse experience with 18 patients; *Annals of Maxillofacial surgery*:2012 (2)
12. Luis Eduardo Almeida, Joseph Zacharias, Sean Pierce. Condylar hyperplasia: An updated review of literature; *Korean J Orthod* 2015; 45(6):333-340
13. S Aravind Warriar, S Sathashivasubramanian. Unilateral Condylar Hyperplasia- A Rare Case Report; *Sri Ramachandra Journal of Medicine* 2010(3):20-22.
14. Aneel Kumar Vaswani, Bhesham Kumar Shahani, Waseem Mehmood Nizamani, Geeta Aneel, Indra Bhesham. Unilateral Mandibular condylar hyperplasia- A Rare entity. *Pakistan Journal of Medicine and Dentistry*; 2015:4(2)
15. Villanueva-Alcojol, L.; Monje, F.; González-García, R. Hyperplasia of the Mandibular Condyle: Clinical, Histopathologic, and Treatment Considerations in a Series of 36 Patients *J Oral Maxillofac Surg* 69:447-455, 2011
16. Pripatnanont P, Vittayakitpong P, Markmanee U, Thongmak S, Yipintsoi T. The use of SPECT to evaluate growth cessation of the mandible in unilateral condylar hyperplasia. *Int J Oral Maxillofac Surg* 2005;34:364-8