

Content available at: <https://www.ipinnovative.com/open-access-journals>

Journal of Oral Medicine, Oral Surgery, Oral Pathology and Oral Radiology

Journal homepage: [www.joooo.org](http://www.joooo.org)

## Original Research Article

## Evaluation of edema formation and salivary EGF related to 810 nm diode laser and conventional surgery after frenectomy

Burak AK<sup>1,\*</sup><sup>1</sup>Mersin University Faculty of Dentistry Periodontology, Mersin, Turkey

## ARTICLE INFO

## Article history:

Received 21-12-2022

Accepted 30-01-2023

Available online 10-03-2023

## Keywords:

Laser

Conventional

Frenectomy

Edema

Face scan

Cephalometry

EGF

810 nm diode

## ABSTRACT

The surgical procedure that lessens edema formation after frenectomy surgery is important.

Re-epithelialization with lasers occurs differently from conventional surgery, and this can affect the salivary EGF level. The aim of this study was to determine edema caused by frenectomy surgery and compare the amount of EGF in saliva. Conventional and 810 nm diode laser surgery performed with thirty-four patients. Laser parameters were 400  $\mu\text{m}$  fiber with 2.5 W output energy, in continuous mode. 3D face scan data was obtained with a Planmeca Proface Mid device and analyzed with the 3D metrology method using the CloudCompare V2 software. Cephalometric analysis was performed using 2D profile photographs with Geogebra software. Edema measurements were repeated on day 1 (T1), day 3 (T2) and day 14 (T3). All saliva samples were collected at T1 and T3 and salivary EGF concentration was determined using the ELISA method. In conventional surgery, a significant difference was found between  $\Delta\text{T2-T1}$  and  $\Delta\text{T3-T1}$  in 3D metrology measurements ( $p=0.0046$ ). In 2D cephalometric measurements there was significant differences in Angle A T2-T1 vs. Angle A T3-T1 ( $p=0.0014$ ) and vs. Angle B T2-T1 ( $p=0.0017$ ) and vs. Angle B T3-T1 ( $p=0.0087$ ) in conventional surgery. There were no significant changes in edema measurements of laser surgery. The laser frenectomy does not produce edema significantly ( $p=0.1232$ ). There were no significant changes between groups in salivary EGF measurements ( $p>0.999$ ). The 810 nm laser surgery produced less edema than conventional surgery. The 810 nm diode laser does not significantly affect salivary EGF.

This is an Open Access (OA) journal, and articles are distributed under the terms of the [Creative Commons Attribution-NonCommercial-ShareAlike 4.0 License](https://creativecommons.org/licenses/by-nc-sa/4.0/), which allows others to remix, tweak, and build upon the work non-commercially, as long as appropriate credit is given and the new creations are licensed under the identical terms.

For reprints contact: [reprint@ipinnovative.com](mailto:reprint@ipinnovative.com)

## 1. Introduction

Frenum surgery is indicated when this anatomical formation has an orthodontic, prosthetic, phonetic, or periodontal effect.<sup>1,2</sup> For this purpose, there are surgical techniques, using a scalpel, electrocautery, and various laser devices.<sup>3,4</sup>

Diode laser has advantages in periodontal soft-tissue surgery, as it involves no sutures, less pain and less post-operative infection.<sup>3,5</sup> After laser surgery, visual analog scale (VAS) scores were found to be lower compared to after scalpel surgery.<sup>6,7</sup> However, recovery is slower in surgical procedures performed with a laser compared to

scalpel.<sup>8,9</sup> Edema formation may occur because diode lasers can penetrate the adjacent tissue and cause lateral heat damage and this damage can cause delayed healing of the surgical site.<sup>9</sup>

In conventional surgery, VAS scores reported higher, recovery is provided with primary healing<sup>5</sup> and healing occurs more quickly than in laser surgery due to the absence of ablated tissue.<sup>9</sup> Edema formation is more common in conventional surgery due to the incisions and sutures.<sup>7,10</sup> Flap design and suture positions also affects postoperative complications such as pain, trismus and swelling.<sup>11</sup>

Prevention of edema formation plays an important role in returning patients to their usual daily comfort levels, as

\* Corresponding author.

E-mail address: [drburakak@mersin.edu.tr](mailto:drburakak@mersin.edu.tr) (Burak AK).

well as in wound healing, and postoperative recovery after the surgical procedure.<sup>12</sup> Edema formation also affects local tissue oxygen and nutrient supply.<sup>13</sup> Anti-inflammatory drugs, cold application, or different surgical devices and adjunctive effects to reduce edema were compared.<sup>1,14,15</sup>

The elastic tape measurement method is the most common method to measure the amount of edema.<sup>14,16</sup> The tape method has disadvantages, such as measuring by direct contact with the patient, reducing comfort, and the possibility of making the measurement incorrect.<sup>17,18</sup> The 3D face-scanning method has been reported to be a fast and reproducible measurement method,<sup>17</sup> and has been evaluated as an alternative to the tape measurement method.<sup>19</sup> Disadvantage of the 3D scanning method is time-consuming, expensive and requires expertise.<sup>17,20,21</sup> An easy-to-apply and reproducible measurement method is needed.

The amount of edema can also be measured with photographic recordings.<sup>20</sup> However, it is difficult to standardize photographic records.<sup>20,22</sup> Cephalometry is a proven method in orthodontics, where angles are used between certain points.<sup>22</sup> The second aim of this study is to measure the amount of edema using a cephalometric analysis of a profile photo.

Wound healing is affected by various growth factors and hormones.<sup>23</sup> EGF functions in wound healing by its hormone-like activity. EGF promotes chemotaxis, inhibits the matrix synthesis, and helps to proliferate osteoblastic cells.<sup>24</sup> Increased EGF has been reported in saliva after periodontal surgery.<sup>25</sup> Increased levels of EGF have been reported in periodontal wound fluid after periodontal regenerative treatment.<sup>23</sup> EGF increases in open wounds until epithelialization is completed.<sup>23,26</sup> The absence of open wound in laser surgery due to the ablated tissue may cause epithelial cells to secrete less EGF. On the other hand it is reported that lasers stimulate fibroblasts to produce more EGF.<sup>27</sup> However, the effect of laser-stimulated cells is unclear. For this reason, this study also aimed to comparatively examine the salivary EGF level.

To the best of our knowledge, there is no study comparing edema formation with the use of 810 nm diode laser frenectomy versus conventional frenectomy. No studies examining salivary EGF were also observed. The aim of this study is to compare the amount of facial edema by two different quantitative methods and salivary EGF level after 810 nm diode laser and conventional frenectomy surgery.

## 2. Materials and Methods

Ethics approval for this study was obtained from the Mersin University Clinical Research Ethics Committee (approval no=78017789/050, 01.04/804076-2018/308). Patients who applied to Mersin University Faculty of Dentistry Periodontology Department and were diagnosed with

high frenum were included in the study. Patients between the ages of 18-65, without any systemic disease, without any previous frenum surgery, without tooth deficiency in the frenum region, without the diagnosis of periodontitis and gingivitis, and who did not undergo restorative or prosthetic treatment or periodontal surgery that could affect the anatomy of the frenulum region were included in the study. Patients who received drug therapy, radiotherapy or prosthetic restoration therapy were not included in the study. A flow diagram of the study is illustrated in Figure 1.

The patients were randomly divided into conventional and diode laser surgery groups. At T1 (before surgery), T2 (3<sup>rd</sup> day after surgery), and T3 (14<sup>th</sup> day after surgery) face scans were taken with Romexis version 4.6 Proface feature of the ProMax® 3D Mid device (Planmeca, Helsinki, Finland). Profile photos were taken with a Panasonic DMC-TZ20 camera at T1, T2, and T3. Unstimulated saliva samples were taken at T1 and T3.

### 2.1. Surgery procedure

All procedures were performed by the same operator and under local infiltration anesthesia with lidocaine (2%) associated with epinephrine 1:100,000.

In conventional surgery, the frenum was grasped with a hemostat inserted deep into the vestibule and completely excised with a scalpel blade (No. 15) on the upper and lower sides of the hemostat.<sup>28,29</sup> The resection site edges were sutured using 4-0 black silk with interrupted sutures.<sup>4,30</sup>

Frenectomy surgery was performed with 810 nm wavelength diode laser with GIGA (Gigaa Gbox 15 W 810nm Surgical Diode Laser System Wuhan Gigaa Optronics Technology Co., Ltd, China) diode laser. A 400  $\mu$ m diameter fiber was used at a 2.5-Watt in continuous mode (Table 1). The frenum was held by a hemostat while the fiber tip of the laser system was applied to the upper and lower parts of the frenum adjacent to the hemostat. Ablate tissue residues were removed with the aid of a sterile sponge. They were washed with saline solution. The laser was carefully applied to the tissue, and care was taken to avoid local necrosis of the adjacent tissues. No sutures were placed after the frenectomy procedure.<sup>28,29</sup>

Both surgical sites were covered with a periodontal dressing (Coe-Pak), which was removed three days after surgery.<sup>4</sup> It was stated that patients should not use any drug other than 500 mg paracetamol, which was used when deemed necessary after the surgical procedure.

### 2.2. Metrological procedure

Edema quantification and analyses were performed using two different methods: 3D deviation map method and 2D cephalometric method.

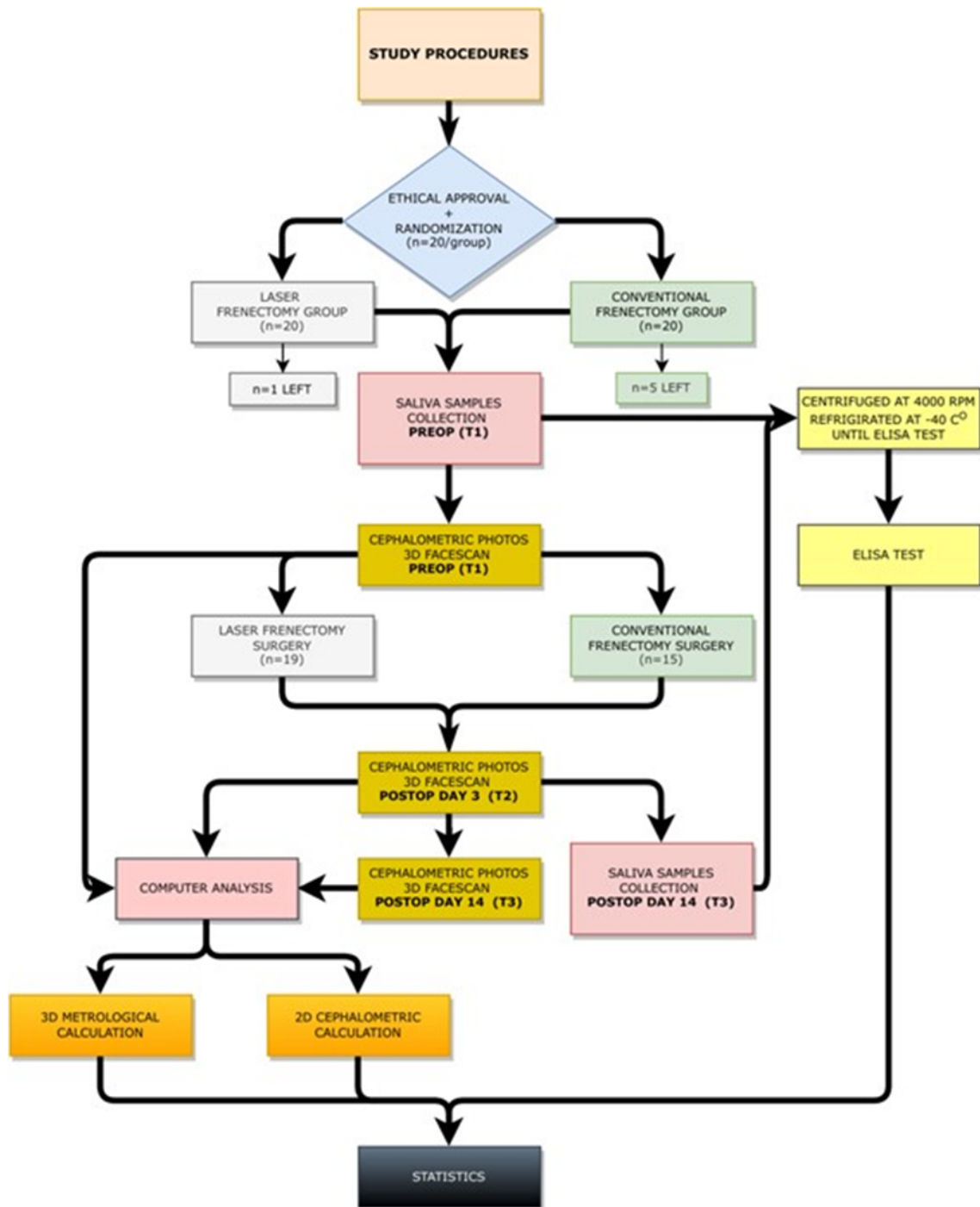


Fig. 1: Study flow diagram

### 2.2.1. 3D deviation map analysis

Face scans were obtained using the Planmeca Promax Mid 3D device and Planmeca ProMax 3D Proface software version 4.6 (Planmeca OY, Finland). Images were exported in wavefront “.obj” format. Scans were imported into CloudCompare V2 (GNU GPL (General Public License) Version: 2.6.2 (Windows 32 bits)) software. Meshes were aligned with the fine registration (ICP- Iterative Closest Points) algorithm method. Difference analyses were performed using cloud/mesh distance algorithm. Linear measurements from meshes were taken from the Sn (subnasale) and Sm (mentolabial sulcus) points.

### 2.2.2. 2D cephalometric analysis

Profile photos taken with a Panasonic DMC-TZ20 camera at T1, T2, and T3 were imported into Geogebra Classic software version 6.0.609.0 offline 2020 (Geogebra GmbH, Linz, Austria). The nasolabial angle (angle A) between the columella (Cm)–subnasale (Sn)–labial superior (Ls) points on the maxilla and the mentolabial angle (angle B) passing through the labial inferior (Li)–mentolabial sulcus (Sm)–soft tissue pogonion (Pg) points on the lower jaw were measured.

### 2.3. Saliva collection

Unstimulated saliva was collected from each patient at T1 and T3. It was reported that patients should not eat or drink anything until 1 hour before the procedure. Patients were asked to spit into saliva collection tubes for 5 minutes. Then, the samples were centrifuged at 4000 rpm and eluent of samples was stored at -40 °C until the ELISA testing. EGF levels were evaluated using the ELISA method.<sup>25</sup>

### 2.4. Statistical analysis

Data were evaluated with GraphPad Prism software version 9.3.1 (San Diego, CA, USA) and expressed as mean and standard deviation. The evaluation completed using a two-way repeated-measures analysis of variance (ANOVA). Intragroup differences were evaluated with Bonferroni's multiple comparisons test. Data with a p-value less than 0.05 were considered significant.

## 3. Results

### 3.1. Demographic data are as presented in Table 1.

The mean age was 31 in conventional surgery and 40 in laser surgery. Thirty-four patients, 10 men and 24 women, were included in the study. The mean age of the entire study was 35,1 for men and 36,3 for women. The mean age of all patients included in the study was 36,2 (Table 2).

**Table 1:** Laser parameters

Device manufacturer	GIGAA Gbox 15 watt
Wavelength	810 nm
Emission mode	Continuous
Output energy	2.5 Watt
Fiber diameter	400 $\mu$ m
Mode	Contact

### 3.2. 3D scan results

In the conventional frenectomy surgery's 3D linear measurements between A point in the  $\Delta$ T2-T1 time interval was 1.214 mm. This was 0.3627 mm in  $\Delta$ T3-T1. This change is significant in the intragroup comparison ( $p=0.0046$ ), as presented in Table 4. The difference between B point was -0.4373 mm in  $\Delta$ T2-T1 and -0.3560 mm in  $\Delta$ T3-T1. This change is statistically insignificant in the intragroup comparison ( $p>0,9999$ ).

In laser surgery, the difference between A point was 0,9958 mm in the  $\Delta$ T2-T1. This was 0.2725 mm in the  $\Delta$ T3-T1 (Table 3). This change is not significant in the intragroup comparison ( $p=0.1232$ ) (Table 4). The difference between B point was -0,5936 mm in  $\Delta$ T2-T1 and 0,1168 mm in  $\Delta$ T3-T1 (Table 3). This change is insignificant in the intragroup comparison ( $p=0,1574$ ) as presented in Table 4.

In the intergroup comparison, a difference of 0,2178 mm in  $\Delta$ T2-T1 and 0,09025 mm in  $\Delta$ T3-T1 was detected at point A between laser and conventional surgery. These differences are not significant. A difference of 0,1564 mm was observed between  $\Delta$ T2-T1 and -0,4728 mm in  $\Delta$ T3-T1 between laser and conventional surgery at point B. This difference is not significant. The 3D linear measurements intergroup comparison table is presented in Table 3. An intragroup comparison table of 3D linear measurements is presented in Table 4. An intragroup comparison graph of 3D linear measurements is presented in Figure 4.

### 3.3. 2D Angle measurement results

In conventional surgery, angle A was 5,755 degrees greater at  $\Delta$ T2-T1 than in laser surgery. This difference is significant ( $p=0,0401$ ). Angle A was 1,311 degrees greater at  $\Delta$ T3-T1 than in conventional surgery. This difference is not significant ( $p>0,9999$ ). Angle B was -0,9305 degrees different at  $\Delta$ T2-T1 compared to laser and conventional surgery. This difference is insignificant. Angle B was -3,159 degrees different compared to laser and conventional surgery group at the  $\Delta$ T3-T1 time interval. This difference is insignificant.

In the intragroup comparison of angle measurement results mean Angle A was 9.111 degrees at  $\Delta$ T2-T1, and 2,699 degrees at  $\Delta$ T3-T1 in conventional surgery (Table 5). Angle A differed significantly in conventional surgery between  $\Delta$ T2-T1 and  $\Delta$ T3-T1 compared to the intragroup comparison results ( $p=0,0014$ ) (Table 6). The mean angle

**Table 2:** Demographic data

	Male		Female		Total n	Total age avg.
	n	Age Avg.	n	Age Avg.		
Conventional	5	25,8	10	33,6	15	30,8
Laser	5	44,4	14	38,8	19	40
Total	10	35,1	24	36,3	34	36,2

**Table 3:** Intergroup comparison table of 3D linear measurements

Bonferroni's multiple comparisons test	Mean Diff,	95,00% CI of diff,	Conventional (means)	Laser (means)	Summary	Adjusted P Value
<b>Conventional Laser</b>						
Point A T2-T1	0,2178	-0,9589 to 1,395	1,214	0,9958	ns	>0,9999
Point A T3-T1	0,09025	-0,7514 to 0,9319	0,3627	0,2725	ns	>0,9999
Point B T2-T1	0,1564	-1,848 to 2,160	-0,4373	-0,5936	ns	>0,9999
Point B T3-T1	-0,4728	-2,043 to 1,097	-0,3560	0,1168	ns	>0,9999

\*Two-way repeated ANOVA, Bonferroni's multiple comparisons test

**Table 4:** Intragroup comparison table of 3D linear measurements

Bonferroni's multiple comparisons test	Mean Diff,	95,00% CI of diff,	Summary	Adjusted P Value
<b>Conventional</b>				
Point A T2-T1 vs. Point A T3-T1	0,8509	0,2401 to 1,462	**	0,0046
Point A T2-T1 vs. Point B T2-T1	1,651	-0,6319 to 3,934	ns	0,2610
Point A T2-T1 vs. Point B T3-T1	1,570	-0,3925 to 3,532	ns	0,1667
Point A T3-T1 vs. Point B T2-T1	0,8000	-1,362 to 2,962	ns	>0,9999
Point A T3-T1 vs. Point B T3-T1	0,7187	-1,065 to 2,503	ns	>0,9999
Point B T2-T1 vs. Point B T3-T1	-0,08129	-1,037 to 0,8745	ns	>0,9999
<b>Laser</b>				
Point A T2-T1 vs. Point A T3-T1	0,7233	-0,1205 to 1,567	ns	0,1232
Point A T2-T1 vs. Point B T2-T1	1,589	-0,009817 to 3,189	ns	0,0520
Point A T2-T1 vs. Point B T3-T1	0,8790	-0,1715 to 1,929	ns	0,1398
Point A T3-T1 vs. Point B T2-T1	0,8661	-0,6345 to 2,367	ns	0,6266
Point A T3-T1 vs. Point B T3-T1	0,1557	-0,7539 to 1,065	ns	>0,9999
Point B T2-T1 vs. Point B T3-T1	-0,7104	-1,580 to 0,1587	ns	0,1574

\*Two-way repeated ANOVA.

B calculated in conventional surgery was -2,847 degrees at  $\Delta T2-T1$  and 0,7913 degrees at  $\Delta T3-T1$  (Table 5). In the intragroup comparison, in conventional surgery, angle A and angle B were statistically different at the  $\Delta T2-T1$  time interval ( $p=0,0017$ ) and  $\Delta T3-T1$  ( $p=0,0087$ ) (Table 6).

In laser surgery, the mean angle A was 3,356 degrees at  $\Delta T2-T1$  and 1,388 degrees at  $\Delta T3-T1$  (Table 5). In laser surgery, there was no significant difference at  $\Delta T2-T1$  and  $\Delta T3-T1$  in angle A. The mean angle B was -1,917 degrees in  $\Delta T2-T1$  time interval and 3,950 degrees for  $\Delta T3-T1$  in laser surgery. This difference is insignificant. The comparison of angle measurements between groups is summarized in Table 5. An intragroup statistical table of angle measurements is presented in Table 6. An intragroup comparison graph of angle measurements is presented in Figure 5.

### 3.4. EGF Measurement results

The amount of salivary EGF was measured before treatment (T1) and after treatment (T3) by using the ELISA method. The initial amount of EGF (T1) in conventional surgery was 347, 3 ng/ $\mu$ l. It was 438,6 ng/ $\mu$ l at the end of the treatment (T3). In laser surgery, T1 EGF was 537,2 ng/ $\mu$ l, T3 was 475,0 ng/ $\mu$ l (T3).  $\Delta T3-T1$  EGF was -91,25 ng/ $\mu$ l in conventional surgery and -62,12 ng/ $\mu$ l in laser surgery. This difference is not significant. The difference in EGF between the groups at the beginning of the treatment (T1 mean diff.) was 189,8 ng/ $\mu$ l. This difference is significant ( $p=0,0356$ ). At the end of the treatment (T3 mean diff) was 36,44 ng/ $\mu$ l. This difference is not significant. The amounts of salivary EGF were higher in the laser group. However, this difference is not significant. EGF measurement results are presented in Table 7. Saliva EGF differences between group means graph is presented in Figure 6. Saliva EGF concentrations means are presented in Table 8 and Figure 7.

**Table 5:** Intergroup comparison table of angle measurements

Bonferroni's multiple comparisons test	Mean Diff,	95,00% CI of diff,	Conventional (means)	Laser (means)	Summary	Adjusted P Value
<b>Conventional - Laser</b>						
Angle A T2-T1	5,755	0,1952 to 11,31	9,111	3,356	*	0,0401
Angle A T3-T1	1,311	-2,758 to 5,380	2,699	1,388	ns	>0,9999
Angle B T2-T1	-0,9305	-12,51 to 10,65	-2,847	-1,917	ns	>0,9999
Angle B T3-T1	-3,159	-10,91 to 4,592	0,7913	3,950	ns	>0,9999

\*Bonferroni's multiple comparisons test

**Table 6:** Intragroup comparison table of angle measurements

Bonferroni's multiple comparisons test	Mean Diff,	95,00% CI of diff,	Summary	Adjusted P Value
<b>Conventional</b>				
Angle A T2-T1 vs. Angle A T3-T1	6,412	2,408 to 10,42	**	0,0014
Angle A T2-T1 vs. Angle B T2-T1	11,96	4,301 to 19,61	**	0,0017
Angle A T2-T1 vs. Angle B T3-T1	8,319	1,862 to 14,78	**	0,0087
Angle A T3-T1 vs. Angle B T2-T1	5,546	-2,657 to 13,75	ns	0,3416
Angle A T3-T1 vs. Angle B T3-T1	1,907	-5,287 to 9,102	ns	>0,9999
Angle B T2-T1 vs. Angle B T3-T1	-3,639	-7,965 to 0,6874	ns	0,1306
<b>Laser</b>				
Angle A T2-T1 vs. Angle A T3-T1	1,968	-2,531 to 6,467	ns	>0,9999
Angle A T2-T1 vs. Angle B T2-T1	5,273	-7,140 to 17,69	ns	>0,9999
Angle A T2-T1 vs. Angle B T3-T1	-0,5942	-7,720 to 6,531	ns	>0,9999
Angle A T3-T1 vs. Angle B T2-T1	3,305	-9,019 to 15,63	ns	>0,9999
Angle A T3-T1 vs. Angle B T3-T1	-2,562	-9,992 to 4,868	ns	>0,9999
Angle B T2-T1 vs. Angle B T3-T1	-5,867	-16,34 to 4,602	ns	0,6849

\*Two-way repeated ANOVA, \*p&lt;0.05

**Table 7:** Saliva EGF mean difference table

Bonferroni's multiple comparisons test	Mean Diff,	95,00% CI of diff,	Summary	Adjusted P Value
Conventional T3 vs. Conventional T1	91,25	-80,19 to 262,7	ns	0,5987
Laser T3 vs. Laser T1	-62,12	-276,6 to 152,4	ns	>0,9999
Laser T1 vs. Conventional T1	189,8	10,70 to 368,9	*	0,0356
Laser T3 vs. Conventional T3	36,44	-179,0 to 251,9	ns	>0,9999

\*Bonferroni's multiple comparisons test, (ng/ $\mu$ l)**Table 8:** Saliva EGF means. (ng/ $\mu$ l)

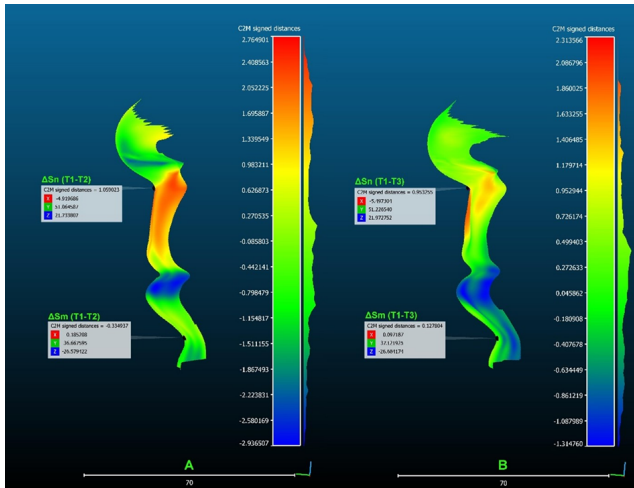
	Conventional T1	Conventional T3	Laser T1	Laser T3
Mean	347,3	438,6	537,2	475,0
Std. Deviation	190,2	129,1	217,3	260,4

#### 4. Discussion

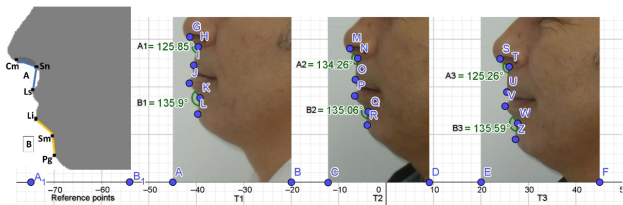
As a result of this study, it was observed that less edema occurred in laser frenectomy compared to conventional frenectomy. There was no significant difference in the amount of salivary EGF at the end of the treatment in laser and conventional surgery.

Lasers can sterilize the tissue and stimulate fibroblasts to synthesize EGF. There is no need for sutures, and less morbidity.<sup>9,27,31</sup> For these reasons, fewer postoperative complications can be expected in laser surgery. The 810

nm diode laser has the lowest tissue removal rate.<sup>32</sup> The temperature difference between the initial tissue temperature and the end of the procedure was higher in the 810 nm diode laser than in the 980, 1470, and 1940 nm lasers.<sup>33</sup> Diode lasers produce energy that penetrates the tissue and causes adjacent tissue heating.<sup>9</sup> Due to this temperature difference the 810 nm diode laser may cause the most edema formation. Conventional surgery is performed via excision with a scalpel.<sup>5</sup> There is no tissue heating in scalpel surgery.<sup>9,33</sup> Epithelialization is rapid in the scalpel, and wound healing is rapid due to the absence of ablated

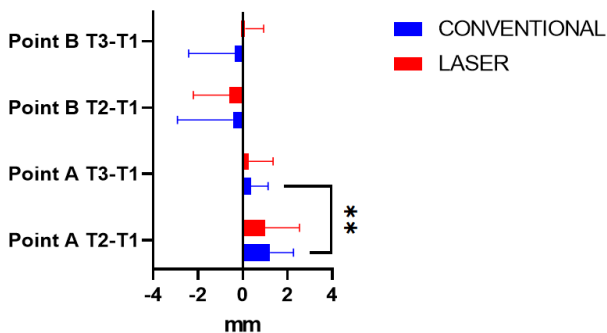


**Fig. 2:** Cloud compare software deviation map (A: T1-T2 and B: T1-T3 cloud/mesh distance difference map measurements). Sn (subnasale) and Sm (mentolabial sulcus) points. T1; baseline, T2; third day post-operation, T3; 14 days post-operation



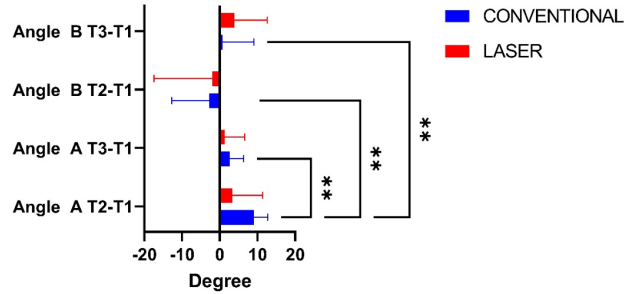
**Fig. 3:** Demonstration of columella point (Cm), subnasale (Sn), labial superior (Ls) in angle A and labial inferior (Li), mentolabial sulcus (Si), soft tissue pogonion (Pg) reference points in angle B and Geogebra software angle measurements in T1-T2-T3

**3D Metrology**



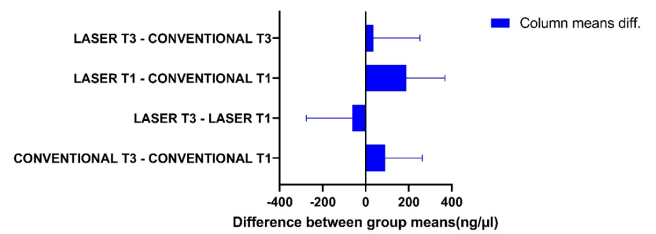
**Fig. 4:** Intragroup comparison graph of 3D linear measurements(\*p<0.005). Point A defines the Sn (subnasale) as the cephalometric landmark and Point B defines the Sm (mentolabial sulcus) as the cephalometric landmark

**2D Cephalometry**



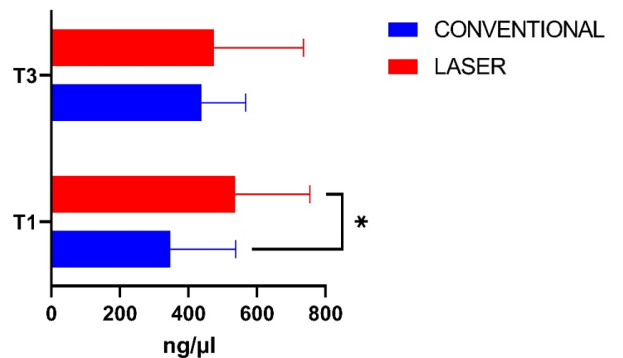
**Fig. 5:** Intragroup comparison graph of angle measurements (\*p<0.05)

**95% Confidence Intervals (Bonferroni)**



**Fig. 6:** Saliva EGF differences between group means graph (ng/μl)

**EGF Saliva concentrations**



**Fig. 7:** Saliva EGF concentrations graph, \*p<0.05

tissue.<sup>9</sup> In scalpel surgery, the surgical area is smaller, and lower EGF, fewer edema, and reduced morbidity may be expected due to the absence of a factor that slows wound healing.

There are studies in which swelling, or edema were measured by tape or visual scoring.<sup>6,29–31,34,35</sup> In the tape measurement method, amount of edema formation is measured by the distance between points, such as the tragus and vermilion.<sup>19</sup> The reproducibility and reliability of this methods is variable.<sup>19</sup> In addition to tape measurements, edema analyses can also be performed with 2D photographs or 3D face-scanning devices.<sup>16–19,36</sup> The reproducibility and

reliability of measurements made with photography and 3D scanners are improved compared to tape or landmark measurement methods.<sup>18,37</sup>

Postoperative edema reaches its maximum level 2 or 3 days after surgery procedure.<sup>15</sup> In this study, the presence of edema was evaluated by taking 2D cephalometric photographs and face scans at 3rd day, and 14th day.<sup>18</sup>

In this study, the 3D face scans on T1 and T3 were superimposed using the fine registration (ICP- Iterative Closest Points) algorithm method, and a difference map was created.<sup>17</sup> The difference between the two scans was accepted as an indicator of edema.<sup>17</sup>

In the literature, studies used an 808 nm laser 1.5-2 W continuous mode, 300  $\mu\text{m}$  fiber,<sup>6</sup> 810 nm 2.5 W 70 Hz 140 ms short pulse mode 400  $\mu\text{m}$  fiber.<sup>28</sup> In this study, laser surgery was performed in contact mode with an 810 nm diode laser in a 2.5 W continuous waveform with a 400  $\mu\text{m}$  fiber tip.<sup>5</sup> Conventional surgery was performed with the help of a scalpel, as described by Archer (1961) and Kruger (1964).<sup>4</sup>

Diode lasers can penetrate deep tissues up to 4-5 mm and generate heat.<sup>33</sup> Wound healing with a diode laser is slower than that with other lasers. An 808 nm diode laser was the latest group used in a study evaluating the wound healing process.<sup>8</sup> Studies were conducted comparing the clinical use of an 808 nm laser and scalpel, and the advantages of the laser regarding patient perceptions, reattachment and healing have been mentioned.<sup>5,6,12</sup> It has been reported that 980 nm diode laser surgery produces a moderate amount of facial edema in %16 of the patients.<sup>38</sup> Similar studies with Er:YAG, Nd:YAG, and other laser systems may provide useful information. It is expected that Er:YAG and Er:CRYSGG lasers will lead to fewer edema due to their cooling systems and reduced tissue penetration.

A study examining face edema after orthognathic surgery reported a decrease in edema of 17.15% in 1 week, 70.51% in the first month, and 81.54% in the third month.<sup>17</sup> Measurements were evaluated in 3D. In the first month, the edema decreased by 70%. In this study, however, the return to baseline was higher in both groups at T3. This difference may be since frenectomy surgery is less invasive than the orthognathic surgery performed by Kau et al. In our study, the amount of edema decreased in all patients on the 14th day in T3. The highest increase in edema formation occurred in the conventional group at T2.

Edema analysis with 3D face scanning is time-consuming and requires additional training.<sup>21,39</sup> The 2D profile or cephalometric analysis is reliable, practical, and requires minimal additional training.<sup>39,40</sup> For this reason, angles A and B were evaluated to analyze edema formation from 2D profile images, as shown in Figure 3. The edema formation in the maxilla region were calculated with angle A. According to the study results, angle A significantly increases on the 3<sup>rd</sup> day in conventional surgery. It returns

to its initial state on the 14<sup>th</sup> day. There was no significant change in angle A in laser surgery.

Twenty-four women and 10 men participated in the study. The gender distribution of the individuals included in the study is not equal. Menstrual cycle can affect wound healing, facial edema, and pain perception, which is one of the negatives in this study.<sup>5,41-43</sup>

The amounts of salivary EGF were compared due to the ablated tissue acting as a laser bandage in the laser-applied area and the epithelialization process of the area left for secondary wound healing during surgery. Interestingly the amount of salivary EGF is significantly different at T1. Laser applied group has 189,8 ng/ $\mu\text{l}$  higher EGF than conventional surgery group (Table 7). This difference may be explained by the wide age range in our study and the EGF release can differ by age.<sup>44</sup> The amount of salivary EGF was reported to be higher in patients who underwent periodontal surgery.<sup>25</sup> In this study, EGF increased in conventional group and decreased in laser group after the frenectomy procedure. However, in T3 there is no significant difference in both groups. Difference in conventional surgery  $\Delta\text{T3-T1}$  was 91,25 ng/ $\mu\text{l}$ . This was higher than laser surgery difference as 36,44 ng/ $\mu\text{l}$  found in  $\Delta\text{T3-T1}$ . This change is not significant. The absence of a significant difference between the amounts of EGF in T3 should be significant considering the age difference in the study participants and the significant difference in T1. The  $\Delta\text{T3-T1}$  difference in means of EGF in conventional surgery was higher than that in laser surgery. This may be because the wound healing is delayed in laser surgery and there is an ablated surface in the wound area. In the laser group, the mean age was higher than in conventional surgery. This may influence the change in EGF level after frenectomy.

EGF measurements were taken on T1 and T3 day. EGF was not taken on T2 because there may be blood in the saliva due to secondary healing in the surgery site.

#### 4.1. Study limitations and future directions for research in this field

1. Gender distribution and the use of only an 810 nm diode laser are limitations of the study.
2. In a study of Fornaini et al., the lowest wound healing rate was found with 810 nm laser and the highest was found for the 1950 nm laser.<sup>32</sup> For this reason, studies using laser types other than an 810 nm diode laser and involving more participants should be conducted.
3. The wide age range and the inability to measure EGF in T2, the unequal age distribution among the groups are the limitations of the study in EGF measurements.
4. EGF measurements should also be evaluated in the wound exudates.



## 5. Conclusions

1. The 810 nm laser surgery produced less edema than conventional surgery.
2. In the intragroup comparison, a significant increase in edema formation was detected at T2 in conventional surgery. No significant increase in edema was detected in 810 nm laser surgery.
3. No significant difference was found between the amounts of salivary EGF in 810 nm laser and conventional surgery. EGF increased in conventional group and decreased in laser group after the frenectomy procedure at T3.
4. The 2D cephalometric angle analysis and 3D face scan analysis are reliable and reproducible methods for evaluating edema formation after frenectomy surgery.

## 6. Source of Funding

This research was funded by Mersin University Scientific Research Projects Management Unit, grant number 2019-1-AP1-3319.

## 7. Availability of Data and Materials

The datasets generated and/or analyzed during the current study are not publicly available due ethical privacy or ethical restrictions but are available from the corresponding author on reasonable request.

## 8. Ethics Approval and Consent to Participate

The study was conducted in accordance with the Declaration of Helsinki and approved by the Institutional Ethics Committee of Mersin University (protocol code, 78017789/050,01,04/804076-2018/308; date of approval, 26/07/2018). Informed consent was obtained from all the subjects involved in the study

## 9. Consent for Publication

Written informed consent was obtained from the patients to publish this paper.

## 10. Conflicts of Interest

The authors declare no conflict of interest.

## Acknowledgements


Not applicable.

## References

1. Pié-Sánchez J, España-Tost AJ, Arnabat-Domínguez J, Gay-Escoda C. Comparative study of upper lip frenectomy with the CO2 laser versus the Er, Cr:YSGG laser. *Med Oral Patol Oral Cir Bucal*. 2012;17(2):228–32.
2. Boutsis EA, Tatakis DN. Maxillary labial frenum attachment in children. *Int J Paediatr Dent*. 2011;21(4):284–8.
3. Protásio ACR, Galvão EL, Falci SGM. Laser Techniques or Scalpel Incision for Labial Frenectomy: A Meta-analysis. *J Maxillofac Oral Surg*. 2019;18(4):490–9.
4. Devishree, Gujjari SK, Shubhashini PV. Frenectomy: a review with the reports of surgical techniques. *J Clin Diagn Res*. 2012;6(9):1587–92.
5. Sezgin G, Özener H, Meseli SE, Kuru L. Evaluation of Patient's Perceptions, Healing, and Reattachment After Conventional and Diode Laser Frenectomy: A Three-Arm Randomized Clinical Trial. *Photobiomodul Photomed Laser Surg*. 2020;38(9):552–9.
6. Babu B, Koppolu P, Mishra A, Pandey R, Swapna LA, Uppada UK. Evaluation of patient perceptions after labial frenectomy procedure: A comparison of diode laser and scalpel techniques. *Eur J Gen Dent*. 2014;3(2):129–33.
7. Uraz A, Çetiner FD, Cula S, Guler B, Oztoprak S. Patient perceptions and clinical efficacy of labial frenectomies using diode laser versus conventional techniques. *J Stomatol Oral Maxillofac Surg*. 2018;119(3):182–6.
8. D'arcangelo C. 2007.
9. Patel RM, Varma S, Suragimath G, Abbayya K, Zope SA, Kale V. Comparison of labial frenectomy procedure with conventional surgical technique and diode laser. *J Dent Lasers*. 2015;9(2):94–9.
10. Zaaba N, Rajasekar A, Sundari KKS. Evaluation of healing following frenectomy. *Bioinformation*. 2021;17(12):1138–43.
11. Guru PE. Envelope Flap Vs Modified Flap In Mandibular 3rd Molar Disimpaction Surgery. *Int J Dent Oral Sci*. 2021;p. 3756–60. doi:10.19070/2377-8075-21000770.
12. Kalakonda B, Farista S, Koppolu P, Baroudi K, Uppada U, Mishra A, et al. Evaluation of patient perceptions after vestibuloplasty procedure: a comparison of diode laser and scalpel techniques. *J Clin Diagn Res*. 2016;10(5):96–100.
13. Politis C, Schoenaers J, Jacobs R, Agbaje JO. Wound Healing Problems in the Mouth. *Front Physiol*. 2016;7:507. doi:10.3389/fphys.2016.00507.
14. Vanani FN, Golestaneh A, Malekigorji M. Comparison of Pain, Wound Healing, Facial Edema, and Surgeon's Comfort in Surgical Extraction of Impacted Third Molars: Surgical Scalpel Versus Radiofrequency Incision. *J Res Dent Maxillofac Sci*. 2020;5(2):2–6.
15. Santos TDS, Osborne PR, Jacob ES, Araújo RTE, Nogueira CBP. Effects of Water-Circulating Cooling Mask on Postoperative Outcomes in Orthognathic Surgery and Facial Trauma. *J Craniofac Surg*. 2020;31(7):1981–5.
16. Jaroń A, Preuss O, Grzywacz E, Trybek G. The Impact of Using Kinesio Tape on Non-Infectious Complications after Impacted Mandibular Third Molar Surgery. *Int J Environ Res Public Health*. 2021;18(2):399.
17. Kau CH, Cronin A, Durning P, Zhurov AI, Sandham A, Richmond S. A new method for the 3D measurement of postoperative swelling following orthognathic surgery. *Orthod Craniofac Res*. 2006;9(1):31–7.
18. Ulu M, Gözlüklü Ö, Kaya Ç, Ünal N, Akçay H. Three-Dimensional Evaluation of the Effects of Kinesio Taping on Postoperative Swelling and Pain after Surgically Assisted Rapid Palatal Expansion. *J Oral Maxillofac Res*. 2018;9(4):e3.
19. Koçer G, Sönmez S, Findik Y, Yazici T. Reliability of the Linear Measurement (Contact) Method Compared with Stereophotogrammetry (Optical Scanning) for the Evaluation of Edema after Surgically Assisted Rapid Maxillary Expansion. *Healthcare (Basel)*. 2020;8(1):52.
20. Villafuerte-Núñez AE, Téllez-Anguiano AC, Hernández-Díaz O, Rodríguez-Vera R, Gutiérrez-Gnecchi JA, Salazar-Martínez JL, et al. Facial Edema Evaluation Using Digital Image Processing. *Discrete Dynamics Nat Soc*. 2013;doi:10.1155/2013/927843.
21. Amornvit P, Sanohkan S. The Accuracy of Digital Face Scans Obtained from 3D Scanners: An In Vitro Study. *Int J Environ Res Public Health*. 2019;16(24):5061.
22. Kusnoto B. Two-dimensional cephalometry and computerized orthognathic surgical treatment planning. *Clin Plast Surg*. 2007;34(3):417–26.

23. Pellegrini G, Rasperini G, Pagni G, Giannobile WV, Milani S, Musto F, et al. Local wound healing biomarkers for real-time assessment of periodontal regeneration: pilot study. *J Periodontol Res*. 2017;52(3):388–96.
24. Dereka XE, Markopoulou CE, Vrotsos IA. Role of growth factors on periodontal repair AU - Dereka. *Growth Factors*. 2006;24(4):260–7.
25. Oxford GE, Nguyen KH, Alford CE, Tanaka Y, Humphreys-Beher MG. Elevated salivary EGF levels stimulated by periodontal surgery. *J Periodontol*. 1998;69(4):479–84.
26. Pastar I, Stojadinovic O, Yin NC, Ramirez H, Nusbaum AG, Sawaya A. Epithelialization in Wound Healing: A Comprehensive Review. *Adv Wound Care (New Rochelle)*. 2014;3(7):445–64.
27. Gkogkos AS, Karoussis IK, Prevezanos ID, Marcopoulou KE, Kyriakidou K, Vrotsos IA. Effect of Nd:YAG Low Level Laser Therapy on Human Gingival Fibroblasts. *Int J Dent*. 2015;2015:258941. doi:10.1155/2015/258941.
28. Ozener HO, Meseli S, Sezgin G, Kuru L. Clinical Efficacy of Conventional and Diode Laser-Assisted Frenectomy in Patients with Different Abnormal Frenulum Insertions: A Retrospective Study. *Photobiomodul Photomed Laser Surg*. 2020;38(9):565–70.
29. Haytac MC, Ozelik O. Evaluation of patient perceptions after frenectomy operations: a comparison of carbon dioxide laser and scalpel techniques. *J Periodontol*. 2006;77(11):1815–9.
30. Kara C. Evaluation of Patient Perceptions of Frenectomy: A Comparison of Nd:YAG Laser and Conventional Techniques. *Photomed Laser Surg*. 2008;26(2):147–52.
31. Parker S, Anagnostaki E, Mylona V, Cronshaw M, Lynch E, Grootveld M. Systematic Review of Post-Surgical Laser-Assisted Oral Soft Tissue Outcomes Using Surgical Wavelengths Outside the 650-1350 nm Optical Window. *Photobiomodul Photomed Laser Surg*. 2020;38(10):591–606.
32. Fornaini C, Merigo E, Sozzi M, Rocca JP, Poli F, Selleri S, et al. Four different diode lasers comparison on soft tissues surgery: a preliminary <i>ex vivo</i> study. *Laser Ther*. 2016;25(2):105–14.
33. Fornaini C, Merigo E, Sozzi M, Selleri S, Vescovi P, Cucinotta A. 810nm, 980nm, 1470nm and 1950nm diode laser comparison: a preliminary “ex vivo” study on oral soft tissues. *SPIE BiOS*. 2015;doi:10.1117/12.2079048.
34. Akpınar A, Tokar H, Alpan AL, Çalıřır M. Postoperative discomfort after Nd:YAG laser and conventional frenectomy: comparison of both genders. *Aust Dent J*. 2016;61(1):71–5.
35. Calisir M, Ege B. Evaluation of patient perceptions after frenectomy operations: A comparison of neodymium-doped yttrium aluminum garnet laser and conventional techniques in the same patients. *Niger J Clin Pract*. 2018;21(8):1059–64.
36. Keyhan SO, Fallahi HR, Cheshmi B, Mokhtari S, Zandian D, Yousefi P. Use of piezoelectric surgery and Er:YAG laser: which one is more effective during impacted third molar surgery? *Maxillofac Plast Reconstr Surg*. 2019;41(1):29.
37. Alan H. Evaluation of the effects of the low-level laser therapy on swelling, pain, and trismus after removal of impacted lower third molar. *Head Face Med*. 2016;12(1):25.
38. Aldelaimi TN, Mahmood AS. Laser-Assisted Frenectomy Using 980nm Diode Laser. *J Dent Oral Disord Ther*. 2015;2(4):1–6.
39. Zogheib T. Comparison of 3D Scanning Versus 2D Photography for the Identification of Facial Soft-Tissue Landmarks. *Open Dent J*. 2018;12:61–71.
40. Malkoç S, Demir A, Uysal T, Canbuldu N. Angular photogrammetric analysis of the soft tissue facial profile of Turkish adults. *Eur J Orthod*. 2009;31(2):174–9.
41. Engeland CG, Sabzehei B, Marucha PT. Sex hormones and mucosal wound healing. *Brain Behav Immun*. 2009;23(5):629–35.
42. Lopez MM, Castillo AC, Kaltwasser K, Phillips LG, Moliver CL. Surgical Timing and the Menstrual Cycle Affect Wound Healing in Young Breast Reduction Patients. *Plast Reconstr Surg*. 2016;137(2):406–10.
43. Tacani PM, Ribeiro DO, Guimarães BEB, Machado AFP, Tacani RE. Characterization of symptoms and edema distribution in premenstrual syndrome. *Int J Womens Health*. 2015;7:297–303.
44. Gresik EW, Brennan M, Azmitia E. Age-Related Changes in EGF and Protease in Submandibular Glands of C57BL/6J Mice1,4. *Gerodontology*. 1982;1(2):81–4.

#### Author biography

**Burak AK**, Assistant Professor  <https://orcid.org/0000-0001-5013-6588>

**Cite this article:** Burak AK. Evaluation of edema formation and salivary EGF related to 810 nm diode laser and conventional surgery after frenectomy. *J Oral Med, Oral Surg, Oral Pathol, Oral Radiol* 2023;9(1):27-36.