

Content available at: <https://www.ipinnovative.com/open-access-journals>

Journal of Oral Medicine, Oral Surgery, Oral Pathology and Oral Radiology

Journal homepage: [www.joooo.org](http://www.joooo.org)

## Case Report

# A rare case of bilateral pulse granuloma of maxilla

Kavita Wadde<sup>1</sup>, Sandhya Kokitkar<sup>1,\*</sup>, Tabita Joy Chettiankandy<sup>2</sup>,  
Samir Khaire<sup>1</sup>, Asha Chowdhur<sup>1</sup>, Nivedhitha Maraimalai<sup>2</sup>

<sup>1</sup>Dept. of Oral and Maxillofacial Surgery, Government Dental College and Hospital, Mumbai, Maharashtra, India

<sup>2</sup>Dept. of Oral Pathology and Microbiology, Government Dental College and Hospital, Mumbai, Maharashtra, India



## ARTICLE INFO

### Article history:

Received 14-04-2023

Accepted 18-05-2023

Available online 02-06-2023

### Keywords:

Giant cell hyaline angiopathy

Hyaline ring granuloma

Pulse granuloma

## ABSTRACT

Pulse or hyaline ring granulomas are rare but are well-defined oral and extraoral lesions due to implantation of the cellulose moiety of plant foods in contrast starch components. Implantation could be through extraction sockets, deep periodontal pockets, associated with tumor growth, interdental areas of teeth, unfilled root canals, and grossly decayed teeth. These get rapidly digested and altered by host responses. It is Microscopic oral inflammatory lesion characterized by the presence of giant cells and hyaline rings. The features of pulse granuloma are not considered clinically distinctive and remain primarily microscopic. Extensive knowledge of abnormal sites of origin and clinical manifestations enables clinicians to recognize the diagnostic risks of confusing pulse granuloma with other entities.

This is an Open Access (OA) journal, and articles are distributed under the terms of the [Creative Commons Attribution-NonCommercial-ShareAlike 4.0 License](https://creativecommons.org/licenses/by-nc-sa/4.0/), which allows others to remix, tweak, and build upon the work non-commercially, as long as appropriate credit is given and the new creations are licensed under the identical terms.

For reprints contact: [reprint@ipinnovative.com](mailto:reprint@ipinnovative.com)

## 1. Introduction

An uncommon giant cell granulomatous disease of the mouth called a pulse granuloma appears in response to implantation of food.<sup>1</sup> Since the first report that was described by Lawrens, its etiopathogenesis has remained debatable.<sup>2</sup> It has been discovered in a number of places, including the mouth, uterine tubes, skin, and lungs.<sup>3,4</sup>

Oral pulse granulomas are most often seen in edentulous jaws or in patients with a history of recent dental procedures. They have been observed in the walls of keratocysts, nasopalatine cysts, residual cysts of the periapical region, and granulomas involving carious teeth with exposed tooth roots or teeth that have undergone unsuccessful endodontic therapy.<sup>5–7</sup>

The aetiopathogenesis of pulse granuloma is a complex one evolved from two concepts, i.e., exogenous and endogenous. Most authors favor the exogenous origin for

these lesions, based on the suggestion of implantation of food particles.

Plant origin especially of leguminous (pulse) origin, enter through extraction sockets, deep periodontal pockets, unfilled root canals and grossly decayed teeth. Whereas, the endogenous origin is suggested to be localized degenerative changes in the walls of blood vessels, collagen degeneration, etc.<sup>8,9</sup> Treatment is local excision and curettage. Recurrence is rare (Discussion with percentage of available) Most of granulomas are clinical masses and concerning of neoplasia hence excision and histopathological report of it are of importance. Pulse granulomas are harmless lesions but can often mimic malignancy. So accurate diagnosis can prevent mismanagement.<sup>10</sup>

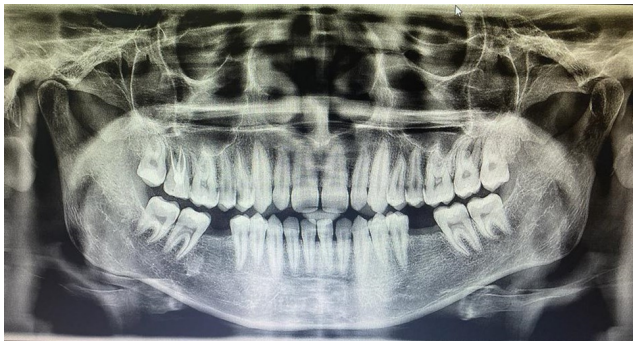Here we present a case of bilateral oral pulse granuloma that was initially misdiagnosed are a endo-perio lesions in bilateral maxillary molars.

\* Corresponding author.

E-mail address: [sandhyakokitkar@gmail.com](mailto:sandhyakokitkar@gmail.com) (S. Kokitkar).

## 2. Case Report

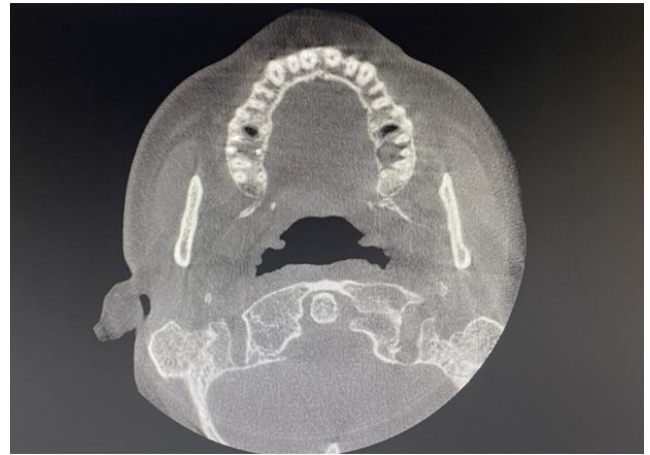A 30-year-old male patient reported to department of Oral and maxillofacial surgery with a chief complaint of occasional pain and pus discharge in upper right and left back tooth region for the last 4 years. Patient had visited private dental clinic for the same issue for which RCT of 17 was done. However, the patient did not obtain any relief post RCT. Patient then reported to the department of Oral and maxillofacial surgery, GDCH. Patient's medical history was non-contributory. Family history revealed that his brother had died of Non-Hodgkin's 3 years back. Clinical examination revealed a sinus tract with respect to 17 with active pus discharge. Pocket depth measuring 10 mm was seen with respect to 17 and 27 on the palatal aspect. Neither of the teeth were tender on percussion, fractured nor mobile. There was no evidence of swelling, ulceration associated with either tooth. Orthopantomograph revealed a periapical radiolucency in relation to 17 with a sclerotic rim indicating periapical pathology and a radiolucency in relation to 17 and radiopaque structure in root canals of 17 suggestive of endodontically treated 17 (Figure 1). CT scan showed well-defined bilateral radiolucency at the apices of 17,27 (Figure 2). Provisional diagnosis of periapical abscess with 17 and 27. Differential diagnoses considered were radicular cyst and periapical granuloma.



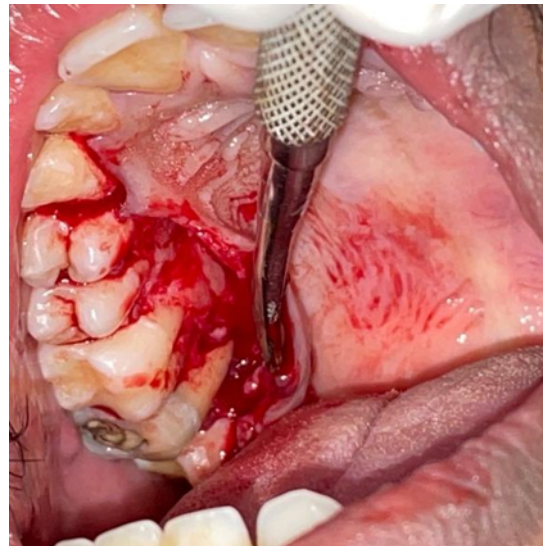
**Fig. 1:** OPG showing Root canal treated tooth #17 with periapical radiolucency and deep periodontal pocket on distal aspect. # 27 also shows periapical radiolucency

Under Local anaesthesia, crevicular incision was taken around teeth 15,16,17 on the buccal and palatal aspect. A full thickness mucoperiosteal flap was raised. Granulation tissue was evident on the root surfaces. The tissue was carefully curetted out and send for histopathological examination (Figure 3). Similar procedure was repeated with respect to 27. Granulation tissue similar to that seen in 17 region was seen and removed to send for histopathological examination.

H and E-stained slide under microscopic examination showed multiple bits of tissue consisting of surface epithelium and connective tissue stroma. Low power view shows fibro cellular connective tissue stroma devoid of



**Fig. 2:** Axial section of CT scan showing periapical radiolucency with 17,27

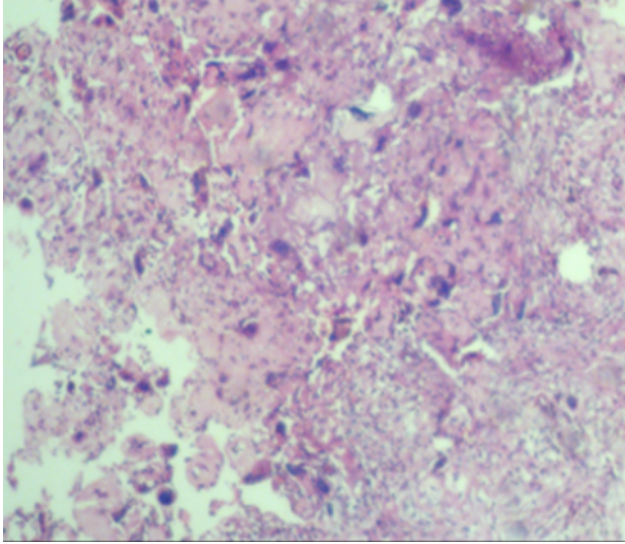


**Fig. 3:** Palatal flap is raised to expose the lesion

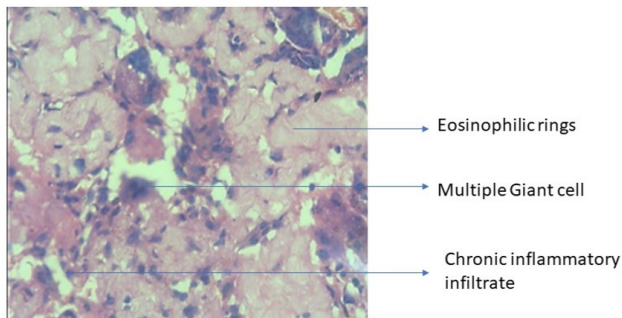
epithelium in most of the areas. Diffuse moderate chronic inflammatory cells infiltrative was noted throughout the connective tissue stroma. Dense collagen fibres were haphazardly arranged and interspersed with fibroblast. Few foci showed presence of multiple eosinophilic amorphous masses surrounded by multinucleated foreign body type giant cells were seen suggestive of pulse granuloma (Figures 4 and 5). After 3 months post-operative IOPA was taken which showed bone formation at roots of 17 when compared to previous IOPA.(Figure 6)

## 3. Discussion

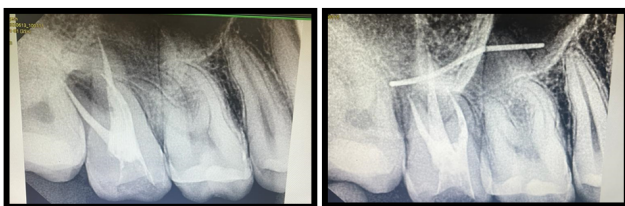
Oral pulse hyaline ring granuloma (OPHRG) is rare finding and associated mostly with mandible.<sup>11</sup> Our case was rare at it was seen in maxillary molar region and was bilateral.



**Fig. 4:** Microscopic examination shows multiple eosinophilic amorphous masses enclosed by multiple foreign body giant cells (10X, H&E)



**Fig. 5:** Microscopic examination shows multiple eosinophilic amorphous masses enclosed by multiple foreign body giant cells (40X, H&E)



**Fig. 6:** Preoperative IOPA showing periapical radiolucency and post-operative IOPA showing bone formation

208 cases with OPHRGs have been tabulated and reviewed by Swetha Acharya et al. in 2019 Including a total of 173 patients OPHRGs that were reviewed by Philipsen and Reichart, those reported from 1971 to 2008 in their literature review. Out of which 72.8% were found in mandible.

Two theories for etiopathogenesis have been proposed: Exogenous theory-the origin of the hyaline rings is due to a foreign material (pulse and legumes) having penetrated the oral mucosa and the Endogenous theory where the rings are formed due to hyaline degenerative changes in walls of blood vessels (endogenous theory). In the oral cavity, these are most often seen in edentulous jaws or in patients with a history of pericoronitis in impacted teeth, in postextraction tissue reaction or as part of a cyst wall where there has been a communication with oral cavity or as a complication of periodontal surgery or associated with deep periodontal pockets.<sup>8,9</sup>

Pulse granulomas also found in lung and gastrointestinal tract. They are clinically occurring masses considered as pseudotumors. OPHRG has distinct histopathological aspects from PG of the lungs and gut as starch cells are often absent, and giant cells may be scant.<sup>10,12</sup>

Radiographic examination is not pathognomic of pulse granulomas, intra-osseous pulse granuloma manifests as an irregular radiolucent lesion and extra-osseous presents as poorly defined erosion of the crest of the alveolar ridge.<sup>11</sup>

According to Chou et al<sup>9</sup> treatment for pulse granuloma is curettage or total excision with which recurrence is rare, but may occur, usually associated with incomplete removal. Once aware of its etiology, the dentist could be able to prevent the disease and to better guide patients, especially those with removable prostheses. and also, those in postoperative period, since the tissue is healing and, therefore, is more susceptible to the inoculation of food debris.

Oral pulse granuloma is a rare entity in which no features considered clinically pathognomic of pulse granuloma and remains largely a microscopic diagnosis.<sup>13</sup> A more widespread knowledge on the unusual sites of occurrence and clinical manifestations may aware the clinicians about the diagnostic hazard of mistaking pulse granulomas for other entities. For clinicians, it is very useful to know hyaline ring granuloma, not only because other diseases (which require different therapeutic approaches) can mimic it, leading to misdiagnosis of relevant impact, but also because some clinical situations increase the risk of its occurrence.

#### 4. Conclusion

It is important to know about pulse granuloma as foreign body reaction can impair the healing process. Apart from this the histopathological differential diagnoses enlist a lot of granulomatous diseases like tuberculosis. So, it



is important to have complete case history and proper clinicopathological correlation to avoid overdiagnosis of this reactive condition.

## 5. Source of Funding

Nil.

## 6. Conflict of Interest

Nil.

## 7. Patient Consent Declaration


Declaration of patient consent-Informed Consent obtained from the patient eosinophilic.


## References

- Simon JH, Chimenti RA, Mintz GA. Clinical significance of the pulse granuloma. *J Endod.* 1982;8(3):116–9.
- Lewars PH. Chronic periostitis in the mandible underneath artificial dentures. *Br J Oral Surg.* 1971;8(3):264–9.
- Knoblich R. Pulmonary granulomatosis caused by vegetable particles. So-called lentil pulse pneumonia. *Am Rev Respir Dis.* 1969;99(3):380–9.
- Kumar M, Narasimha A, Prasad C, Deo R. Pulse granuloma of the parotid gland masquerading as carcinoma - A case report with review of literature. *J Clin Biomed Sci.* 2011;1(1):25–9.
- Gueiros LA, Silva ARS, Romañach MJ, Leon JE, Lopes MA, Jorge J. Distinctive aspects of oral hyaline ring granulomas. *Oral Surg Oral Med Oral Pathol Oral Radiol Endod.* 2008;106(2):e35–9.
- Kotrashetti VS, Angadi PV, Mane DR, Hallikerimath SR. Oral pulse granuloma associated with keratocystic odontogenic tumor: Report of a case and review on etiopathogenesis. *Ann Maxillofac Surg.* 2011;1(1):83–6.
- Talacko AA, Radden BG. Oral pulse granuloma: Clinical and histopathological features. *Int J Oral Maxillofac Surg.* 1988;17(6):343–6.
- Philipsen HP, Reichart PA. Pulse or hyaline ring granulomas. Review of the literature on etiopathogenesis of oral and extra-oral lesions. *Clin Oral Investig.* 2010;14(2):121–8.
- Chou L, Ficarra G, Hansen LS. Hyaline ring granuloma: a distinct oral entity. *Oral Surg Oral Med Oral Pathol.* 1990;70(3):318–24.
- Nowacki NB, Arnold MA, Frankel WL, Harzman A, Limketkai BN, Yearsley MM, et al. Gastrointestinal tract-derived pulse granulomata: clues to an underrecognized pseudotumor. *Am J Surg Pathol.* 2015;39(1):84–92.
- Acharya S, Hallikeri K, Anehosur V, Okade A. Oral pulse or hyaline ring granuloma: A case report and a brief review. *J Indian Soc Periodontol.* 2015;19(3):327–32.
- Mulla HM, Vibhute N, Baad R, Shashikiran ND, Parker M, Parmod RC. An insight into diagnosis of a hidden entity: Impacted food material. *Indian J Dent Res.* 2018;29(1):41–5.
- Kimura TC, Carneiro MC, Coelho YFS, deSousa S, Veltrini VC. Hyaline ring granuloma of the mouth-A foreign-body reaction that dentists should be aware of: Critical review of literature and histochemical/immunohistochemical study of a new case. *Oral Dis.* 2021;27(3):391–403.


## Author biography


**Kavita Wadde**, Professor and Head  <https://orcid.org/0000-0002-0127-0876>

**Sandhya Kokitkar**, Postgraduate Student  <https://orcid.org/0009-0000-4312-8758>

**Tabita Joy Chettiankandy**, Professor and Head  <https://orcid.org/0000-0002-6839-6959>

**Samir Khaire**, Associate Professor  <https://orcid.org/0000-0002-4367-0077>

**Asha Chowdhar**, Postgraduate Student  <https://orcid.org/0000-0002-3914-9262>

**Nivedhitha Maraimalai**, Postgraduate Student  <https://orcid.org/0000-0003-1208-3088>

**Cite this article:** Wadde K, Kokitkar S, Chettiankandy TJ, Khaire S, Chowdhar A, Maraimalai N. A rare case of bilateral pulse granuloma of maxilla. *J Oral Med, Oral Surg, Oral Pathol, Oral Radiol* 2023;9(2):108-111.