



Content available at: <https://www.ipinnovative.com/open-access-journals>

Journal of Oral Medicine, Oral Surgery, Oral Pathology and Oral Radiology

Journal homepage: www.joooo.org



Original Research Article

A comparison of one point versus two point fixation in the management of zygomatico-maxillary complex fractures

Abhinandan Patel K N¹, Girish Gowda¹, Prajwal K Bharadwaj^{1*}, Preethi Bhat¹, Sindhu Iyengar¹

¹Dept. of Facio-Maxillary Surgery, Sanjay Gandhi Institute of Trauma & Orthopaedics, Bengaluru, Karnataka, India



ARTICLE INFO

Article history:

Received 12-01-2024

Accepted 01-02-2024

Available online 13-03-2024

Keywords:

Tripod fracture
Internal fixation
Osteosynthesis

ABSTRACT

Background: The zygomaticomaxillary complex (ZMC) fractures are highly frequent injuries. There is a variety of operative techniques for fixation of ZMC fractures, with no consensus about the best technique. We aim to compare one-point versus two-point fixation of tripod zygomatic fractures.

Materials and Methods: This study was carried out on 34 patients admitted to the trauma unit in Sanjay Gandhi Institute of Trauma and Orthopaedics in the period from September 2022 to August 2023. Patients were divided into two groups (group 1; one-point fixation, and group 2; two-point fixation).

Results: When compared to the one-point fixation group, only 14 patients had substantial stability with a P-value of <0.05 being statistically significant. In contrast, nearly all patients in the two-point fixation group had higher stability. In the two-point fixation group, nearly all patients had a post-operative scar; in the one-point fixation group, however, only two patients had the same scar, and the mouth opening was also improved. In two-point fixation, paraesthesia was observed in nearly seven patients, while in one-point fixation, it was present in only two patients.

Conclusion: The one-point fixation technique for tripod ZMC fractures is considered effective as the two-point fixation technique; and it offers advantages of scarless operation, reduced operation time, fewer complications, and lower cost.

This is an Open Access (OA) journal, and articles are distributed under the terms of the [Creative Commons Attribution-NonCommercial-ShareAlike 4.0 License](https://creativecommons.org/licenses/by-nc-sa/4.0/), which allows others to remix, tweak, and build upon the work non-commercially, as long as appropriate credit is given and the new creations are licensed under the identical terms.

For reprints contact: reprint@ipinnovative.com

1. Introduction

The zygomatic bone articulates with the frontal, sphenoid, temporal, and maxillary bones, defining the anterior and lateral projection of the face. The mid-facial contour and the contents of the orbits are safeguarded by the zygomatic complex. One of the most frequent facial injuries in maxillofacial trauma is zygomatic complex fracture, which primarily affects young adult males.¹ The distinctive tetrapod configuration of the ZMC, which articulates with several bones, defines the cheek prominence, the inferior and lateral orbital boundaries, and the anterolateral aspect

of the face.^{2,3}

If these fractures are not attended to, they may lead to functional and aesthetic deficits such as;

1. Loss of facial symmetry
2. Paraesthesia of the infraorbital nerve
3. Depressed malar prominence
4. Limited mouth opening
5. Obstruction of the lacrimal duct, epiphora
6. Diplopia, orbital dystopia,
7. Enophthalmos, and loss of vision when related to orbital floor fractures.

Variable surgical techniques have been performed to achieve satisfactory outcomes e.g. the Gillies' temporal approach,

* Corresponding author.

E-mail address: prajbhar.bharadwaj@gmail.com (P. K. Bharadwaj).

upper eyelid, lateral eyebrow, sub-ciliary, transconjunctival, and intraoral approaches.⁴⁻⁶

Achieving anatomic reduction and stable fixation is the major objective of the treatment in order to avoid functional or cosmetic impairments following surgery.

Hence, the current study compares the stability and aesthetic outcome of one- point versus two-point fixation of tripod zygomatic fractures by using miniplates, through assessment of clinical and radiological outcomes.

2. Aim

To analyze and compare the stability, aesthetic appearance in zygomatic complex fractures after open reduction with single point and two-point fixation.

3. Objectives

1. To evaluate the stability of single point fixation of ZMC fractures.
2. To evaluate the stability of two-point fixation of ZMC fractures.
3. To evaluate the aesthetic appearance post operatively after open reduction in single- and two-point fixation of ZMC fractures.
4. To evaluate the post operative mouth opening and stability of fracture.
5. To evaluate the complications, if any.

4. Materials and Methods

The procedures followed were in accordance with the ethical standards of the responsible committee on human experimentation (institutional or regional) and with the Helsinki Declaration of 1975, as revised in 2000. The study was conducted on subjects reporting to the Department of Faciomaxillary Surgery, XXX. Randomization was carried out using sequentially numbered, opaque, sealed envelopes as the allocation concealment scheme (simple random technique). Each envelope contained the names of either group one or group two to which the patients will be allotted. A prospective study segregating the patients into one point fixation group and two-point fixation group will be done before the proposed procedure. All patients with tripod fractures of the zygoma will undergo computed tomography (CT) scans before and after ORIF. Group 1 consisting of 17 patients will undergo open reduction with 1-point (zygomatico-maxillary buttress region) internal fixation through a buccogingival incision, and group 2 composed of another 17 patients will undergo open reduction with 2-point (zygomatico-maxillary buttress and fronto-zygomatic regions) internal fixation through buccogingival and lateral eyebrow incisions. Clinically all the patients will be assessed as a part of follow-up protocol at one week, 3 weeks, 6 weeks after the procedure for the following factors:

1. Facial contour, malar symmetry,
2. Eye globe position, neurosensory disturbance of the infraorbital nerve,
3. Mouth opening and occlusal stability,
4. Continuity of the fracture (PNS X-ray or CT scans).

In patients under group 2 (Two point fixation group), lateral eyebrow incision e.g. unsightly scar or keloid formation, and complications of the miniplates e.g. infection and palpability of the plate will also be assessed. (FIGURE 2, 2a, 3, 3a, 4, 4a, 5, 5a, 5b, 5c)

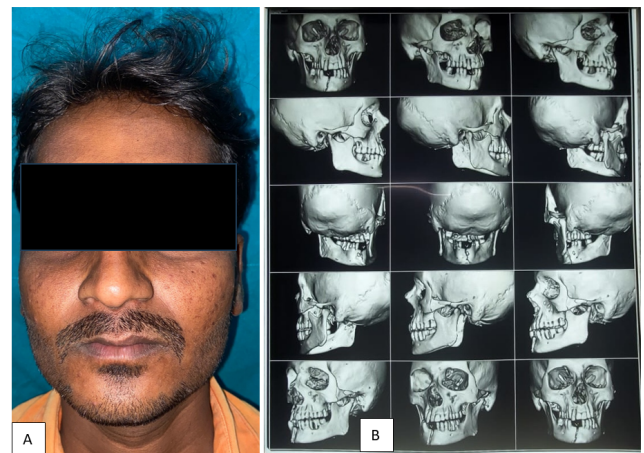

Figure 1: A): Frontal view of the patient; B): Pre-operative 3D CT scan depicting fracture of right zygomatico-maxillary complex

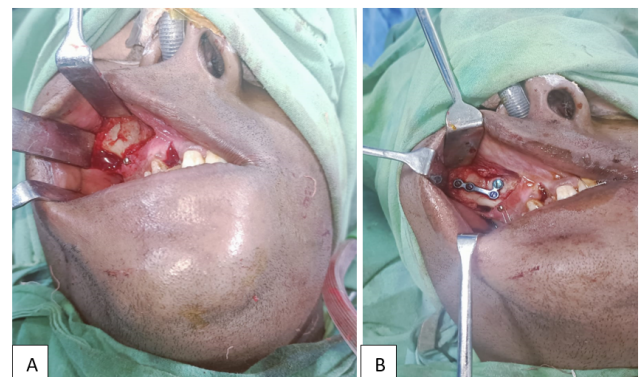


Figure 2: A): Intra operative view of right zygomatico-maxillary buttress showing the fracture line; B): Depicting reduction and fixation with titanium miniplates and screws of right zygomatico-maxillary buttress

4.1. Inclusion criteria

1. Patients with tripod zygomatic fractures that are indicated for open reduction and internal fixation by miniplates and screws.
2. Displacement of fracture less than 5mm at the fronto-zygomatic region.

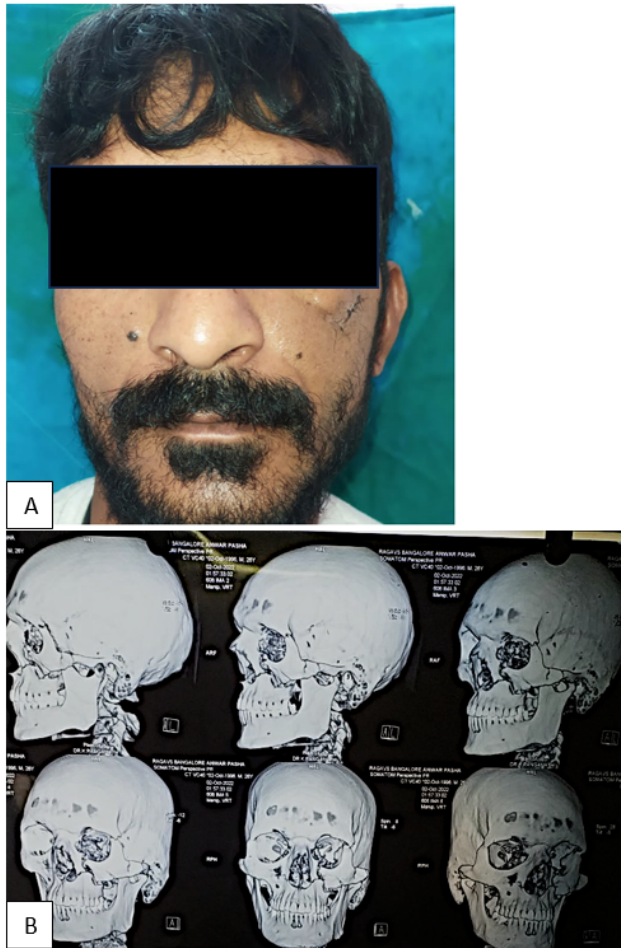

Figure 3: A): Frontal view of the patient for two point fixation; B): Pre-operative 3D CT scan depicting fracture of left zygomatico-maxillary complex

4.2. Exclusion criteria

1. Patients with Pan-facial fractures.
2. Patients with associated Le fort I/II/III maxillary fractures.
3. Patients with Orbital blow-in/out fractures.

4.3. Preoperative evaluation of patients

This includes clinical examination, radiological and laboratory investigations. All cases were evaluated clinically by taking a full history, general examination and maxillofacial examination for signs of zygomatic complex fractures. Also, assessment of the infraorbital nerve injury and ophthalmological evaluation were documented. Radiological evaluation through CT scan of facial bones in three-dimensional (3D) reconstruction film, axial and coronal planes.

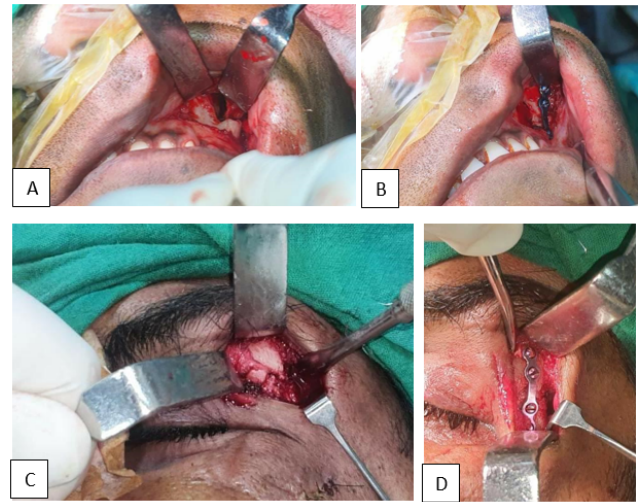


Figure 4: A): Intraoperative view of left zygomatico-maxillary buttress showing the fracture line; B): Depicting reduction and fixation with titanium miniplates and screws of left zygomatico-maxillary buttress; C): Intra operative view of fractured left fronto-zygomatic suture/ lateral orbital rim; D): Depicting reduction and fixation with titanium miniplates and screws of fronto-zygomatic screws

4.4. Number and name of the groups

1. Patients treated with 1- point fixation in zygomaticomaxillary buttress region.
2. Patients treated with 2- point fixation in zygomaticomaxillary and frontozygomatic region.

4.5. Study parameters

1. VC- Vertical change which represents the movement of the bilateral infraorbital rim line.
2. HC- Horizontal change which represents the movement of the bilateral anterior margins of the fossa temporal is line.

4.6. Armamentarium (Figure 5)

1. Titanium mini plates- 2mm straight 'L' plates
2. Titanium miniplates- 1.5mm 4-holed straight plates
3. Titanium screws 6 mm, 8 mm
4. Surgical screw holder, Screw driver and
5. Basic surgical Instruments
6. Plate bender

5. Results

When compared to the one-point fixation group, only 14 patients had substantial stability with a P-value of <0.05 being statistically significant. In contrast, nearly all patients in the two-point fixation group had higher stability. In the

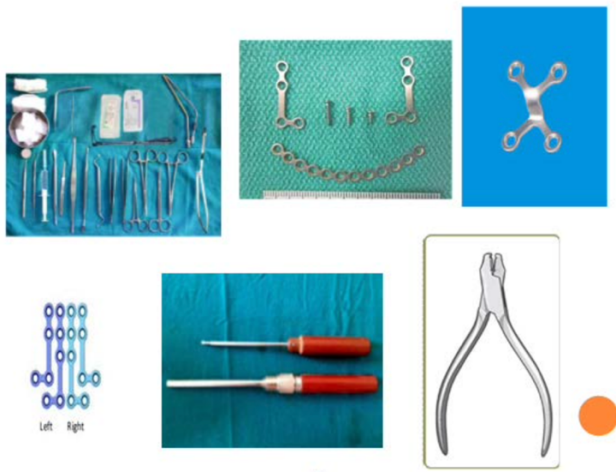

Figure 5: Basic armamentarium for open reduction and internal fixation

two-point fixation group, nearly all patients had a post-operative scar; in the one-point fixation group, however, only two patients had the same scar, and the mouth opening was also improved. In two-point fixation, paresthesia was observed in nearly seven patients, while in one-point fixation, it was present in only two patients. (Tables 1, 2, 3, 4, 5 and 6)

Table 1 shows the stability among one point and two-point fixation. The stability was present in almost all the patients in two-point fixation whereas only 14 individuals had stability in one point fixation. P-value <0.05 is considered to be statistically significant. The comparison for stability clearly shows that statistically significant difference was seen among one- and two-point fixation. In stability, two-point fixation stands ahead superior than one point fixation.

Table 2 shows the scar among one point and two-point fixation. The scar was present in almost all the patients in two-point fixation whereas only 2 individuals had scar in one point fixation. P-value <0.05 is considered to be statistically significant. The comparison for scar clearly shows that statistically significant difference was seen among one- and two-point fixation. In scar, one-point fixation stands ahead superior than two-point fixation.

Table 3 shows the comparison of mouth opening among one point and two-point fixation. The mean of mouth opening was higher in one point fixation (41.17) than two-point fixation (38.94). Statistically significant difference for mouth opening was seen.

Table 4 shows the complication among one point and two-point fixation. The complication was present in 2 patients in two-point fixation whereas only no individuals had complication in one point fixation. P-value <0.05 is considered to be statistically significant. The comparison for complication clearly shows that statistically significant

difference was seen among one- and two-point fixation. In complication, two-point fixation stands ahead superior than one-point fixation.

Table 5 shows the paraesthesia among one point and two-point fixation. The paraesthesia was present in almost 7 patients in two-point fixation whereas only 2 individuals had paraesthesia in one point fixation. P-value <0.05 is considered to be statistically significant. The comparison for paraesthesia clearly shows that statistically significant difference was seen among one- and two-point fixation. In paraesthesia, two-point fixation stands ahead superior than one-point fixation.

Table 6 shows the comparison of satisfactory score among one point and two-point fixation. The mean of score was higher in two-point fixation (9.17) than one-point fixation (8.70). Statistically significant difference for satisfactory score was seen.

6. Discussion

One crucial component of the facial structure is the zygomaticomaxillary complex. The orbit, maxilla, and temporal fossa are all related to the zygoma, a diamond-shaped bone in the centre part of the face. Its faces are temporal, orbital, and lateral. The frontozygomatic suture (FZS), infraorbital rim, zygomaticomaxillary buttress, and zygomaticotemporal suture are the four articulations of the zygoma. With the exception of the nose, it sustains injuries more frequently than any other facial feature due to its placement.^{7,8}

While occasional traumas may result in a fracture of the antral wall or orbital rim alone, the majority of injuries involve the zygomatic bone, hence the term "zygomaticomaxillary." the mandibular mobility implications. Most midface fractures are caused by trauma to the zygomatic complex, and for these fractures, early intervention is usually seen to be the best course of action.^{9–11}

However, 1-point fixation in the FZ area through a lateral eyebrow incision usually leaves external scars, palpability of plates, and swelling resulting from severed muscle and soft tissue. Because the soft tissue overlying the FZ area is very thin, thin plates must be used to prevent visibility, sensibility, and palpability. One-point fixation in the ZM area does not leave external scars or palpability of plates or screws. In addition, when plates or screws are removed, a buccogingival incision leaves no external scars. Repeated lateral eyebrow incisions may give more chances to leave external scars.^{12,13}

In ZMC fractures, maintaining reduction is the goal of bone repair for both practical and aesthetic reasons. Studies on biomechanics have tried to identify the forces operating on the ZMC and how they can impact fixation methods. Although the masseter is the primary muscle responsible for ZMC displacement, its actual impact on the result of surgery

Table 1: Comparison of stability among one point and two point fixation

Stability	One point fixation		Two point fixation	
	Frequency (N)	Percentage (%)	Frequency (N)	Percentage (%)
Yes	14	82.3	17	100
No	3	17.7	0	0
P-value				0.048*

Table 2: Comparison of scar among one point and two point fixation

Scar	One point fixation		Two point fixation	
	Frequency (N)	Percentage (%)	Frequency (N)	Percentage (%)
Yes	2	8.9	17	100
No	15	91.1	0	0
P-value				0.015*

Table 3: Comparison of mouth opening among one point and two point fixation

Variables	One point fixation	Two point fixation
Mean	41.1765	38.9412
Std. Error of Mean	.63729	1.05882
Std. Deviation	2.62762	4.36564
Variance	6.904	19.059
Range	8.00	14.00
Minimum	38.00	32.00
Maximum	46.00	46.00
P-value		0.013*

Table 4: Comparison of complication (Oedema) among one point and two point fixation

Oedema	One point fixation		Two point fixation	
	Frequency (N)	Percentage (%)	Frequency (N)	Percentage (%)
Yes	0	0	2	8.9
No	17	100	15	91.1
P-value				0.048*

Table 5: Comparison of paraesthesia among one point and two point fixation

Paraesthesia	One point fixation		Two point fixation	
	Frequency (N)	Percentage (%)	Frequency (N)	Percentage (%)
Yes	2	8.9	7	41.2
No	15	91.1	10	58.8
P-value				0.021*

Table 6: Comparison of satisfactory score among one point and two point fixation

Variables	One point fixation	Two point fixation
Mean	8.7059	9.1765
Std. Error of Mean	.14258	.09531
Std. Deviation	.58787	.39295
Variance	.346	.154
Range	2.00	1.00
Minimum	7.00	9.00
Maximum	9.00	10.00
P-value		0.07*

remains a matter of controversy. When a ZMC fracture lasts four to six weeks, Dal Santo et al. showed a substantial reduction in ipsilateral masseteric force. Furthermore, elevating masseteric attachments from the zygoma using an intraoral method to exposure may potentially have an impact on muscle performance. Asymmetry following reduction is found to be between 10 and 13%. Fracture instability is not as likely to be the cause of this malar asymmetry as it is imprecise reduction.^{12–14}

Tarabichi noted that in vitro studies are deceptive due to the lack of serration along the orbital rim and the disregard of the roles of the superficial musculoaponeurotic system, uninterrupted periosteum, and skin in stabilising a fractured zygoma. reported successful results with trans-sinus reduction through the comminuted anterior wall of the sinus and 1-point fixation of malar fractures. Fujioka et al. proposed that in their in vivo analysis, when the fracture was not comminuted and 3-point alignment was obtained, 1-point fixation at the zygomaticomaxillary compartment was adequately robust.^{14,15}

Thus, 1-point fixation at the ZMB area should be sufficiently stable for tripod fractures if it is not difficult to reduce displacement of the F-Z process and a comminuted fracture of the infraorbital rim and zygomatic arch using ultrasonography. Two-point fixation should be done in the ZMB as well as the F-Z compartment additional lateral canthal incision if the lateral orbital rim is comminuted.

7. Conclusion

According to our research, the zygomatico-maxillary complex can be sufficiently stabilised by 1-point fixation at the ZMB without suffering from comminuted fractures of the lateral orbital rim. Additionally, in certain patients with zygomatic tripod fractures, one-point fixation in the zygomatico-maxillary buttress region can prevent ugly scars and provide excellent surgical outcomes.

When there is a small preoperative bone gap in the F-Z area, single point fixation in the ZM area is preferable; however, when there is a large bony gap in the FZ area, two-point fixation is preferable. However, the scar in the FZ area and the palpability of the prosthesis there make the two-point fixation patients unhappy.

In the FZ area, absorbable plates or microplates could be employed to prevent the prosthesis from being palpable. It is an excellent fixation by intraoral maxillary vestibular technique (Balasubramanian's or Keen's Intra oral approach) to prevent multiple surgical incision, probable infection, additional scar, and nerve palsy. For ZMC minimally displaced fractures with little post-operative problems, ZM buttress fixation is considerably superior.

8. Study Limitations

Since each author's assessment of the parameters was different, it was impossible to standardise them for

comparison. In one study, Kim et al. (2017) observed no statistically significant differences between the two groups (three-point fixation and two-point fixation) in terms of post-operative stability.

The authors of two studies, Hasse et al. (2011) and Ji et al. (2016), did not state which type of fixation was better in their investigation; nonetheless, they came to the conclusion that since there are numerous fixation techniques accessible, the best method to treat ZMC fractures is to use a safe, facilitated procedure.

9. Source of Funding

None.

10. Conflict of Interest

None.

Acknowledgments

We acknowledge Department of Orthopaedics and Emergency Services, Sanjay Gandhi Institute of Trauma and Orthopaedics. This paper has not been presented or published anywhere by any of the authors.

References

1. Kim ST, Go DH, Jung JH, Cha HE, Woo JH, Kang IG. Comparison of 1-point fixation with 2-point fixation in treating tripod fractures of the zygoma. *J Oral Maxillofac Surg.* 2011;69(11):2848–52.
2. Kim JH, Lee JH, Hong SM, Park CH. The effectiveness of 1-point fixation for zygomaticomaxillary complex fractures-a systematic review. *Arch Otolaryngol Head Neck Surg.* 2012;138(9):828–32.
3. Gadkari N, Bawane S, Chopra R, Bhate K, Kulkarni D. Comparative evaluation of 2-point vs 3-point fixation in the treatment of zygomaticomaxillary complex fractures-a systematic review. *J Craniomaxillofac Surg.* 2019;47(10):1542–50.
4. Pozatek ZW, Kaban LB, Guralnick WC. Fractures of the zygomatic complex: an evaluation of surgical management with special emphasis on the eyebrow approach. *J Oral Surg.* 1973;31(2):141–8.
5. Kumar PS, Gurkarpalsingh M. Retrospective Comparison of One Point Fixation versus Two Point Fixation in the Treatment of Tripod Fractures. *IOSR J Dent Med Sci.* 2019;18(3):37–43.
6. Ebenezer V, Ramalingam B, Sivakumar M. Treatment of zygomatic complex fractures using two point fixation under general anaesthesia. *World J Med Sci.* 2014;10(2):179–83.
7. Chakranarayan A, Thapliyal GK, Sinha R, Suresh MP. Efficacy of two point rigid internal fixation in the management of zygomatic complex fracture. *J Maxillofac Oral Surg.* 2009;8(3):265–9.
8. Tarabichi M. Transsinus reduction and one-point fixation of malar fractures. *Arch Otolaryngol Head Neck Surg.* 1994;120(6):620–5.
9. Hwang K. One-point fixation of tripod fractures of zygoma through a lateral brow incision. *J Craniofac Surg.* 2010;21(4):1042–4.
10. Zaleckas L, Pečiulienė V, Gendvilienė I, Pūrienė A, Rimkuvienė J. Prevalence and etiology of midfacial fractures: a study of 799 cases. *Medicina (Kaunas).* 2015;51(4):222–7.
11. Ellis E, Kittidumkerng W. Analysis of treatment for isolated zygomaticomaxillary complex fractures. *J Oral Maxillofac Surg.* 1996;54(4):386–400.
12. Shumrick KA, Kersten RC, Kulwin DR, Smith CP. Criteria for selective management of the orbital rim and floor in zygomatic

- complex and midface fractures. *Arch Otolaryngol Head Neck Surg.* 1997;123(4):378–84.
13. Bos RR, Boering G, Rozema FR, Leenslag JW. Resorbable poly (L-lactide) plates and screws for the fixation of zygomatic fractures. *J Oral Maxillofac Surg.* 1987;45(9):751–3.
14. Gruss JS, Wyck LV, Phillips JH, Antonyshyn O. The importance of the zygomatic arch in complex midfacial fracture repair and correction of posttraumatic orbitozygomatic deformities. *Plast Reconstr Surg.* 1990;85(6):878–90.
15. Luck JD, Lopez J, Faateh M, Macmillan A, Yang R, Davidson EH, et al. Pediatric zygomaticomaxillary complex fracture repair: Location and number of fixation sites in growing children. *Plast Reconstr Surg.* 2018;142(1):51–60.

Author biography

Abhinandan Patel K N, Professor and HOD

Girish Gowda, Assistant Professor and Fellowship Guide

Prajwal K Bharadwaj, Fellow Maxillofacial Trauma
 <https://orcid.org/0009-0001-9560-299X>

Preethi Bhat, Consultant

Sindhu Iyengar, Fellowship, Maxillofacial Trauma

Cite this article: Patel K N A, Gowda G, Bharadwaj PK, Bhat P, Iyengar S. A comparison of one point versus two point fixation in the management of zygomatico-maxillary complex fractures. *J Oral Med, Oral Surg, Oral Pathol, Oral Radiol* 2024;10(1):20-26.