



Content available at: <https://www.ipinnovative.com/open-access-journals>

Journal of Oral Medicine, Oral Surgery, Oral Pathology and Oral Radiology

Journal homepage: www.joooo.org



Original Research Article

Clinical and radiological assessment of open and closed reduction of inferior orbital rim fracture

Abhinandan Patel¹, Girish Gowda¹, Suhas Molahally Shetty^{1*}, Preethi Bhat¹, Yoshita Gowda¹

¹Dept. of Oral & Maxillofacial Surgery, Sanjay Gandhi Institute of Trauma & Orthopedics, Bengaluru, Karnataka, India



ARTICLE INFO

Article history:

Received 11-01-2024

Accepted 06-02-2024

Available online 13-03-2024

Keywords:

Inferior orbital rim

Closed reduction

Open reduction

ABSTRACT

Background: In maxillofacial traumas, zygomaticomaxillary complex (ZMC) and orbital blow out fractures are commonly encountered midfacial fractures that may result in aesthetic and functional impairment. Orbital floor injuries can occur in isolation or in association with zygomaticomaxillary complex fractures. We aim to assess Clinical and radiological outcome of open and closed reduction of inferior orbital rim fracture.

Materials and Methods: This study was carried out on 34 patients admitted to the trauma unit in Sanjay Gandhi Institute of Trauma and Orthopaedics in the period from September 2022 to August 2023. Patients were divided into two groups (group 1; closed reduction, and group 2; open reduction).

Results: When compared with group 1 group 2 patient had better post operative outcome. None of the patients in group 2 complained about blurred vision, ocular motility restriction, and infra orbital nerve paraesthesia. In group 2 patients there is significant changes in orbital volume postoperatively compared to group 1. More stable fracture reduction was noted in group 2. When compared to the group 1 patients, 90% of the patients had substantial stability with a P-value of <0.05 being statistically significant.

Conclusion: Open reduction and internal fixation of inferior orbital rim has better outcome postoperatively. Apart from the inconspicuous scar in the infra orbital region, the patient had better quality of life.

This is an Open Access (OA) journal, and articles are distributed under the terms of the [Creative Commons Attribution-NonCommercial-ShareAlike 4.0 License](https://creativecommons.org/licenses/by-nc-sa/4.0/), which allows others to remix, tweak, and build upon the work non-commercially, as long as appropriate credit is given and the new creations are licensed under the identical terms.

For reprints contact: reprint@ipinnovative.com

1. Introduction

In maxillofacial traumas, zygomaticomaxillary complex (ZMC) and orbital blow out fractures are commonly encountered midfacial fractures that may result in aesthetic and functional impairment. Orbital floor injuries can occur in isolation or in association with zygomaticomaxillary complex fractures.^{1,2} The four potential sites of fixation as follows: the zygomaticomaxillary buttress (ZMB), the lateral orbital rim (LOR), the zygomatic arch (ZA), and the inferior orbital rim (IOR). The need to address one or more fixation points of these four articulations mainly depends on the degree

of displacement: one-point fixation is usually done at the ZMB; two-point fixation is usually done at the ZMB + LOR; three-point fixation is usually done at the ZMB + LOR + IOR; only severely displaced fractures require four-point fixation.³ The zygoma plays an important role in the facial contour for both cosmetic and functional reasons; therefore, zygomatic bone injuries should be properly diagnosed and adequately treated.¹ Comparison of various surgical approaches and their complications can only be done objectively using outcome measurements that require a protocol for management and long-term follow-up.⁴ Fractures of the orbital floor may lead to an increase in orbital volume and may result in limitation of vertical and horizontal ocular movements, diplopia, enophthalmos, and

* Corresponding author.

E-mail address: suhasshetty18@gmail.com (S. M. Shetty).

altered sensation in the distribution area of the infraorbital nerve.⁵ It's always been the controversy of fixing the inferior orbital rim in terms of two point fixation. The behaviour of the orbital floor is questionable when the rim is just only reduced and when it is reduced and fixed. The clinical outcomes also depends on the approach that is used to expose and fix the inferior orbital rim. This study aims at the assessing the bony changes and clinical outcome that occurs in different treatment methodology, that is closed and open reduction of inferior orbital rim.

2. Aim

To assess the clinical outcome and bony changes of open reduction and closed reduction of inferior orbital rim fracture.

3. Objectives

1. To evaluate the clinical outcomes post operatively.
2. To evaluate the bony changes radiologically.

4. Materials and Methods

The study will be conducted on subjects reporting to the Department of Faciomaxillary Surgery, Sanjay Gandhi Institute of Trauma and Orthopedics, Bangalore. Randomization will be carried out using sequentially numbered, opaque, sealed envelopes as the allocation concealment scheme (simple random technique). Each envelope contained the names of either group one or group two to which the patients will be allotted. All patients with tripod fractures of the zygoma will undergo computed tomography (CT) scans before and after ORIF. Group 1 consisting of 10 patients will undergo closed reduction of inferior orbital rim, zygomatico-maxillary buttress region internal fixation through a buccogingival incision and FZ through lateral eyebrow incision. Group 2 composed of another 10 patients will undergo open reduction with open reduction and internal fixation of zygomatico-maxillary buttress, fronto-zygomatic region and inferior orbital rim regions through buccogingival, lateral eyebrow incisions and infra-orbital incision respectively.

Clinical outcome of the patient is assessed at follow ups of 1 week and 1 month post-operative interval.

4.1. Assessment of clinical outcomes

1. Infraorbital hypesthesia
2. Ocular motility
3. Diplopia
4. Blurry vision

Immediate post operative 3D CT face and aids in assessing the radiological changes from pre op to post op. (Figures 1, 2, 3 and 4)

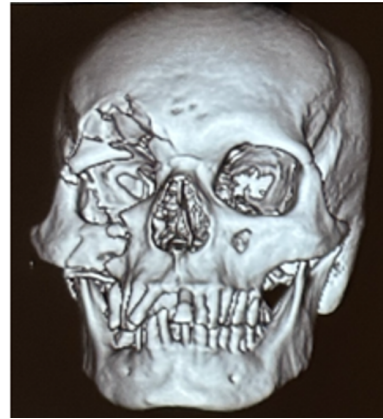

Figure 1: Preoperative 3DCT scan of the patient

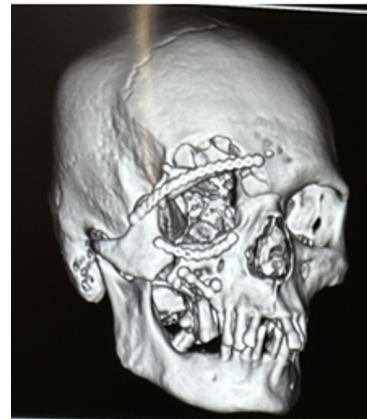


Figure 2: Post operative 3DCT scan of the patient depicting rim continuity

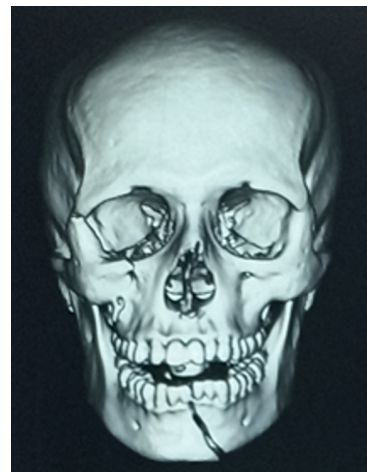

Figure 3: Preoperative 3DCT scan of the patient

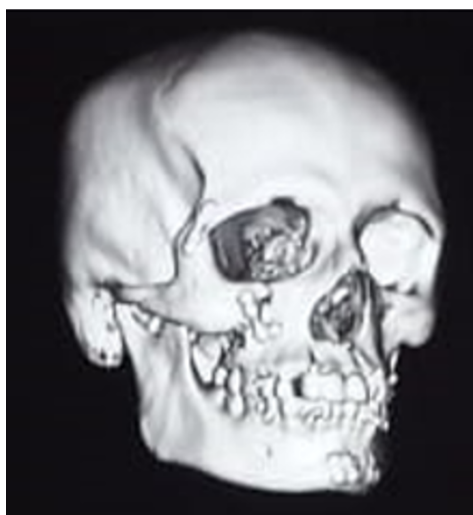

Figure 4: Post operative 3DCT scan of the patient depicting rim discontinuity and step deformity

4.2. Assessment of radiological outcomes

1. Rim continuity
2. Orbital volume
3. Orbital floor continuity

4.3. Inclusion criteria

1. Unilateral zygomaticomaxillary complex fractures involving inferior orbital rim.
2. Age group above 18 years.

4.4. Exclusion criteria

1. Presence of systemic or ocular diseases, such as glaucoma, cataract, or contralateral blindness.
2. Presence of congenital deformities of the face.
3. History of previous treated or untreated facial trauma

4.5. Preoperative evaluation of patients

This includes clinical examination, radiological and laboratory investigations. All cases were evaluated clinically by taking a full history, general examination and maxillofacial examination for signs of zygomatic complex fractures. Also, assessment of the infraorbital nerve injury and ophthalmological evaluation were documented. Radiological evaluation through CT scan of facial bones in three-dimensional (3D) reconstruction film, axial and coronal planes.

4.6. Number and name of the groups

1. Patients treated with closed reduction of infraorbital rim fracture.

2. Patients treated with open reduction of infraorbital rim fracture.

4.7. Armamentarium

1. Titanium mini plates- 2mm straight 'L' plates
2. Titanium miniplates- 1.5mm 4-holed straight plates and curved plate
3. Titanium screws 6 mm, 8 mm
4. Surgical Screw Holder, Screw Driver and
5. Basic Surgical Instruments
6. Plate bender

5. Results

Patients were divided into four age groups that less than 30 years, 31 to 40 years, 41 to 50 years and more than 50 years. In group A 40% of patients belong to age group of below 30 years, 10% fall between age group of 31 to 40 years, 30% fall in between 41 to 50 years. And 20 % belong to age group of more than 50 years.

In group B, 20% of the patients belong to age group of below 30 years, 40% of them belong to age group of 31 to 40 years, another 20% of them fall into group of 41 to 50 years, last 20 % of the fall into more than 50 years.

Etiology for the traumas were mainly Road traffic accidents, assaults and fall at their workplace or residence. In group A 70% of the patients had injury because of RTA, another 20% were due to assault and rest 10% were due to fall. Whereas in group B 60% of the patients has RTA, 30% were injured because of assaults and rest 10% were due to fall.

As per one of the parameter, the neurological findings that is infraorbital paraesthesia. In group A where infraorbital rim fracture were managed conservatively 50% of the patients presented with infraorbital paraesthesia and other 50% had no signs of paraesthesia. In group B 90% of them had no paraesthesia and 10% presented with paraesthesia post operatively.

Another parameter is about the ocular motility that is about the restrictions in the ocular movements. In group A where the involved rim fracture is managed conservatively, 50% of the patients had restricted ocular movements in superior gaze. Whereas in group B the involved rim fracture is managed with ORIF and post operatively none of them complained of restricted ocular motility.(Figure 5)

In group A, post operatively 50% of the patient complained of not resolving diplopia and in group B none of the patient reported back with complaint of diplopia

In group A, 50% of the patient complained of blurred vision postoperatively, whereas in group B no patient had complained about blurred vision postoperatively.

In group A, 60% of the patients had discrepancy in rim continuity which was appreciated on palpation and post op scans. Whereas in group B, no patients had palpable

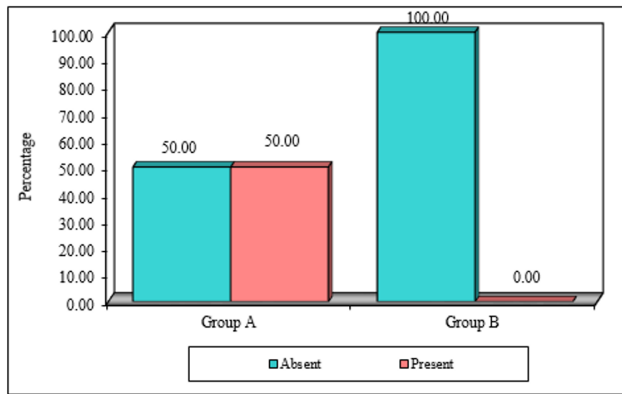


Figure 5: Bar graph representing comparison of pre operative and post operative ocular motility

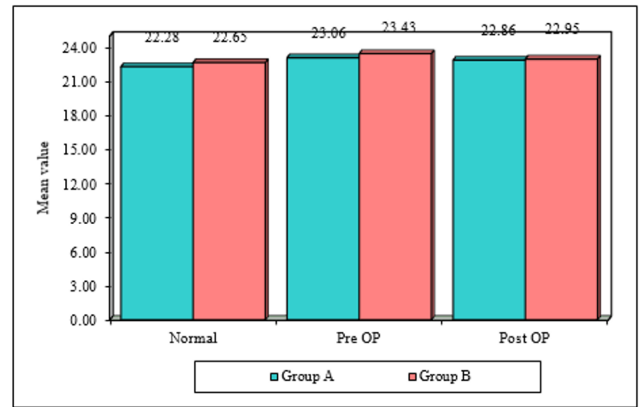


Figure 7: Bar graph representing comparison in between pre operative and post-operative orbital volume with contralateral unaffected eye

discrepancy in rim continuity, post-operatively. (Figure 6)

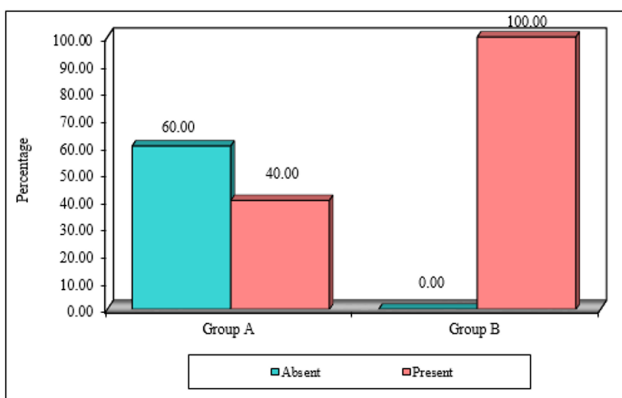


Figure 6: Bar graph representing comparison of pre operative and post operative Rim continuity

In group A, 60% of the patients post-operative scans showed discrepancy in the floor continuity. In group B, none of the patients post-operative scans showed any major discrepancy in the scans.

Orbital volume is measured in CT. In group A, there is significant difference in the volume of the involved orbit when compared with the contralateral orbital volume of the same patient. There is increase in the volume of the involved orbit. Post operatively there is decrease in the volume of the involved orbit. Whereas in group B the difference in significant in the volume of the involved orbits volume when compared with its pre op to post op. (Figure 7)

6. Discussion

Zygomatic complex fractures are quadri-pod fractures because of the involvement of the zygomaticotemporal, zygomaticomaxillary, zygomaticofrontal, and Zygomatico-sphenoid junctions. The need to address one or more fixation points of these four articulations mainly depends

on the degree of displacement.^{5,6} Zygomaticomaxillary complex (ZMC) and orbital blow out fractures are commonly encountered midfacial fractures that may result in aesthetic and functional impairment.^{1,2}

The principles of zygomatic complex fractures and their management are well described in the literature.⁵ Surgical methods of ZMC fracture fixation have evolved over the years, beginning with wires for osteosynthesis all the way to miniplate fixation and even biodegradable plates and screws. Traditional teaching recommends three-point fixation for ZMC fractures, based on biomechanical studies.⁷

In our current study, patients in group A were managed with closed reduction of the infraorbital rim fracture. Whereas group B was managed using open reduction and internal fixation. In group B, clinical assessment of neurological status, ocular motility, diplopia, and blurred vision were found to have a superior clinical outcome than group A. Radiological assessment of orbital volume, rim continuity and orbital floor continuity were noted to be better in cases where the orbital rim was addressed.⁸

Al-Qattan et al, in his study concluded that restoring displaced orbital fractures will lead to restoration of the orbital volume.^{5,9} Most of the injury to the nerve was owing to compression following depression and rotation of the zygomatic complex requiring infraorbital rim fixation and surgical intervention. The incidence of postoperative infraorbital nerve sequelae was diminished considerably in unstable zygomatic fractures when treated by osteosynthesis with mini-plates. Patients who did not receive any treatment had some degree of paraesthesia.^{10,11}

Even minimally displaced zygomatic-complex fractures can result in functional and aesthetic deformities. A study by A H Malik et al., noticed corneal injury in 32% of cases and diplopia in 20.89% of cases.¹² Many surgeons prefer exploration of the orbital floor in patients having symptomatic diplopia. It is believed that the orbital floor

defect is more likely to decrease than increase after reduction of the ZMC fracture as the floor defect may appear small on preoperative imaging.⁷

In dislocated fractures, two or three fixation points are necessary, depending on the grade, site of dislocation and whether the fractures are of the comminuted type. Dislocation of the frontozygomatic rim necessitates open reduction at this site. In these patients, reduction and fixation are started in the frontozygomatic area, because a precise reduction is usually achievable, even in cases of multi-fragmented fractures. In addition, reduction and fixation at this site acts as a guide for the following fixations.^{13,14}

Ali Ebrahimi et al., in his study derived a conclusion that ZMC fractures commonly increase orbital volume on the affected side and this finding is highly correlated with enophthalmos.² Hence, fixation of the orbital rim would maintain the continuity of orbit which in turn affects the orbital volume.

Supporting this study, Rohner et al, advocated that placing a plate at 3 points of fixation improved structural strength.¹⁵ On contrary to our study, Gawande et al.,¹ stated that 2 point fixation at fronto-zygomatic and zygomatico-buttress without fixation of the orbital rim would result in lesser post-operative complications.

ZMC fractures observe soft-tissue preservation and advocate a “less-is-more” approach. Nonetheless, S J. Farber and colleagues in their review of ZMC fractures came into conclusion that, more comminuted high-energy ZMC fractures require wider exposure and greater fixation.⁷ Choice of number and site of fixation points depends mainly on the degree of displacement and preference of the surgeon.

7. Conclusion

Our study mainly aimed at assessing the clinical outcomes and radiological findings of the zygomatico maxillary complex fracture associated with orbital fractures. In two of our groups we compared the tripod fractures fixation at three points and two points.

Among both the group, the group B patients where orbital rim was reduced and fixed using titanium miniplates had less post-operative complaints. The diplopia, blurred vision, restricted ocular motility and infraorbital paraesthesia were resolved post-operatively and rim continuity, floor continuity and orbital volume were found to be better and improved. functionally this technique provides better prognosis and outcome. However, scar over inferior orbital rim incision and palpability of the implant makes the open reduction technique unhappy.

8. Source of Funding

None.

9. Conflict of Interest

None.

References

- Gawande MJ, Lambade PN, Bande C, Gupta MK, Mahajan M, Dehankar T. Two-point versus three-point fixation in the management of zygomaticomaxillary complex fractures: a comparative study. *Ann Maxillofac Surg.* 2021;11(2):229–35.
- Schneider M, Besmens IS, Luo Y, Giovanoli P, Lindenblatt N. Surgical management of isolated orbital floor and zygomaticomaxillary complex fractures with focus on surgical approaches and complications. *J Plast Surg Hand Surg.* 2020;54(4):200–6.
- Ebrahimi A, Motamedi MH, Rasouli HR, Naghdi N. Enophthalmos and orbital volume changes in zygomaticomaxillary complex fractures: is there a correlation between them? *J Oral Maxillofac Surg.* 2019;77(1):134.
- Tahernia A, Erdmann D, Follmar K, Mukundan S, Grimes J, Marcus JR, et al. Clinical implications of orbital volume change in the management of isolated and zygomaticomaxillary complex-associated orbital floor injuries. *Plast Reconstr Surg.* 2009;123(3):968–75.
- Al-Qattan MM, Gelidan A. Fixation at the Inferior Orbital Rim in Medially Rotated Zygomatic Complex Fractures. *Plast Reconstr Surg Glob Open.* 2021;9(8):e3739.
- Lehtinen V, Salli M, Pyötsiä K, Toivari M, Snäll J. Primary reconstruction of combined orbital and zygomatic complex fractures with patient-specific milled titanium implants - A retrospective study. *J Craniomaxillofac Surg.* 2022;3. doi:10.1016/j.jcms.2022.09.006.
- Farber SJ, Nguyen DC, Skolnick GB, Woo AS, Patel KB. Current management of zygomaticomaxillary complex fractures: a multidisciplinary survey and literature review. *Craniomaxillofac Trauma Reconstr.* 2016;9(4):313–22.
- Chao MT, Losee JE. Complications in Pediatric Facial Fractures. *Craniomaxillofac Trauma Reconstr.* 2009;2(2):103–12.
- Boyette JR, Pemberton JD, Bonilla-Velez J. Management of orbital fractures: challenges and solutions. *Clin Ophthalmol.* 2015;9:2127–37.
- Das AK, Bandopadhyay M, Chattopadhyay A, Biswas S, Saha A, Balkrishna UM, et al. Clinical evaluation of neurosensory changes in the infraorbital nerve following surgical management of zygomaticomaxillary complex fractures. *J Clin Diagn Res.* 2015;9(12):54–8.
- Parameswaran A, Panneerselvam E, Ramanathan M, Kottackal MM, Mukherjee B. Classification and Management of Infra-orbital Rim Fractures. *J Oral Maxillofac Surg.* 2022;80(6):1053–61.
- Malik AH, Shah AA, Ahmad I, Shah BA. Ocular injuries in patients of zygomatico-complex (ZMC) fractures. *J Maxillofac Oral Surg.* 2017;16(2):243–7.
- Cortese A, D'Alessio G, Brongo S, Gargiulo M, Claudio PP. Management of zygomatic fractures in young patients: technical modifications for aesthetic and functional results. *J Craniofac Surg.* 2016;27(8):2073–77.
- Vergano LB, Landi S, Monesi M. Locked posterior fracture-dislocation of the shoulder. *Acta Biomed.* 2019;90(Suppl 12):139–46.
- Rohner D, Tay A, Meng CS, Huttmacher DW, Hammer B. The sphenozygomatic suture as a key site for osteosynthesis of the orbitozygomatic complex in panfacial fractures: a biomechanical study in human cadavers based on clinical practice. *Plast Reconstr Surg.* 2002;110(6):1463–71.

Author biography

Abhinandan Patel, Professor

Girish Gowda, Assistant Professor

Suhas Molahally Shetty, Fellow  <https://orcid.org/0000-0002-9439-2230>

Preethi Bhat, Consultant Maxillofacial Surgeon

Yoshita Gowda, Fellow

Cite this article: Patel A, Gowda G, Shetty SM, Bhat P, Gowda Y. Clinical and radiological assessment of open and closed reduction of inferior orbital rim fracture. *J Oral Med, Oral Surg, Oral Pathol, Oral Radiol* 2024;10(1):58-63.