



Content available at: <https://www.ipinnovative.com/open-access-journals>

Journal of Oral Medicine, Oral Surgery, Oral Pathology and Oral Radiology

Journal homepage: www.joooo.org



Case Series

Use of new piezoelectric inserts in the avulsion of complex impacted teeth

Rania Said Ibrahim Abdelazim Ibrahim^{1*}, Laura Porcheddu¹, Giona Peroni¹,
Giulia Rovelli¹, Luigi Tagliatesta¹, Jason Motta Jones¹

¹University of Milan, Oral Surgery Division, Santi Paolo & Carlo Hospital, Milan, Italy



ARTICLE INFO

Article history:

Received 14-02-2024

Accepted 27-02-2024

Available online 13-03-2024

Keywords:

Piezoelectric surgery

Third molar avulsion

ABSTRACT

This case series aims to present a new method for the avulsion of impacted third molars with a high risk of nerve damage.

This new technique uses piezoelectric surgery, particularly the new dedicated insert, in order to significantly reduce the risk of iatrogenic injury induced by levers and rotating instruments.

The study examines 17 dental elements with different degrees of impaction, classified according to Winter's Classification and Pell & Gregory's Classification. Therefore, the prediction of the intervention difficulty was evaluated using the Modified JD Classification (MJD). When performing surgical extractions of teeth located near the inferior alveolar nerve (IAN), there is a considerable risk of neurological complications, in all the cases presented, the patients had a normal postoperative course, without any septic or functional/neurological complications. In cases where continuity with noble structures represents a strong risk factor for neurological sequelae, this technology can greatly reduce the risk of iatrogenic injuries.

This is an Open Access (OA) journal, and articles are distributed under the terms of the [Creative Commons Attribution-NonCommercial-ShareAlike 4.0 License](https://creativecommons.org/licenses/by-nc-sa/4.0/), which allows others to remix, tweak, and build upon the work non-commercially, as long as appropriate credit is given and the new creations are licensed under the identical terms.

For reprints contact: reprint@ipinnovative.com

1. Introduction

The extraction of impacted third molars is the most common procedure in oral surgery. However, it is not without risks or technical difficulties, and, for this reason, it must always be preceded by careful planning.

Tooth avulsion can be a complex and investigative procedure depending on several factors such as root anatomy, relationship with the adjacent tooth, accessibility, and proximity to noble structures (e.g. vessels, nerves, cavities). It is also useful to evaluate the degree of patient collaboration, to guide the clinician in the selection of the type of anesthesia.

All these aspects must be evaluated by a careful preoperative clinical and radiographic examination to plan

correctly the procedure. gold standard approach in third molar extraction includes elevating a flap with a periosteal elevator to obtain tissue detachment and performing osteotomy and odontotomy using various instruments such as a manual, revolving, or piezoelectric insert when appropriate.

Close contact of the tooth with the inferior alveolar nerve (IAN) in the case of mandibular elements can cause trauma, often of minor severity, or a direct injury, causing transient neurological damage (paresthesia) or permanent damage (anesthesia, dysesthesia, or allodynia). To protect the integrity of the neurovascular structures while obtaining improved patient cooperation, the surgery should be approached in the least traumatic manner feasible. The use of piezoelectric technology aims to reduce complications and postoperative morbidity by exploiting the cutting capacity provided by the vibration of dedicated

* Corresponding author.

E-mail address: raniaibrahim8799@gmail.com (R. S. I. A. Ibrahim).

inserts.

This paper presents 19 cases of extractive surgery of third molars with varied degrees of complexity. It demonstrates how piezoelectric surgery, specifically a new specialized insert, can be used to reduce the risk of iatrogenic injury caused by the inappropriate use of levers and rotating instruments during the extraction of impacted third molars.

2. Materials and Methods

The avulsion of impacted third molars can be associated with intra- or postoperative complications, especially when they are located near noble anatomical structures such as the inferior alveolar nerve (NIA) or the maxillary sinus.

Therefore, the degree of complexity determined by three key factors must be taken into account when planning the surgical procedure: the shape and position of the element, intra-operative variables (the operator’s experience and surgical technique), and demographic variables (the patient’s age, gender, ethnicity, and body mass index).

Through 1st and 2nd level radiographic examinations (orthopantomography and CBCT, respectively) it is possible to evaluate:

1. The tooth level of impaction.
2. The morphology and number of roots.
3. The width of the follicular sac and of the periodontal ligament (its thickness decreases progressively with age).
4. The level of surrounding bone mineralization (the upper jaw has lower mineralization and density and greater elasticity than other bones).
5. The proximity of the impacted tooth to the adjacent teeth (the lack of a bone septum between the impacted tooth and the roots of the adjacent teeth represents a factor of greater difficulty since it makes it harder to dislocate the impacted tooth with a lever and increases the risk of damaging neighboring teeth) and the proximity of the inclusion to relevant anatomical structures (mandibular canal, maxillary sinus, nasal floor).

This study includes 17 patients: one patient with elements 1.8 and 2.8 included in the maxillary sinus, eight patients with element 3.8 impacted, six patients with element 4.8 impacted, one patient with partially impacted elements 3.8 and 4.8, and one patient with 3.8 not impacted (Table 1).

Table 1: Description of the elements considered in the study

Element	Number of elements	Number of elements included
1.8	1	1
2.8	1	1
3.8	10	8
4.8	7	6

The preoperative diagnosis was made based on clinical and radiographic examination as a first-level examination, an orthopantomography (OPT) was recommended for all patients. Its acquisition made it possible to evaluate the position of the impacted lower third molars using the following criteria:

1. The angle of the third molar in relation to the axis of the second molar (Winter’s classification), is classified as vertical, horizontal, mesioangular, and disto-angular.
2. Spatial relationships of the tooth with the ascending branch of the mandible and with the occlusal plane, and its relationship with the inferior alveolar nerve (Pell & Gregory’s classification). (Figure 1) (Table 2)

Table 2: Preoperative diagnosis of the position of the elements on the basis of the OPT according to the winter classification

Type of angulation	Number of elements
Vertical	5
Horizontal	2
Mesio-angular	3
Disto-angular	2

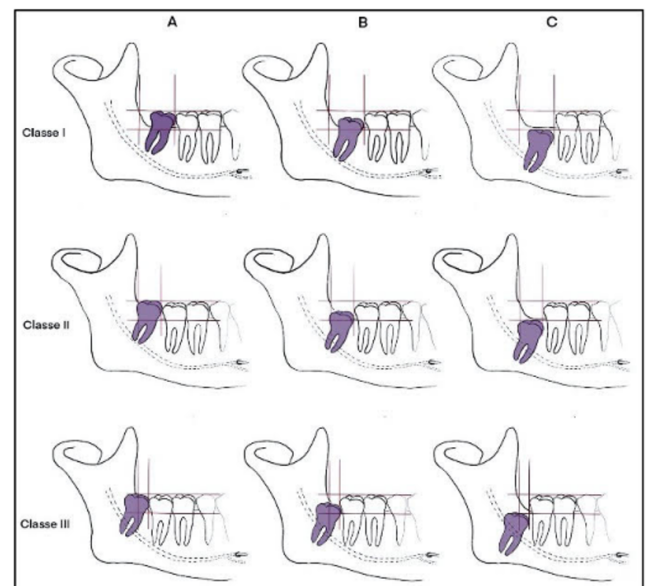


Figure 1: Pell & Gregory’s classification

Since first level radiographic image (OPT), is in two dimensions, a cone beam computed tomography (CBCT) was prescribed to 9 patients to investigate the spatial relationships between the impacted element and the inferior alveolar vascular-nervous bundle, or between the impacted tooth and the maxillary sinus.

The prediction of the difficulty of the intervention was evaluated through the Modified JD Classification (MJD) and

Table 3: Modified JD classification (MJD)

	M	R	A	C	B	S	Score
	Mesiodistal position in relation to the second molar.	Mesiodistal position in relation to the mandibular branch.	Apico-coronal position in relation to the alveolar crest.	Apico-coronal position in relation to the mandibular canal.	Buccolingual position in relation to the lingual and buccal walls of the mandible.	Spacial Position	
Pz. 4	1	1	2	2	1	1	8 - moderate
Pz. 5	0	3	3	0	3	2	11- moderate
Pz. 6	2	1	2	1	2	3	11 - moderate
Pz. 7	0	1	1	1	2	0	5- easy
Pz. 8	1	1	2	1	1	1	7 - moderate
Pz. 9	0	1	1	1	1	1	5 - easy
Pz. 10	0	1	1	2	2	0	6 - easy
Pz. 11	0	1	0	2	1	0	5 - easy
Pz. 12	2	1	2	1	0	3	9 - moderate

the scores given by the MJD indices are shown in the table. We remind you that the classification assigns a value from 0 to 3 (0 conventional, 1 simple, 2 moderate, 3 complicated) to six classes M, R, A, C, B, and S, according to the position of the tooth according to the FDI notation (Table 3).

After explaining the surgical procedure to the patients, it is agreed that the procedure would be performed in an outpatient setting with local anesthesia, except for one patient with whom it is agreed to perform under general anesthesia due to the proximity of the maxillary sinus to elements 1.8 and 2.8. Prior to the surgery, the patients were provided with detailed explanations regarding the clinical procedure, the expected post-operative effects, as well as potential complications that may occur during and after the surgery.

In 17 surgeries, a mucoperiosteal flap was created starting from the mesiobuccal surface of either the lower or upper second molar and ending with a relief incision in the distobuccal direction, allowing the identification of the third molar’s crown. For the last two cases, a semilunar flap (3.8) and a trapezoidal flap were prepared, each with two relief incisions, one in the distobuccal direction and one in the mesiobuccal direction (3.8). All the incisions were performed using a 15C Braun blade.

In 7 cases, the PR1 (Mectron®) was used to lift the flap, while in the remaining procedures, traditional dissectors or the periosteal elevator were employed.

This was followed by the removal of bone around the crown of the third molars (osteotomy), performed with a rotary instrument with a round bur in 16 operations and the remaining 3 with a piezoelectric insert FF lever (Mectron®). This step aimed to enhance the visibility of the dental structure and its anatomical relationships with the surrounding tissues. In all instances, the insert was operated at the "cortical" power setting, and the peristaltic water pump jet was adjusted to level 3 in four cases, level 5 in fourteen cases, and level 6 in one case. (Table 4)

Table 4: Water pump power

Water pump power	Number of cases
3	4
5	14
6	1

Odontotomy of the crown of 17 elements was performed (Figures 4, 5 and 6), 16 elements of which were completed with the odontotomy of the roots using the piezoelectric device with “OT12 S” insert (Mectron s.p.a., Carasco, Ge – Italy). At this point the “FF lever, Mectron®” (Mectron s.p.a., Carasco, Ge – Italy) was used to dislocate root fragments and remove them safely, ensuring the integrity and minimal trauma to the inferior alveolar nerve passing through the tooth roots. (Tables 5, 6 and 7)

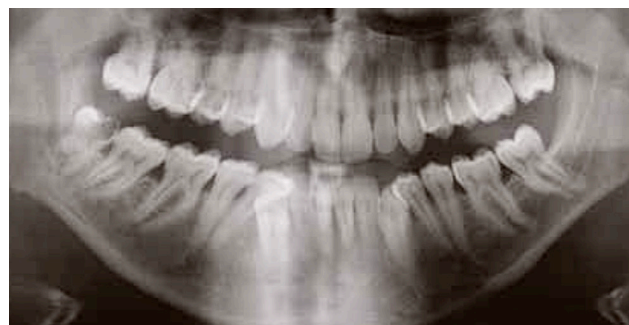

Figure 2: Orthopantomography showing severe decay on tooth 48 and overlap of the neurovascular bundle with root block

The time (t) of luxation and avulsion of the teeth was calculated by timing the procedure from the time the flap incision was made until the tooth was completely removed. (Tables 5 and 6)

After the extraction, the socket was examined to ensure the absence of lesions as well as the integrity of the adjacent

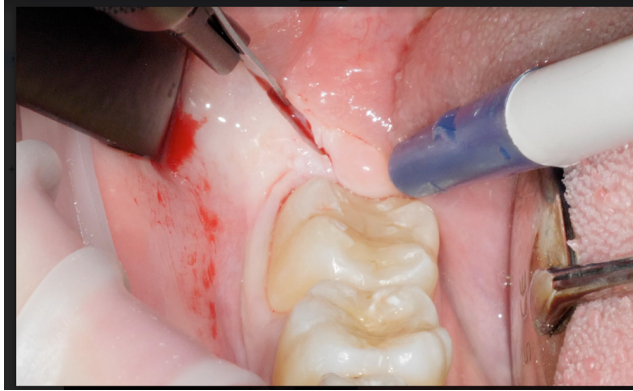


Figure 3: Intraoral clinical view of partially impacted tooth 48

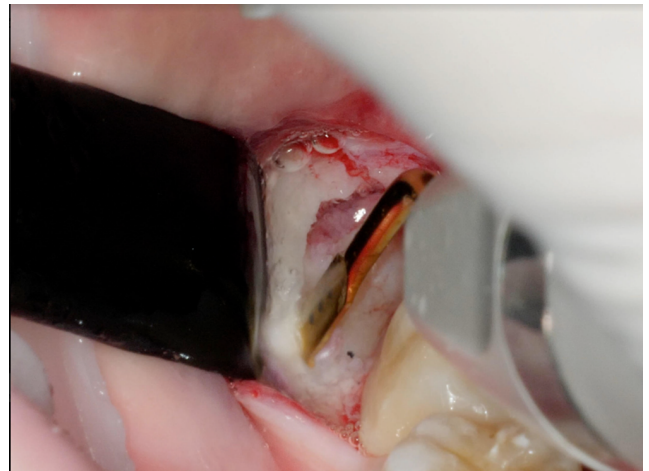


Figure 6: Use of first piezo insert

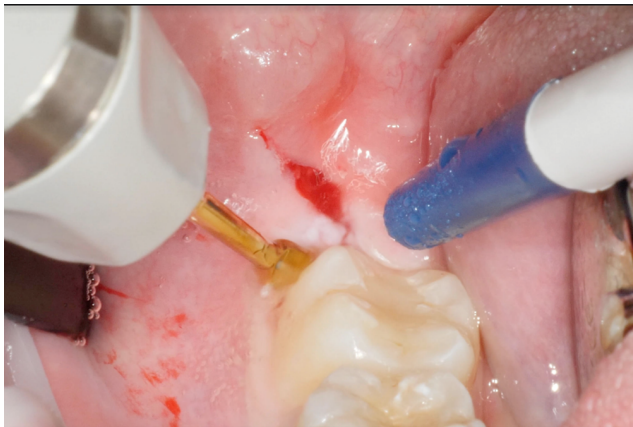

Figure 4: Detachment of mucoperiosteal tissue with dedicated piezoelectric insert

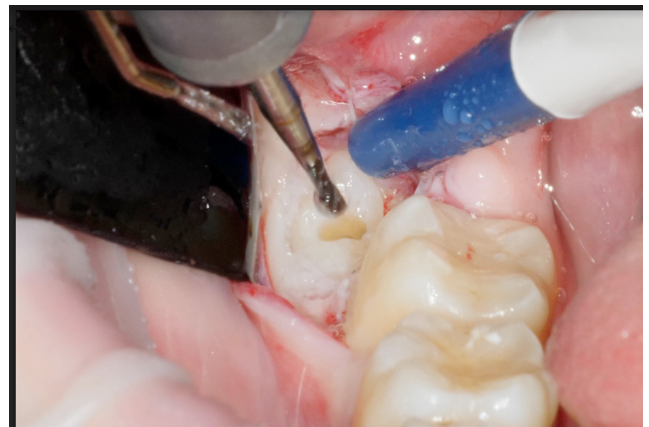


Figure 7: Odontotomy using a slit bur on a straight handpiece

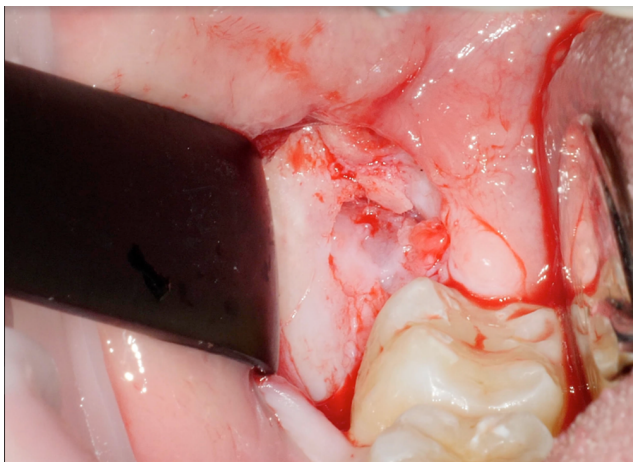


Figure 5: Bone exposure following flap detachment

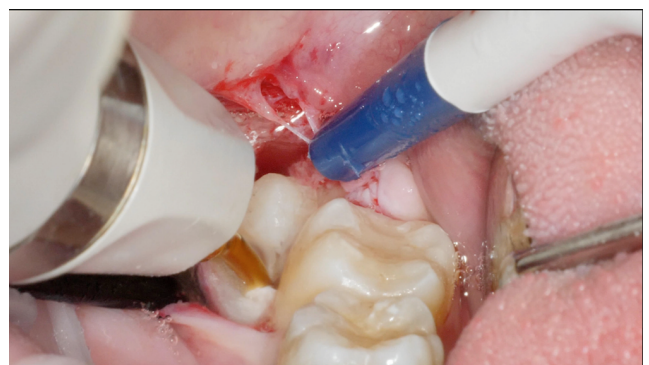

Figure 8: Use of dedicated piezoelectric insert for distal luxation of the root block

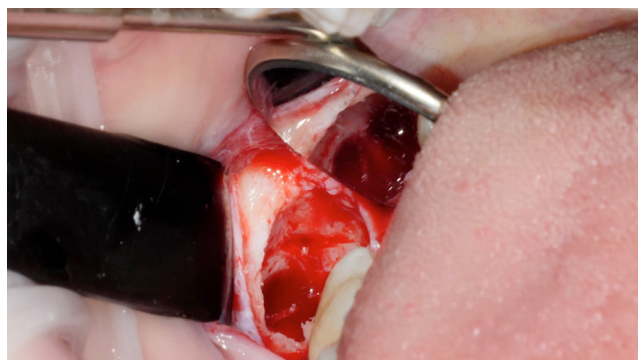


Figure 9: Direct and indirect view of empty

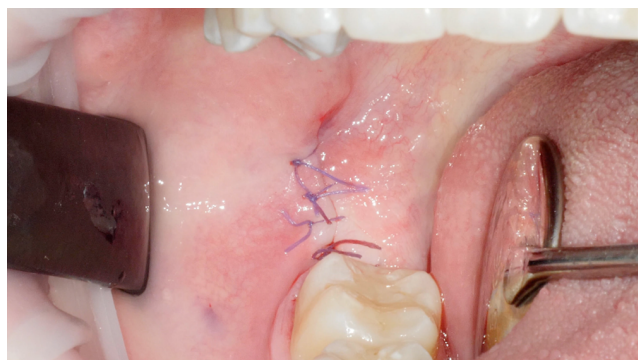

Figure 10: Final view after suturing

Table 5: Dislocation times of the various elements with the piezoelectric insert

Time (t)	Number of cases	Elements involved
t < 5 min	1	3.8
5 min < t < 10 min	10	3.8 - 4.8
10 min < t < 15 min	5	3.8 - 4.8 - 1.8
15 min < t < 20 min	2	2.8 - 3.8
20 min < t < 25 min	1	3.8

Table 6: Statistics related to dislocation times

Statistics	Value (minutes)
Media	10.84
Median	9
Standard deviation	4,93

Table 7: Surgical approach during third molar avulsion

Surgical approach	Number of cases	
Crown	No section	3
	Total section	14
	Multiple sections	2
	Fragmentation	0
Roots	No sections	16
	Section	0
	Fragmentation	3

structures. Resorbable Vicryl® 5/0 monofilament sutures (Ethicon Coated Vicryl Suture 5/0, USA) were then applied. At the end of the surgical procedure, patients continued their antibiotic therapy begun the day before until the standard dosage was completed. They were given oral antibiotics (Amoxicillin + Clavulanic Acid 875+125 mg, once every 12 hours for 6 days), and pain relievers as needed.

Finally, patients were scheduled for a follow-up appointment in 7 days to evaluate the healing process. In particular, for the lower arch elements, clinical evaluations were conducted to ensure proper nerve functionality and to detect any changes in sensitivity that could be attributed to nerve damage.

These evaluations included:

1. Gentle pressure test, conducted by placing a small cotton ball on the skin of the chin and, the anterior and middle third of the mandibular body.
2. Rubbing test, which involved rubbing the cotton ball in the same areas while asking the patient to describe the perceived sensation.
3. Two-point discrimination test, performed with two thin needles placed at a predetermined distance on the examined area and gradually moving them apart while asking the patient to indicate when they could no longer discriminate between the two points. A discriminated distance of 5 mm was considered an acceptable sensory response.
4. Nociception was assessed by applying a needle to the chin’s skin: nociceptive sensitivity was considered good if the patient responded adequately to increasing stimulation intensity.
5. Cold sensitivity test was conducted using a cooled cotton ball to see if the patient’s thermal sensitivity was preserved.

The same procedures were then repeated on the left side as a control.

3. Results

When performing surgical extractions of teeth located near the inferior alveolar nerve (IAN), there is a considerable risk of neurological complications, which can be as high as 45-69% with traditional surgical approaches.^{1,2} However, based on the nineteen interventions performed, it is evident that the use of piezoelectric surgery with the new dedicated insert allows minimize the trauma of the intervention and the related risks. Among the examined group, only 3 cases experienced root fracture of the element, which was fixed using the ff lever insert, allowing the removal of residual fragments without any postoperative sequelae. (3.8-3.8-4.8) In all cases, the patients had a normal postoperative course, without any septic or functional/neurological complications.

4. Discussion

The avulsion of third molars in bone inclusion can be associated with intra- or postoperative complications, especially when such elements are located in proximity to noble anatomical structures such as the inferior alveolar nerve (IAN) or the maxillary sinus. Therefore, the surgical intervention's design must consider the degree of complexity dictated by three main factors: the shape and position of the element, intra-operative variables (operator experience and surgical technique), and demographic variables (age, gender, ethnicity, and patient's body mass index).³⁻⁵

Through I and II-level radiographic examinations (orthopantomography and CBCT, respectively), it is possible to evaluate:

1. The degree of inclusion of the dental element.
2. The morphology and number of roots.
3. The amplitude of the follicular sac and periodontal ligament (its thickness decreases progressively with age).
4. The degree of mineralization of the surrounding bone tissue (the bone tissue of the jaws has less mineralization and density and greater elasticity than other bones, especially the upper jaw's tissue).
5. The proximity of the included tooth to adjacent teeth (the absence of an osseous septum between the included tooth and the roots of nearby teeth represents a factor of greater difficulty since it makes the dislocation of the included tooth with a lever more difficult and increases the possibility of damaging nearby teeth during maneuvers) and the proximity of the included tooth to significant anatomical structures (mandibular canal, maxillary sinus, nasal floor).^{3,6}

The use of the new insert and the piezoelectric manipulator makes it possible to eliminate the iatrogenic risk linked to the avulsive component of the dental element, usually executed through manual levers, thus reducing the risk of iatrogenic injury caused by the greater pressure, operator-dependent, exerted through the use of levers. Also, the risk of cortical perforation or tissue laceration that could be caused by the cutting surface of the lever if it escapes from the operator's grip is reduced. Finally, the risk of inadvertently damaging the adjacent tooth is reduced.

Winter and Pell & Gregory classifications regarding the radiographic position of the tooth in relation to the ascending branch of the mandible and the occlusal plane of the lower second molar are still the most widely used method to describe the degree of impaction and thus the difficulty of the intervention. Several attempts have been made to propose classifications that encompass a higher number of variables to obtain a universal criterion for defining the difficulty of the intervention. Stacchi et al. in 2018, for example, proposed a classification, analyzing

those present in the literature up to that point, which assumes the evaluation of the duration of the intervention as the primary indicator of the degree of difficulty.⁴ The second fundamental parameter is represented by the risk dictated by the proximity of the roots of the tooth to the inferior alveolar nerve bundle and the lingual nerve (LN). In particular, recent studies have shown how the most significant aspect in the possibility of occurrence of postoperative neurological lesions is the presence - or absence - of contact between the root apices of the lower third molar and the IAN, and thus the presence or absence of bone cortical around the mandibular canal.⁷

Traditional surgical approaches (rotating instruments combined with drills) are routinely applied even to impacted teeth that lie in proximity or contiguity to the inferior alveolar nerve. However, in cases where impacted teeth are in direct relationship or continuity with nervous structures, the use of other surgical techniques appears to be much more appropriate. Coronectomy represents an alternative to complete tooth avulsion. This surgical technique involves only the removal of the crown of the eighth, leaving the radicular block in contact with the IAN inside the alveolus. While ensuring the integrity of the nerve trunk, this technique is not without risks and possible peri- and post-operative complications, including pain, infections, or alveolitis, requiring in a good percentage of cases (5.28-11.26%) a second intervention to remove the radicular portion.⁸

Piezoelectric surgery has some advantages over traditional surgery. This technology exploits the micro-vibrations of particular ultrasonic surgical inserts in such a way as not to damage the soft tissues even in case of accidental contact with the surgical insert itself. From this, it follows:

1. The possibility of obtaining a selective, precise, and safe cut of hard tissues, operating in high anatomical risk fields (mucous membranes, membranes, blood vessels, and nerves), as a consequence of the modulated ultrasonic low frequency.
2. A micrometric cut: the effort required to make a cut in piezo-surgery is very light (compared to the use of slot drills or bone saws) with high operator control of the instrument, high precision guaranteed by the micro-vibrations of the insert, greater intraoperative safety while limiting tissue damage.
3. A bloodless site as a consequence of the cavitation effect: thanks to the presence of the physiological solution necessary for cooling the tips, which flows laminarly along the insert, a physical phenomenon is generated characterized by the formation of very low pressure vapor bubbles which, imploding, give rise to a mechanical cleaning action, making the operative field bloodless and at the same time lowering the septic risk of the intervention.

4. A shorter duration of the intervention: the results of the randomized controlled study by Jiang et al.⁹

According to a systematic review with the meta-analysis by Al-Moraissi in 2016, the piezoelectric surgical technique applied in third molar extractions shows a significant reduction in post-operative sequelae (edema, pain, trismus). In accordance with numerous studies, the low incidence of postoperative sequelae would be attributed to the atraumatic and micrometric cutting action of the instrument.⁹

Possible disadvantages of this technology can include the learning curve required for using the piezoelectric equipment and insert, the limited data available in the literature regarding it, and initial costs. The risk of losing sensitivity in an inferior alveolar nerve, even permanently, is the main concern of a patient undergoing surgical removal of an impacted or semi-impacted lower third molar in close contact with nerve structures.¹⁰ In fact, informed consent forms submitted to patients usually explain that accidental injuries, strains, or compressions of the IAN can result in alterations in sensitivity of the skin on the face corresponding to the ipsilateral half of the mandible and chin, with symptoms ranging from paresthesia (tingling), which tends to regress until disappearance, to anesthesia for complete nerve injuries. Chiapasco et al.¹⁰ reported an incidence of nerve injuries affecting the inferior alveolar nerve ranging from 0.2% to 1.4%, while the involvement of the lingual nerve in neurological sequelae occurs between 0.2% and 0.8%.¹¹

Regarding neurological complications following third molar extractions, the literature reports a majority of transient paresthesias with spontaneous healing and resolution (0.4-6%), while permanent damage lasting longer than six months after the intervention is found in a case series of less than 1%.¹¹ Even in the most severe cases, partial resolution of symptoms has been observed within a period ranging from 3 to 9 months, albeit with difficulties for patients to distinguish symptom resolution from adaptation or "habituation" to this new condition.¹²

About the extraction kit used, the company recommends applying a force of about 2 kg, significantly lower than that normally applied with a common manual lever. The force direction must be parallel to the axis of the impacted tooth and applied intermittently (4 sec ON and 2 sec OFF) to avoid iatrogenic overheating of the mineralized surfaces along which the vibrations propagate in the apical direction.

To achieve predictable results and minimize the risk of significant nerve injuries, in addition to precise preoperative diagnosis and careful surgical planning with first- and second-level radiographic exams, piezoelectric surgery represents a valid alternative that greatly reduces the risk of post-intervention neurosensory sequelae.

5. Conclusion

Considering the limitations of this study, the combination of the proposed new insert with the already established

effectiveness of piezoelectric surgery, together with the surgeon's experience, represents a valid alternative for atraumatic extraction of third molars.

In cases where continuity with noble structures represents a strong risk factor for neurological sequelae, this technology can greatly reduce the risk of iatrogenic injuries.

Furthermore, avoiding the use of lever forces further lowers the possibility of trauma and can contribute to increasing patient compliance.

6. Conflict of Interest

The authors declare that they have no conflict of interest.

7. Financing for Study

The authors declare that they have not received any funding for this study.

8. Informed Consent

The authors declare that the patient's informed consent was obtained for the publication of the case, including photos.

9. Declaration of Generative AI and AI- Assisted Technologies in the Writing Process

The authors declare that they have not use generative AI and AI-assisted technologies in the writing process.

References

1. Robert RC, Bacchetti P, Pogrel MA. Frequency of trigeminal nerve injuries following third molar removal. *J Oral Maxillofac Surg.* 2005;63(6):732–5.
2. Klazen Y, Cruyssen FVD, Vranckx M, Vlierberghé MV, Politis C, Renton T, et al. Iatrogenic trigeminal post-traumatic neuropathy: a retrospective two-year cohort study. *Int J Oral Maxillofac Surg.* 2018;47(6):789–93.
3. Akadiri OA, Obiechina AE. Assessment of difficulty in third molar surgery—a systematic review. *J Oral Maxillofac Surg.* 2009;67(4):771–4.
4. Stacchi C, Daugela P, Berton F, Lombardi T, Andriulionis T, Perinetti G, et al. A classification for assessing surgical difficulty in the extraction of mandibular impacted third molars: Description and clinical validation. *Quintessence Int.* 2018;49(9):745–53.
5. Jun SH, Kim CH, Ahn JS, Padwa BL, Kwon JJ. Anatomical differences in lower third molars visualized by 2D and 3D X-ray imaging: clinical outcomes after extraction. *Int J Oral Maxillofac Surg.* 2013;42(4):489–96.
6. Leung YY, Cheung LK. Risk factors of neurosensory deficits in lower third molar surgery: an literature review of prospective studies. *Int J Oral Maxillofac Surg.* 2010;40(1):1–10.
7. Cervera-Espert J, Pérez-Martínez S, Cervera-Ballester J, Peñarocha-Oltra D, Peñarocha-Diago M. Coronectomy of impacted mandibular third molars: A meta-analysis and systematic review of the literature. *Med Oral Patol Oral Cir Bucal.* 2016;21(4):e505–13.
8. Póvoa R, Mourão C, Geremias TC, Sacco R, Guimarães LS, Montemezzi P, et al. Does the Coronectomy a Feasible and Safe Procedure to Avoid the Inferior Alveolar Nerve Injury during Third Molars Extractions? A Systematic Review. *Healthcare (Basel).* 2021;9(6):750–50.

9. Al-Moraissi EA, Elmansi YA, Al-Sharaee YA, Alrmali AE, Alkhutari AS, Jiang Q, et al. Does the piezoelectric surgical technique produce fewer postoperative sequelae after lower third molar surgery than conventional rotary instruments? A systematic review and meta analysis. *Int J Oral Maxillofac Surg*. 2016;45(3):383–91.
10. Chiapasco M, Crescentini M, Romanoni G. Germectomy or delayed removal of mandibular impacted third molars: the relationship between age and incidence of complications. *J Oral Maxillofac Surg*. 1995;53(4):418–22.
11. Lhano NCD, Ribeiro RA, Martins CC, Assis CC, Assis N, Devito KL. Panoramic versus CBCT used to reduce inferior alveolar nerve paresthesia after third molar extractions: a systematic review and meta-analysis. *Dentomaxillofac Radiol*. 2020;49(4):20190265. doi:10.1259/dmfr.20190265.
12. Hillerup S. Iatrogenic injury to the inferior alveolar nerve: etiology, signs and symptoms, and observations on recovery. *Int J Oral Maxillofac Surg*. 2008;37(8):704–9.

Laura Porcheddu, Student

Giona Peroni, Student


Giulia Rovelli, Student

Luigi Tagliatesta, DDS Oral Surgeon

Jason Motta Jones, DDS Oral Surgeon

Cite this article: Ibrahim RSIA, Porcheddu L, Peroni G, Rovelli G, Tagliatesta L, Jones JM. Use of new piezoelectric inserts in the avulsion of complex impacted teeth. *J Oral Med, Oral Surg, Oral Pathol, Oral Radiol* 2024;10(1):64-71.

Author biography

Rania Said Ibrahim Abdelazim Ibrahim, Student
 <https://orcid.org/0009-0006-6403-3401>