



Content available at: <https://www.ipinnovative.com/open-access-journals>

Journal of Oral Medicine, Oral Surgery, Oral Pathology and Oral Radiology

Journal homepage: [www.joooo.org](http://www.joooo.org)



## Case Report

# Dental extrusion in children: Case report

Soukeye Ndoye<sup>1\*</sup>, Malick Faye<sup>1</sup>, Mamadou Tidiane Diallo<sup>1</sup>, Ndeye Guiniane Diouf<sup>1</sup>, Abdoulaye Diouf<sup>1</sup>

<sup>1</sup>Dept. of Pediatric Odontology, Institute of Odontology and Stomatology; University of Cheikh Anta, Diop Dakar, Senegal



### ARTICLE INFO

#### Article history:

Received 05-01-2024

Accepted 21-02-2024

Available online 13-03-2024

#### Keywords:

Tooth

Extrusion

Repositioning

Retention

Child

### ABSTRACT

**Background:** The orofacial sphere is an area frequently affected by trauma. Their severity is much greater in children and adolescents, due to the immaturity of the dental and bone structures and the instability of the dental arches.

**Case Report:** A 9-year-old child, victim of a road traffic accident, was referred to the emergency department of the Albert Royer Children's Hospital, for dental trauma. In the consultation around 15 hours after the trauma, the clinical and radiographic assessment revealed extrusion of the right upper central incisor with gingival tearing, lateral luxation of the upper lateral incisors and the left upper central incisor, and laceration of the inner surface of the right upper lip associated with edema. Reimplantation of the extruded tooth was performed. Flexible canine-to-canine splint was applied for 3 weeks. A non-steroidal anti-inflammatory prescription was made to complement the one already made in the emergency consultation. Clinical and radiographic follow-ups at 1 week, 15 days, 1 month, 3 months, 6 months, and 1 year were carried out.

**Conclusion:** Despite their high frequency, especially in children, dental trauma should be the subject of an emergency consultation. Even if the prognosis is reserved, appropriate therapy should be undertaken if the conditions are right, while respecting the guidelines of learned societies for the child's well-being and quality of life.

This is an Open Access (OA) journal, and articles are distributed under the terms of the [Creative Commons Attribution-NonCommercial-ShareAlike 4.0 License](https://creativecommons.org/licenses/by-nc-sa/4.0/), which allows others to remix, tweak, and build upon the work non-commercially, as long as appropriate credit is given and the new creations are licensed under the identical terms.

For reprints contact: [reprint@ipinnovative.com](mailto:reprint@ipinnovative.com)

## 1. Introduction

Traumatic dental injuries are the fifth most common health problem worldwide, can affect the quality of life, and are associated with high treatment costs for individuals and society.<sup>1</sup> They are frequent and concern 25% of school children and 33% of adults.<sup>2</sup> The prevalence varies between 2 and 58%.<sup>3</sup> According to the International Association of Dental Traumatology (IADT), one in three children experiences trauma between the ages of 8 and 12. During this period of life, fractures and dental displacements (lateral dislocations, extrusion, intrusion, expulsion) are the most

frequent, and the incisors, especially the upper incisors, are the most affected.<sup>4</sup>

Alveolo-dental trauma constitutes real dental emergencies because of the aesthetic, functional, and psychological repercussions that can alter well-being and quality of life.<sup>5</sup>

Their management is a real challenge for the practitioner because it occurs at a time when the child is in full growth and development.

A careful clinical and radiographic assessment is essential to determine the type of trauma and guide the therapeutic choice which will be oriented towards the favorable evolution of the dental and alveolar structures and the harmony of the growth of the jaws. Management must

\* Corresponding author.

E-mail address: [soukeye.ndoye@ucad.edu.sn](mailto:soukeye.ndoye@ucad.edu.sn) (S. Ndoye).

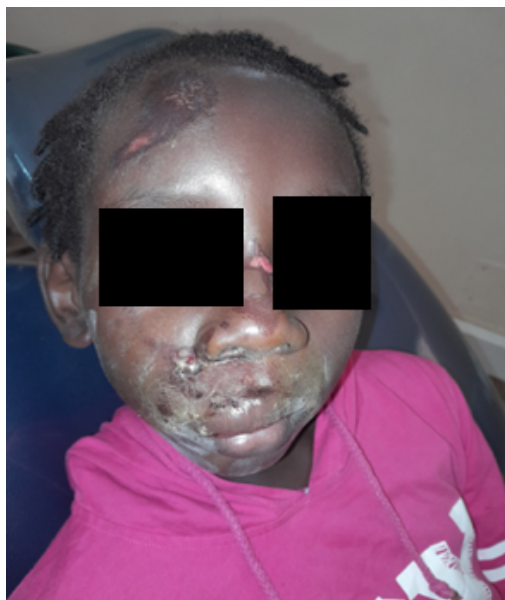take into account the type of trauma, the tooth concerned, the patient, the technical platform, and the expertise of the practitioner.

Dental extrusion or extrusive luxation is a trauma to the supporting tissues characterized by partial displacement of the tooth in its socket in an axial direction and results, most often, from a violent and oblique impact. Clinically, the tooth appears longer than the contralateral ones, with a crown tilted to the palatal side and excessive mobility. The periodontal ligament is affected but not exposed to the disrupt of the alveolar vascularization. Despite great variability in studies, extrusion is always found in first or second position in extrusive luxation.<sup>6,7</sup> This work reports the treatment of a child with severe extrusion of an immature permanent incisor.

## 2. Clinical Case Presentation

It was a 9-year-old girl, victim of road traffic accident and taken by firefighters to the Assistance and Emergency Department of the Albert Royer Children's Hospital. After general emergency treatment, the patient was referred for a consultation at the dentistry department for specific oral care.

The oral history reveals pain accentuated by eating, phonation, contact of the lower lip, and tooth-to-dental contact. The extra-oral examination reveals facial asymmetry with swelling of the right upper lip, and a laceration on the face on the right side (nose, eye contour, forehead) (Figure 1).

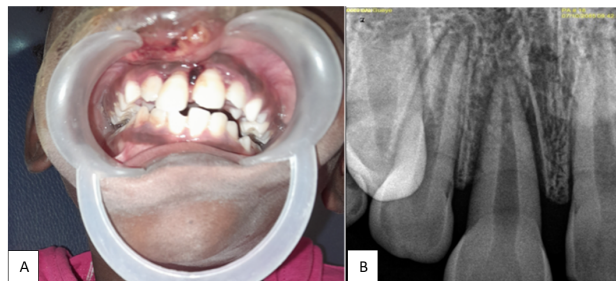


**Figure 1:** Front view which highlights the labial swelling and skin wounds

Palpation of the bony rim (mandibular condyle) presents normal symptoms. The amplitude and opening path are

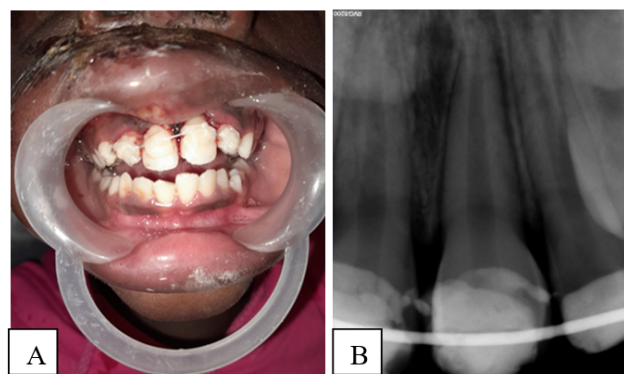
normal.

Intraoral examination shows that the patient was in mixed dentition with an overhang and an overlap greater than 3mm, an open wound on the inner surface of the right upper lip, ulceration of the gum between the maxillary central incisors, the right maxillary central incisor (11) appears “longer” compared to the adjacent teeth and with significant mobility. Right maxillary lateral incisor and left maxillary central incisor (tooth n°21) present a type 2 mobility, and no. 22. Tooth No. 41 presents a simple coronal fracture.



**Figure 2:** A): Highlights labial ulceration and extrusion of the 11; B): The retroalveolar radiograph which highlights a thickening of the periodontal space of the 11, which confirms the dislocation

At this stage, the diagnoses of extrusion, a root fracture, and a dental alveolar fracture of 11 are assumed. A radiographic examination carried out using a retro-alveolar image revealed the emptiness of part of the socket of 11, a displacement of 11, and an increased ligament space (Figure 3).



**Figure 3:** This image highlights repositioning and splinting with a wire secured with composite

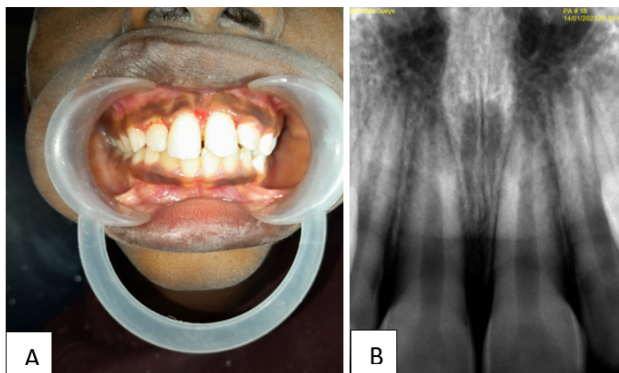
The results of the clinical examination and radiographic assessment made it possible to make the diagnosis of severe extrusion of 11 associated with subluxation of 12, 21, and 22.

### 2.1. Therapeutic care

Faced with such a clinical situation, we opted for was the repositioning of tooth n°11 associated with splinting, composite restoration of tooth n°41 and a follow-up schedule.

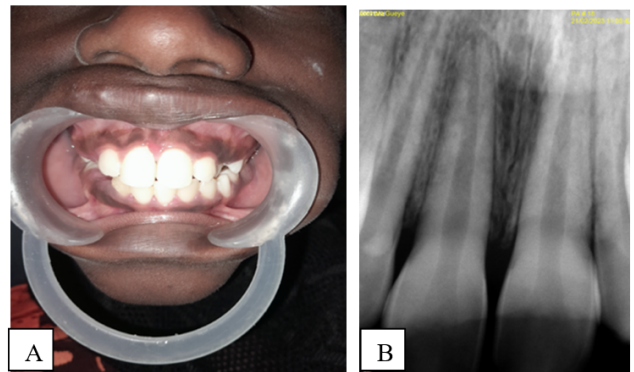
Referring to the International Association of Dental Traumatology (IADT) recommendations, the following protocol was adopted:

1. Local anesthesia without vasoconstrictor (Lidocaine 2%),
2. Manual repositioning with gentle pressure,
3. Flexible retention from canine to canine by placing the extruded tooth last (Figure 4),
4. X-ray to check the correct positioning of the traumatized tooth,
5. Prescription of non-steroidal anti-inflammatory drugs to alleviate upper lip edema.
6. Oral and food hygiene tips
7. Initial medical certificate

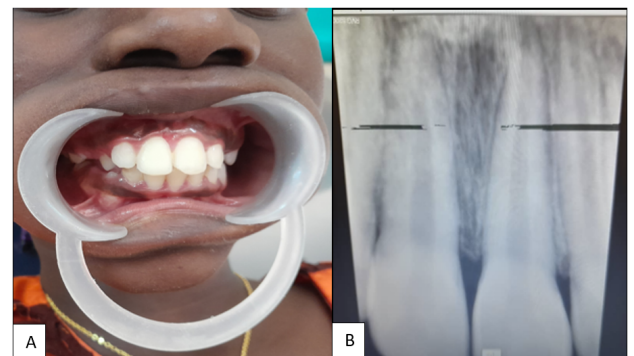


**Figure 4:** Control at 1 month. Healing of the gums and lip. The deep periodontium shows a normal radiographic appearance

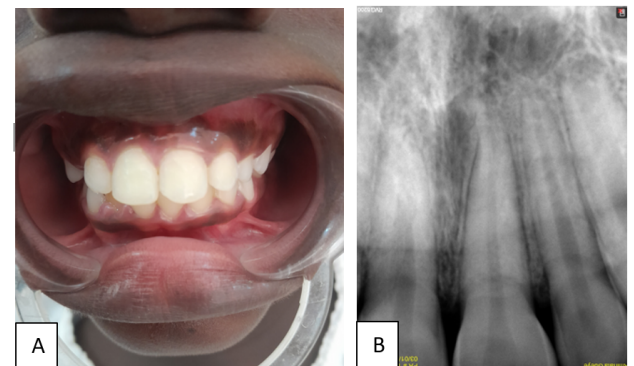
A clinical and radiographic check was carried out at 15 days, 1 month, 3 months, and 6 months (Figures 5, 6 and 7). At 15 days, the pulp sensitivity test was positive, the percussion was a little painful, the x-ray showed improvement in the periodontal ligament, and the retainer was removed. Clinical and radiographic checks at 1 month, then 3 months, and 6 months revealed periodontal and apical healing. A positive pulp sensitivity test result, a negative axial percussion test, and normal mobility were noted. Clinical control at 1 year reveals a normal color (absence of dyschromia), an absence of clinical symptoms, and a positive pulp sensitivity test. On radiographic control, the deep periodontium reveals a normal appearance, without root or bone resorption, without apical or periapical osteolytic image. The periodontal space was visible, which confirms the absence of ankylosis.



**Figure 5:** Control at 3 months



**Figure 6:** Control at 6 months



**Figure 7:** Control at 1 year: the deep periodontium reveals a normal appearance, without root or bone resorption, without apical or periapical osteolytic image

### 3. Discussion

Alveolo-dental trauma must be the subject of an emergency consultation, especially in the young patient due to the negative impacts that it can cause in the short, medium, and long term. Indeed, earlier the consultation, the more favorable the prognosis. In this present clinical case, despite the severity of the trauma and the time elapsed between the trauma and the consultation (12 hours), the appropriate

treatment was undertaken while keeping in mind that according to the IADT guidelines, to have a favorable prognosis in case of extrusion, the consultation time must be less than 3 hours.<sup>8</sup> However, the characteristics of the tooth in extrusion (stage 9 in the classification of Nolla), compliance with the operating protocol, the mother's motivation, the child's cooperation, and his general state of health are all parameters that motivated the repositioning to keep the tooth in the arch. Also, the immature permanent tooth is rich in young cells and has a strong potential for differentiation, defense, and repair, making the prognosis of pulp survival possible.<sup>8</sup>

The degree of displacement is an important factor in prognosis. Indeed, according to Humphreys et al.,<sup>8</sup> a displacement greater than 3 mm was associated with a risk of pulpal complications contradictory results were found by Andreasen et al.<sup>9</sup> and Lee et al.,<sup>10</sup> which comforts us in this present clinical case.

The follow-up was carried out respecting the deadlines as suggested by the recommendations with radiography and clinical tests at each follow-up. For this case, the results of the clinical and radiographic assessment showed a favorable evolution in terms of periodontal healing, maintenance of pulp sensitivity, and absence of clinical symptoms and periapical lesions. Indeed, it is recommended not to rush to devitalize a traumatized tooth that does not respond to sensitivity tests immediately or in the days following the shock because the pulpal shock can be long and the test can become positive only 2 or even 3 months later. Furthermore, if it is an immature tooth, the existence of stem cells in the periapical region which survive even in the event of necrosis can allow revascularization with continued root construction and/or apical closure.<sup>9,10</sup>

The follow-up schedule will be respected with a follow-up every year for up to 5 years because complications such as necrosis or pulp obliteration, inflammatory resorption, and even ankylosis can occur and require either endodontic treatment or an apexification or revascularization treatment depending on the stage of root construction. According to Bourguignon et al., the risk of pulp obliteration is very common in immature teeth having undergone extrusion, intrusion, or lateral dislocation.<sup>2</sup>

#### 4. Conclusion

This case report highlights the importance of always attempting repositioning in the event of extrusion if the conditions are met even if the subsequent risk of complications is high. This therapeutic attitude will restore aesthetics and function which are important aspects of well-being and quality of life, especially in young patients.

#### 5. Source of Funding

None.

#### 6. Conflict of Interest

None.

#### References

- Abbott P. Traumatic dental injuries are now the 5th most prevalent disease/injury in the world-But they are being neglected!! *Dent Traumatol.* 2018;34(6):383.
- Bourguignon C, Cohenca N, Lauridsen E, Flores M, O'Connell AC, Day PF, et al. International Association of Dental Traumatology guidelines for the management of traumatic dental injuries: 1. Fractures and dislocations. *Dent Traumatol.* 2020;36(4):314–30.
- Goettens ML, Torriani DD, Hallal PC, Correa MB, Demarco FF. Dental trauma: prevalence and risk factors in schoolchildren. *Community Dent Oral Epidemiol.* 2014;42(6):581–90.
- Andreasen JO, Andreasen FM. Frontmatter. In: Essentials of Traumatic Injuries to the Teeth. United States: John Wiley & Sons; 2000.
- Dave M. EBD spotlight: The impact of dental trauma on the oral health-related quality of life of children and adolescents. *BDJ Team.* 2023;10:46–7.
- Azami-Aghdash S, Azar FE, Azar FP, Rezapour A. Prevalence, etiology, and types of dental trauma in children and adolescents: systematic review and meta-analysis. *Med J Islam Repub Iran.* 2015;29(4):234.
- Diangelis AJ, Andreasen JO, Ebeleseder KA, Kenny DJ, Trope M, Sigurdsson A, et al. International Association of Dental Traumatology guidelines for the management of traumatic dental injuries: 1. Fractures and dislocations of permanent teeth. *Dent Traumatol.* 2012;28(1):2–12.
- Humphreys K, Badri A, Kinirons S, Welbury M, Cole RR, Bryan BO, et al. Factors affecting outcomes of traumatically extruded permanent teeth in children. *Pediatr Dent.* 2003;25(5):475–8.
- Andreasen FM, Pedersen BV. Prognosis of dislocated permanent teeth –the development of pulp necrosis. *Endod Dent Traumatol.* 1985;1(6):207–20.
- Lee R, Barrett EJ, Kenny DJ. Clinical outcomes for permanent incisor luxations in a pediatric population. II. Extrusions. *Dent Traumatol.* 2003;19(5):274–9.

#### Author biography

**Soukeye Ndoye**, Researcher

**Malick Faye**, Researcher

**Mamadou Tidiane Diallo**, Researcher

**Ndeye Guiniane Diouf**, Researcher

**Abdoulaye Diouf**, Researcher

**Cite this article:** Ndoye S, Faye M, Diallo MT, Diouf NG, Diouf A. Dental extrusion in children: Case report. *J Oral Med, Oral Surg, Oral Pathol, Oral Radiol* 2024;10(1):75-78.