



Content available at: <https://www.ipinnovative.com/open-access-journals>

Journal of Oral Medicine, Oral Surgery, Oral Pathology and Oral Radiology

Journal homepage: www.joooo.org



Case Series

Mucoepidermoid carcinoma: A comparative analysis of histological grading systems

Vaishali Anil Nandkhedkar^{b1}, Mandakini Mandale^{b1*}, Jayanti Humbe^{b1}, Savita Prashant Wagh^{b1}, Shubhankar Anil Nandkhedkar^{b2}

¹Dept. of Oral Pathology and Microbiology, Government Dental College and Hospital, Aurangabad, Maharashtra, India
²CSMSS Dental College, Aurangabad, Maharashtra, India



ARTICLE INFO

Article history:

Received 07-05-2024

Accepted 30-05-2024

Available online 17-06-2024

Keywords:

Histological grading systems

Mucoepidermoid carcinoma

Salivary gland tumour

ABSTRACT

Background: Salivary gland carcinomas comprise of only 3-5% of all head and neck malignancies. Mucoepidermoid carcinoma (MEC) is the most common malignant salivary gland tumor. The morphologic diversity of MEC can pose diagnostic challenges hence, various histological grading systems have been proposed based on the quantitative and qualitative analysis. This proves to be greatly consequential in the management and prognosis of patients with MEC.

Objective: To compare histologic grading methods in MEC of major & minor salivary glands.

Materials and Methods: 20 histopathologically diagnosed cases of MEC (10 each major & minor salivary gland) will be analysed using following methods: Qualitative Method: 1) Modified Healey 2) Memorial Sloan-Kettering Cancer Center method. Quantitative method: 1) Armed force Institute of Pathology (AFIP) 2) Brandwein method Histological findings were evaluated.

Result: In our study AFIP grading system, 50% Cases were classified as low grade, 35% as intermediate grade and 15% as high graded. According to Brandwein grading system, 20% of cases were categorized as low, 35% cases as intermediate, 45% cases as high grade MEC. Modified Healey grading system of MEC showed 50%, 40%, 10% cases as low, intermediate and high grade MEC respectively. MSKCC grading system revealed as 55%, 30% and 15% cases as low, intermediate and high grade MEC respectively. Our finding indicated that MSKCC grading system was the most favourable histological grading system as percentage of agreement found to be 85%.

Conclusion: Careful microscopic examination is the most important parameter in the grading of MEC. This meticulous microscopic examination emerges as the cornerstone in grading MEC. Both MSKCC and Modified Healey grading methods exhibits effectiveness in evaluating MEC. Our finding indicated that Memorial Sloan Kettering Cancer Center (MSKCC) was the most favourable histological grading system as percentage of agreement found to be 85%. However, further longer studies are imperative to substantiate this finding and for establish of universally accepted grading system for Mucoepidermoid carcinoma.

This is an Open Access (OA) journal, and articles are distributed under the terms of the [Creative Commons Attribution-NonCommercial-ShareAlike 4.0 License](https://creativecommons.org/licenses/by-nc-sa/4.0/), which allows others to remix, tweak, and build upon the work non-commercially, as long as appropriate credit is given and the new creations are licensed under the identical terms.

For reprints contact: reprint@ipinnovative.com

1. Introduction

Salivary gland malignancies make up 0.5 to 1.2% of all cancers and 5% of all head and neck cancers. 21.7% of malignant lesions are found in all salivary gland

neoplasms with mucoepidermoid carcinoma (MEC) being the most common type of salivary gland malignancy. MEC histologically consists of a mixture of mucus cells, intermediate cells and epidermoid cells. It is graded as low, intermediate and high grade based on histological features. The morphologic diversity of MEC can pose diagnostic challenges. Various grading systems have been

* Corresponding author.

E-mail address: vaishalipatho72@gmail.com (M. Mandale).

proposed based on the quantitative and qualitative analysis. For Quantitative analysis: AFIP (Armed force institute of pathology) and Brandwein histological grading system. For Qualitative analysis: Modified Healey system, MSKCC (Memorial Slon Kettering cancer center). World health organization (WHO) recommends AFIP (Armed force institute of pathology) system for histological grading of MEC.

The AFIP and Brandwein system focus on point based quantitative analysis like assigning scores to histological features such as intra cystic component, necrosis, invasion and mitosis. On the other hand Modified Healey System and MSKCC are based on Qualitative analysis emphasizing cytomorphologic and architectural patterns, as well as features like perineural invasion and angiolymphatic invasion. The purpose of this article is comparing these grading systems for MEC and is to conduct, meticulous review of the histological features in order to identify the best or universally accepted grading system. Thus, establishing a reliable grading system which can aid pathologist in achieving greater consistency and ultimately more appropriate therapy for patients with MEC.

2. Materials and Methods

2.1. Inclusion criteria

20 clinically and Histopathologically diagnosed cases of MEC since last 10 years.

2.2. Study design

Two investigators independently evaluated all the 20 cases of MEC, analysing both clinical and histological data for four grading systems, two qualitative and two quantitative system. The qualitative methods included the Modified Healey grading system and Memorial Slon Kettering Cancer Center (MSKCC) while quantitative analysis the point based method included, Armed force institute of pathology (AFIP) and Brandwein grading systems.

2.3. Statistically analysis

Each parameter in the grading system was assigned score point and sum of the score for histological parameter was calculated. This total score was then used to determined the grading of each case.(Table 1)

Based on cytomorphologic and architectural pattern the qualitative histological grading system including the Modified Healey system and MSKCC system were proposed (Tables 2 and 3). Modified Healey system was considered the best system because it focused on predominant morphological features for certain histological para meters and on other hand, the MSKCC system complied various histopathological features for grading, (Table 6)

Table 1: Quantitative grading of AFIP and Brandwein

A): Quantitative grading of AFIP	Grade
AFIP (Point Based)	
Intracystic component <20% = 2pts	Low grade (0 -4)
Neural invasion present = 2pts	Intermediate grade (5 - 6)
4 or more mitoses (3)	High grade (7 or more)
Necrosis present = 3pts	
Anaplasia = 4 pts	
B): Quantitative grading of Brandwein	Grade
Brandwein (point based)	
Intracystic component less than 25% (2)	Low grade (0)
Tumor front invades in small nests and islands (2)	Intermediate grade (2 - 3)
Pronounced nuclear atypia (2)	High grade (4 or more)
Lymphovascular invasion (3)	
Bony invasion (3)	
4 or more mitoses (3)	
Perineural invasion (3)	
Necrosis (3)	

Table 2: Qualitative grading modified Healy system

Low grade
Macro and microcysts
Rare intermediate cells
Rare mitotic figures
Absent/minimal nuclear pleomorphism
Well circumscribed tumor with broad edges
Extravasated mucin and fibrotic stroma present
Intermediate grade
Microcysts and solid component
More intermediate cells
Few mitotic figures
Slight nuclear pleomorphism
Uncircumscribed tumor
Fibrotic stroma separating tumor nests
High grade
Predominantly solid, with or without microcysts
Perineural invasion present
Many mitotic figures
Nuclear pleomorphism, including presence of prominent nucleoli
Predominance of intermediate cells
Desmoplastic stoma

The data obtained was statistically analysed using proportion and percentage method. Total score of each grading system was compared with that of the MSKCC System and percentage of agreements among system was determined. (Tables 4, 5 and 6)

3. Result

In this retrospective study, 20 cases of histopathologically diagnosed MEC were studied from the institution. Each

Table 3: Memorial sloan kettering cancer center (MSKCC) grading system

Low grade
Predominantly cystic growth pattern (> 80%)
0- 1 mitotic figures/10 high power fields (HPF)
Well circumscribed
No necrosis
Intermediate grade
Predominantly solid growth pattern
2- 3 mitotic figures/10 high power fields (HPF)
Well circumscribed or infiltrative
No necrosis
High grade
Any growth pattern but usually solid
≥ 4 mitotic figures/10 high power fields (HPF)
Usually infiltrative
Necrosis is present

Table 4: Showing % of agreement of AFIP with MSKCC grading system

		MSKCC Grading system			Total
		Low	Intermediate	High	
AFIP grading system	Low	9 (45%)			45%
	Intermediate		3 (15%)		15%
	High			1 (5%)	5%
	Total	45%	15%	5%	65%

Table 5: Showing percentage of agreement of Brandwein with MSKCC grading system

		MSKCC Grading system			Total
		Low	Intermediate	High	
Brandwein grading system	Low	4 (20%)			20%
	Intermediate		2 (10%)		10%
	High			2 (10%)	10%
	Total	20%	10%	10%	40%

Table 6: Showing percentage of agreement of modified healey grading system with MSKCC grading system

		MSKCC Grading system			Total
		Low	Intermediate	High	
Modified Healey Grading system	Low	9 (45%)			45%
	Intermediate		6 (30%)		30%
	High			2 (10%)	10%
	Total	45%	30%	10%	85%

case was graded using four grading systems namely Armed Forced Institute of Pathology (AFIP), Brandwein, Modified Healey system and Memorial Slon Kettering Cancer Center (MKSICC).

In our study, Grading of MEC showed the following results:

1. AFIP grading system

- (a) Low grade: 45%
- (b) Intermediate grade: 15%
- (c) High grade: 5% (Table 4 and Figure 1)

2. Brandwein grading system

- (a) Low grade: 20%
- (b) Intermediate grade: 10%
- (c) High grade: 10% (Table 5 and Figure 1).

3. Modified Healey grading system

- (a) Low grade: 45%
- (b) Intermediate grade: 30%
- (c) High grade: 10% (Table 6 and Figure 1)

4. MSKCC grading system

- (a) Low grade: 55%,
- (b) Intermediate grade: 30%
- (c) High grade: 15% (Figure 1)

The obtained data of histological grading AFIP, Brandwein and Modified Healey grading system were compared with MSKCC grading system. [Fig no 2 – Bar diagram]. The findings showed that the distribution of grades in the AFIP and Brandwein system were similar to each other but varied when compared to the MSKCC system.

Based on the data, the total agreement of the AFIP, Brandwein, and Modified Healey System with MSKCC was as follows:

1. Modified Healey: 85%
2. AFIP: 65%
3. Brandwein: 40%

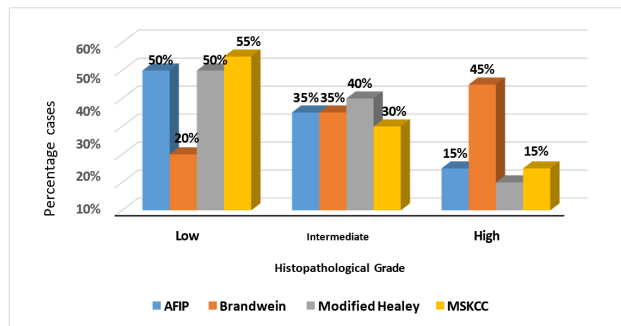


Figure 1: Representing comparison between histopathological grade of MEC and four histopathological grading system

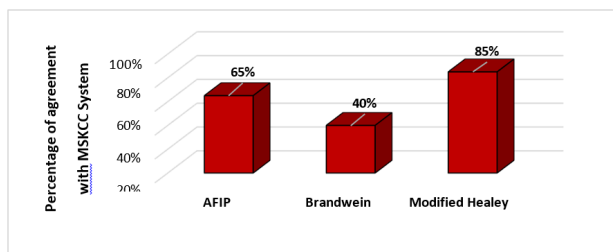


Figure 2: Showing percentage of agreement with MSKCC system

The Modified Haeley grading system exhibited the highest agreement with MSKCC system showing 85% concordance. The AFIP system demonstrated a moderate agreement of 65% while Brandwein system showed the lowest agreement at 40%.

The findings were statistically analysed using proportion and percentage method. The result indicated that the Modified Haeley system which aligns closely with the MSKCC grading system could be considered the most reliable among the three alternative grading system

evaluated. Inference drawn, the Modified Haeley grading system based on its high agreement with MSKCC system, may offer the most accurate reflection of MEC histological grading. The AFIP system also shows reasonable concordance, whereas, the Brandwein system may require further refinement to achieve better alignment with the MSKCC system.

4. Discussion

MEC is most common malignant salivary gland tumour which usually presents with histological, biological and clinical diversity.¹ It is histologically characterized by cystic, solid or solid cystic growth patterns composed of varying proportion of mucous, epidermoid and intermediate cells.² MEC is being graded as low grade, intermediate grade and high grade. Histological grading of MEC acts as significant predictor for the prognosis of the lesion. This will be an important tool for the treatment management of the MEC. Amongst the different grading systems proposed are AFIP and Brandwein for quantitative analysis and for qualitative analysis systems suggested are MSKCC and Modified Healey histological grading systems. Though the outcome of MEC has been shown to be associated with histological grades, there is no single grading system that is universally accept.³

Foote and Frazell classified the Mucoepidermoid tumours as low grade and high grade. In the literature, most authors felt that it was impossible to predict biologic behaviour from the histologic appearance of the tumours and it was believed that there were features, clinical and histologic findings that would permit the identification of most aggressive lesions and these authors thought all tumours should be considered malignant, calling them as Mucoepidermoid carcinoma.⁴

Evans 1984, designated a two tiered grading system calling tumours low grade when they demonstrate <10% cystic growth and relying solely on a cut-off of 90% solid, non-cystic architecture to categorize MEC as high-grade MEC. Shortly after, a three tiered grading system with an intermediate category was recognized.⁵ Recent studies highlighted the value of grading in management of the MEC patients. Low grade tumours generally require surgical treatment while high grade tumours require adjuvant radiation as well as neck dissection. Controversies arises in the management of intermediate grade of Mucoepidermoid carcinoma.⁴

The ideal requirement of the histological grading systems were proposed as follows:

1. It should accurately predict the outcome.
2. It should be used for stratification of patient.
3. It should be applicable for all intraoral sites
4. It should have simple criteria.
5. It should be quick and time efficient.⁶

Currently, for MEC, four histological grading systems were proposed which include AFIP, Brandwein system, Modified Healey system and MSKCC.⁷ For the quantitative analysis, AFIP and Brandwein systems were recommended and for qualitative analysis Modified Healey and MSKCC systems.

The AFIP grading system is a point-based system which is based on the parameters that were found useful in predicting the outcome. The histological findings are <20% cystic component, neural invasion, tumour necrosis, anaplasia were considered as parameters for the determination of score. In AFIP system low grade denotes 0-4 points, intermediate ranges between 5-6 and high grade more than 7. Total sum of points were used for the grading of the tumour. According to some pathologists, AFIP grading system risks undertreating some patients.

Brandwein and associates proposed a modified grading system for the MEC, it is an additional parameter which is added to the AFIP grading system. Additional parameters are as follows. Bone invasion, vascular invasion and tumour invasion in nests.⁵ Total score in the Brandwein system for low grade MEC considered to be 0 and 2-3 for intermediate grade and more than 4 for high grade MEC. Studies in the literature, revealed that Brandwein grading system seems to upgrade MEC and classify some indolent tumour as high grade which might result in unnecessary treatment for these tumours.

Nance et al support this finding, in his studies intermediate cluster with low MEC.⁸ While in AFIP ARO et al. showed that intermediate cluster with high grade MEC.⁹ The intermediate grade demonstrates the most variability between grading systems and most controversies will be in treatment management of the patient. Though Brandwein grading was designed as a modification of the AFIP system, the former requires the presence of just one parameter that classifies a case as intermediate grade, whereas two features make it a high grade tumour.

To overcome these difficulties, new histological grading systems, which are based on the cytological and morphological features of tumours. Based on the qualitative analysis of histopathological findings of MEC, interpreted, two histological grading systems, Modified Healey system, and MSKCC SYSTEM.

Modified Healey system is a descriptive qualitative system which includes parameters such as perineural invasion and vascular invasion. In this system other parameters used are cellular pleomorphism, prominent nucleoli, microcysts, macrocysts, peripheral chronic inflammation which reveal the tumour architecture. Qualitative grading in MEC appears simple. In order to better grade this tumour, Memorial Sloan-Kettering Cancer Center grading system was introduced. MSKCC system was based on the architecture and cytology of the tumour. Using this system, MEC were graded as low grade when they have circumscribed borders

are mostly cystic, showing no significant pleomorphism, mitoses or tumour necrosis.

Inflammation which reveals the tumour architecture. Qualitative grading in MEC appears simple. In order to better grade this tumour, Memorial Sloan-Kettering Cancer Center grading system was introduced. MSKCC system was based on the architecture and cytology of the tumour. Using this system, MEC were graded as low grade when they have circumscribed borders are mostly cystic, showing no significant pleomorphism, mitoses or tumour necrosis.

Intermediate grade predominantly solid with or without infiltration, no mitosis and no tumour necrosis and pleomorphism, high grade illustrates increased mitosis. 4/10 HPF and tumour necrosis. MSKCC system does not include perineural invasion, vascular invasion, and bony invasion as grading parameters. This MSKCC system is relatively similar to Healey system but more defined, less ambiguous and does not include perineural invasion and vascular invasion as grading parameters. Raja Seethala (2005) suggested that all grading systems are somewhat cumbersome, ambiguous but evidence suggests that using a system consistently shows greater reproducibility than using an intuitive approach.⁶

Histological grading is the most important tool for the clinicians in determining the appropriate management and prognostication in patients presenting with salivary gland MEC. With this aim, in the present retrospective study, histological slides were reviewed meticulously and all the cases were graded as per the histological grading systems – AFIP, Brandwein, Modified Healey system, and MSKCC. For statistical analysis percentage and proportion were used.

In our study, AFIP system represents 50% cases of low grade MEC, Brandwein analysed 20% cases for low grade MEC, for intermediate grading 35% respectively and high grade exhibit 15% and 45%. (Figure 1) AFIP System when compared with MSKCC it was observed that 9 cases of low grade tumour (45%), intermediate grade 3 cases (15%) and high grade 1 (5%). The percentage of agreement with AFIP and MSKCC was 65% (Figure 2). Previous studies conducted by Quannam Ahemand 2016 reported that only 3 cases out of 19 cases were classified as high grade.³ This finding was in accordance with the present study in our study only 2 cases out of 20 were observed as high grade.³

The Brandwein grading system which was a modification of AFIP suggests a poor percentage of agreement with MSKCC and Brandwein to be 40%. In the literature, different studies carried with reference to the quantitative analysis and concluded that these methods are easier to apply but Brandwein seemed to upgrade most of the lesions. Though this system having more parameters than AFIP, this grading system needs the presence of a single parameter to move in the intermediate grade or presence of just two parameters leads to high grade category.³

Modified Healey system and MSKCC when compared for the percentage of agreement, 85% was observed,

suggesting that most favourable agreement. This finding is in accordance with the previous studies in the literature. Sood et al 2023 conducted study with aimed at comparison of four grading systems for MEC. In this studies, result observed was agreement between MSKCC and Modified Healey was highest at 90% of cases.⁷ There was generally poor agreement between MSKCC and Brandwein grading systems. Brandwein assigned the explained that comparison of agreement among four grading systems revealed lack of consensus in 28% of cases of MEC. This finding is similar to the earlier reports of histological grading in major salivary glands. Agreement between grading systems is far more likely to be seen, when tumours are graded as high or low grades but not intermediate grade.⁵ In the present study, MSKCC and Modified healey shows 85% of the agreement (Table 6). This finding is in accordance with the previous studies which are conducted related with the histological grading.

5. Conclusion

Careful microscopic examination is the most important parameter in the grading of MEC. This meticulous microscopic examination emerges as the cornerstone in grading MEC. Both MSKCC and Modified Healey grading methods exhibits effectiveness in evaluating MEC. Our finding indicate that MSKCC GRADING SYSTEM was the most favourable histological grading system as percentage of agreement found to be 85%. However, further longer studies are imperative to substantiate this findings and for establish of universally accepted grading system for Mucoepidermoid carcinoma.

6. Source of Funding

None.

7. Conflict of Interest

None.

References


1. Yoshida EJ, García J, Eisele DW, Chen AM. Salivary gland malignancies in children. *Int J Pediatr Otorhinolaryngol.*

2014;78(2):174–8.


2. Ellis GL, Auclair PL. Atlas of tumor pathology: In: Tumors of the Salivary Glands. Third series. Washington DC: Armed Forces Institute of Pathology; 1996. p. 1–26.
3. Qannam A, Bello IO. Comparison of histological grading methods in mucoepidermoid carcinoma of minor salivary glands. *Indian J Pathol Microbiol.* 2016;59(4):457–62.
4. Nascimento AG, Amaral AL, Prado LA, Kligerman J, Silveira TR. Mucoepidermoid carcinoma of salivary glands: a clinicopathologic study of 46 cases. *Head Neck Surg.* 1986;8(6):409–17.
5. Katabi N, Ghossein R, Ali S, Dogan S, Klimstra D, Ganly I. Prognostic features in mucoepidermoid carcinoma of major salivary glands with emphasis on tumour histologic grading. *Histopathology.* 2014;65(6):793–804.
6. Seethala RR. An Update on Grading of Salivary Gland Carcinomas. *Head Neck Pathol.* 2009;3(1):69–77.
7. Sood N, Meena S, Gupta R, Gupta S. Histologic grading of salivary gland mucoepidermoid carcinoma: A comparison of four grading systems and correlation with survival. *J Cancer Res Ther.* 2024;20(1):57–61.
8. Nance MA, Seethala RR, Wang Y, Chiosea SI, Myers EN, Johnson JT, et al. Treatment and survival outcomes based on histologic grading in patients with head and neck mucoepidermoid carcinoma. *Cancer.* 2008;113(8):2082–9.
9. Aro K, Leivo I, Mäkitie AA. Management and outcome of patients with mucoepidermoid carcinoma of major salivary gland origin: a single institution's 30-year experience. *Laryngoscope.* 2008;118(2):258–62.


Author biography

Vaishali Anil Nandkhedkar, Assistant Professor  <https://orcid.org/0000-0001-9676-7182>

Mandakini Mandale, Professor Academic  <https://orcid.org/0000-0002-7878-2888>

Jayanti Humbe, Associate Professor  <https://orcid.org/0000-0003-1926-915X>

Savita Prashant Wagh, Assistant Professor  <https://orcid.org/0000-0002-9737-7941>

Shubhankar Anil Nandkhedkar, PG Student  <https://orcid.org/0009-0008-5381-8478>

Cite this article: Nandkhedkar VA, Mandale M, Humbe J, Wagh SP, Nandkhedkar SA. Mucoepidermoid carcinoma: A comparative analysis of histological grading systems. *J Oral Med, Oral Surg, Oral Pathol, Oral Radiol* 2024;10(2):107-112.