



Content available at: <https://www.ipinnovative.com/open-access-journals>

Journal of Oral Medicine, Oral Surgery, Oral Pathology and Oral Radiology

Journal homepage: [www.joooo.org](http://www.joooo.org)



## Case Report

# Navigating neurofibroma: A clinical case report

Dipanwita Chakraborty<sup>1\*</sup>, Malashri N Ghatke<sup>2</sup>, Miriyala Satyashree Vibha<sup>3</sup>,  
Shilpa Ravishankar Tayi<sup>2</sup>

<sup>1</sup>Dept. of Community Oncology, Sri Shankara Cancer Hospital & Research Centre, Bangalore, Karnataka, India

<sup>2</sup>Dept. of Oral Medicine and Radiology, Navodaya Dental College and Hospital, Raichur, Karnataka, India

<sup>3</sup>National Dental Care, Hyderabad, Telangana, India



## ARTICLE INFO

### Article history:

Received 21-05-2024

Accepted 30-05-2024

Available online 17-06-2024

### Keywords:

Spindle cell neoplasm

Solitary neurofibroma

Hard palate

## ABSTRACT

Spindle cell neoplasm is an unusual bimorphic malignant tumor that typically affects the upper aerodigestive tract mucosa but can potentially arise elsewhere in the body. A diverse range of benign and malignant tumors, including those with neural, fibroblastic, vascular, myofibroblastic, myogenic, and epithelial origins, are together referred to as soft tissue spindle cell neoplasms. The average age of occurrence is 51 years for men and 67 years for women, with a predominance of men. There is limited information in the literature about the symptoms of spindle cell neoplasms. These tumors typically have a polypoid form, with a high concentration of dysplastic spindle cell components. They are composed of surface epithelial alterations ranging from mild epithelial dysplasia to invasive carcinoma. The article provides insight into a case of neurofibromatous variant of spindle cell neoplasm.

This is an Open Access (OA) journal, and articles are distributed under the terms of the [Creative Commons Attribution-NonCommercial-ShareAlike 4.0 License](https://creativecommons.org/licenses/by-nc-sa/4.0/), which allows others to remix, tweak, and build upon the work non-commercially, as long as appropriate credit is given and the new creations are licensed under the identical terms.

For reprints contact: [reprint@ipinnovative.com](mailto:reprint@ipinnovative.com)

## 1. Introduction

Spindle cell neoplasm is an aggressive and uncommon variant of squamous cell neoplasm characterized by the rapid growth of both epithelial and mesenchymal elements. These neoplasms make up 1% of all oral cavity malignancies and are rather uncommon.<sup>1</sup> Due to its propensity for early metastasis and recurrence, these type of neoplasms require prompt diagnosis. In 2013, Shamim T. presented a basic working type classification of spindle cell neoplasms that comprises neural, myofibroblastic, muscular, fibroblastic, vascular, epithelial, odontogenic, and other cancers.<sup>2</sup> Spindle cell neoplasms can range in nature from benign to reactive, with some being malignant. Neoplasms can present as ulcerated, polypoid, pedunculated tumors that protrude from the mucosal surfaces. The

risk factors for spindle and squamous cell neoplasms are unequivocally the same, including alcohol, tobacco, poor dental hygiene, and a history of radiation exposure. The case report contains a case of a neurofibroma of the hard palate, which is a neural variant of spindle cell neoplasm.

## 2. Case Report

A female patient aged 40 years walked into a dental college in Raichur, Karnataka, India in the year 2022 with a complain of growth in the palatal region of the mouth which had been present for a year, associated with pain in the same region for 2 months. The growth was of peanut size and increased to the present size in due course of time. The pain developed gradually and was intermittent, throbbing type, moderate in intensity, and radiating to the right and left temporal region. Starting on day four or five, the growth started presenting bloody discharge. There was

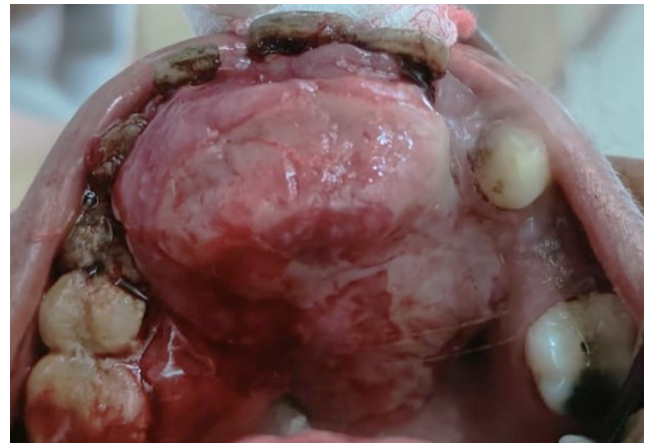\* Corresponding author.

E-mail address: [dipnweeta@gmail.com](mailto:dipnweeta@gmail.com) (D. Chakraborty).

no significant family history.

During a prior visit to a private dental facility, the patient received a prescription for medications, but was unable to recall the specifics when questioned.

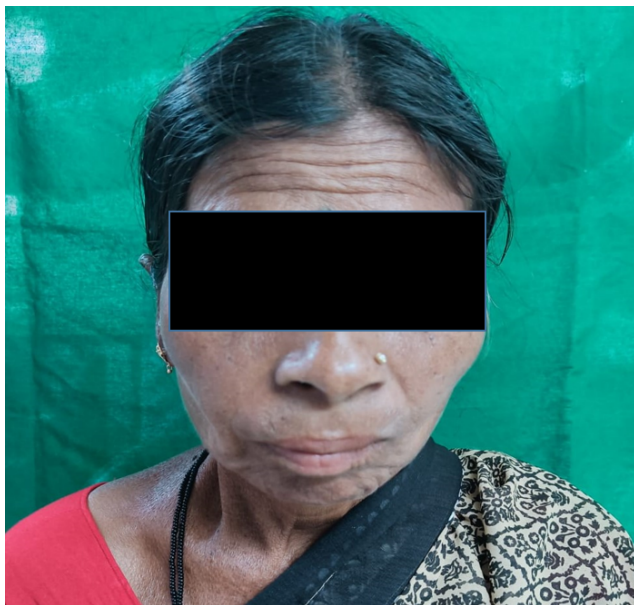Extra-oral examination revealed no gross facial asymmetry. (Figure 1) On intra-oral inspection, a round to oval-shaped well-defined exophytic growth was noted in the palatine region, measuring approximately 6x4x3 cm<sup>3</sup> [LxWxD]. The anteroposterior extension of the growth involved the palatal aspects of teeth no. 11, 12, 13, 14, 15, 21, 23, and 24 anteriorly till the junction of the hard and soft palate posteriorly. Medio-laterally the growth extended 1cm to the right and 2cm to the left from mid-palatine(midline) suture respectively. The growth was pale pink to reddish in color, surface was erythematous with the presence of areas of erosion. The surrounding mucosa showed inflammation. On palpation, the growth appeared to be pedunculated, tender, soft to firm in consistency, and compressible. Bleeding on palpation from the growth was noted. Inspection of the hard tissues revealed grade I mobility with respect to teeth no 13, 14, 15, and 24, grade II mobility with respect to teeth no 11, 12, and 21; deep proximal caries with respect to teeth no 11, 12, 21. Teeth no 22 and 25 were missing. Teeth no 11, 12, 13, 14, 15, 21 and 23 were tender on percussion. The increased size of the growth resulted in spacing between anterior teeth.(Figure 2)



**Figure 2:** Exophytic growth in the palatine region

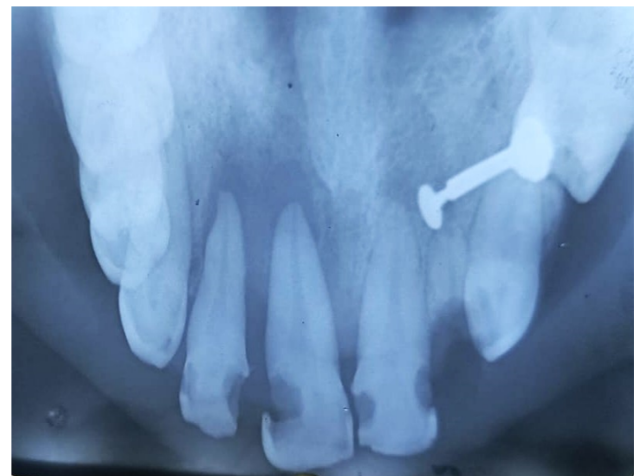
Differential diagnosis of i. Peripheral giant cell granuloma, ii. Pleomorphic adenoma and iii. Irritational fibroma were thought off.

A cross-sectional maxillary occlusal projection showed advanced dental caries with respect to 11 and 21; an ill-defined, complete radiolucency was noted in the periapical region of 11, 12, 21 measuring approximately 0.5x0.5cm<sup>2</sup>, with no sclerotic border suggestive of chronic periapical abscess with respect to 11,12,21. (Figure 3)



**Figure 1:** No noticeable gross facial asymmetry

Based on the chief complaint and the clinical presentation of the growth, the provisional diagnosis was given as peripheral ossifying fibroma involving the anterior maxilla with respect to 11, 12, 13, 14, 15, 21, and 23.



**Figure 3:** Cross-sectional maxillary occlusal projection

Axial plain CT study of the facial bone presented a soft tissue lesion in the right maxilla along the floor of the right nasal cavity involving the anterior 3rd part of the right side of the hard palate with significant soft tissue component projecting into the oral cavity. Anteriorly mass was extending to involve the alveolar margin of central and lateral incisors with significant root erosion of right central and lateral incisors together. The lesion measured approx. 3.5x2.6x2.2 cm<sup>3</sup>. Features were in favor of aggressive bony/mucosal lesions. (Figure 4)



**Figure 4:** Axial plain CT study shows a soft tissue lesion in the right maxilla along the floor of the right nasal cavity involving the anterior 3rd part of the right side of the hard palate with significant soft tissue component projecting into the oral cavity [Seen in the yellow circles]

After a routine surgical profile, the growth was excised under local anesthesia followed by extraction of teeth no. 11, 12, 13, 14, 15, 16, 17, 21 and 23. Antibiotic coverage and analgesics were prescribed for 5 days.

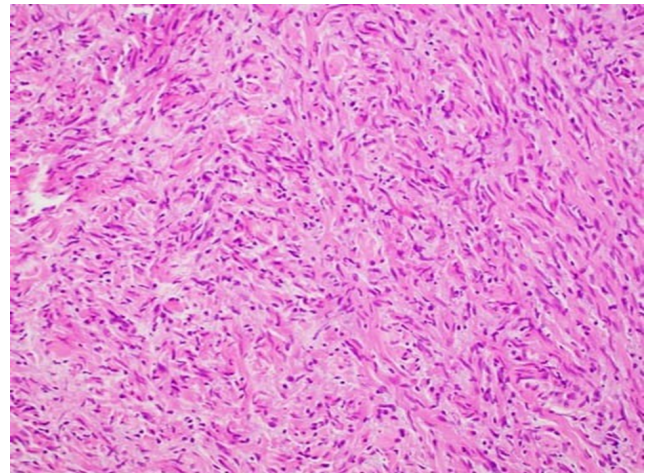
The specimen was sent for biopsy.

Histopathological examination of the specimen revealed interlacing bundles of non-encapsulated elongated spindle cells with wavy nuclei, interspersed monomorphic comma-shaped nuclei, mast cells, and shredded collagen. Areas of nuclear pleomorphism, necrosis, hemorrhage, and mitoses were absent, but the overall histopathology was that of a benign spindle cell neoplasm, a solitary/localized neurofibroma. (Figure 5) The recovery of the patient was uneventful. The follow-up assessment confirmed that the area has healed normally.

### 3. Discussion

Cells that are longer than they are wide are referred to as spindle cells. They can be found in malignancies as well as in normal, healthy tissues. These are the cells with the most variance, and many cell types also display the same "spindled" look. The cytoplasmic extensions of the fusiform spindle cells extend in one or two directions away from the nucleus. Their cytoplasm ranges from medium blue to light blue, and their sizes vary. The form of the cell nucleus ranges from spherical to oval. Physiological cells with spindle morphology include Schwann cells, perineural cells, smooth muscle cells, myoepithelial cells, fibroblasts, and myofibroblasts.

Virchow originally described spindle cell neoplasm in 1865.<sup>1</sup> Men account for 85% of all cases of neoplasia, and they often arise in the sixth to eighth decades of life. It has been associated with prior radiation exposure in the affected area, alcohol misuse, and cigarette smoking.



**Figure 5:** Histopathology of the specimen revealed interlacing bundles of non-encapsulated elongated spindle cells with wavy nuclei, interspersed monomorphic comma-shaped nuclei, mast cells, and shredded collagen

While many spindle cell neoplasms are benign or just reactive, some are malignant. The genesis of spindle cell neoplasms in the oral cavity can be linked to mesenchymal, odontogenic, and epithelial components.

According to the proposed working classification of spindle cell neoplasms of the oral cavity by Shamim T,<sup>2</sup> neurofibroma is a type of benign spindle cell neoplasm/ benign neurogenic neoplasm Neurofibromas (NF) are rare tumors that mostly affect soft tissue and are infrequently observed intraosseously in the maxillofacial region. Shklar and Meyer (1963) classified neurofibroma as (i) solitary/single and (ii) Multiple (Neurofibromatosis, Von Recklinghausen's Syndrome).<sup>3</sup>

WHO defines 'Neurofibroma as a benign tumor of the peripheral nerve sheath phenotype with mixed cellular components which includes Schwann cells, perineural hybrid cells, and intraneural fibroblasts'. The prevalence of solitary NF in the oral cavity is 6.5%, according to published research.

Neurofibroma can present as a single lesion or as a component of the generalized syndrome of neurofibromatosis. (also known as von Recklinghausen disease). The localized form is identical to the disseminated form, except for the absence of systemic and hereditary factors present in the disseminated type. It is rare for a solitary NF to affect the oral cavity; Bruce was the first to report a single NF in the oral cavity in 1954.<sup>4</sup> Few occurrences of this kind have been documented in the literature since then. Solitary oral NF can occur on the tongue, hard palate, buccal mucosa, labial mucosa, and floor of the mouth.

The cause of solitary neurofibroma is currently unknown. Neurofibromatosis (NF) is correlated with the expression of

the NF-1 and NF-2 genes and is inherited as an autosomal dominant trait characterized by a high degree of penetrance and variable expressivity. It is estimated that in up to 50% of cases, NF is caused by spontaneous mutation.

The etiopathogenesis of NF is not yet fully understood, and it is unclear whether Schwann cells or perineural fibroblasts are the origin of these cells. Perineural fibroblasts are a type of neuroectodermal tissue cell that produces collagen. They form a network around each nerve's axis cylinder and are associated to Schwann cells.

Neurofibromas are divided into two main categories by the World Health Organization (WHO): dermal and plexiform. Dermal neurofibromas originate from a single peripheral nerve, whereas plexiform neurofibromas are linked to multiple nerve bundles.

Neurofibromas in the oral cavity are painless, slowly growing lesions that do not exhibit any symptoms. These tumors exhibit a wide range of sizes, from small nodules to large masses. They are usually found in individuals between the ages of thirty to forty and are slightly more common in males. Patients may feel pain if the lesion is secondarily traumatized due to its location, e.g., on the tongue or the hard palate.

Depending on the onset, gender predominance, location, and classical slow growing feature, oral neurofibroma can be diagnosed as collagenous fibroma, lipoma, schwannoma etc.<sup>5</sup>

Only an incisional biopsy or an excisional biopsy combined with a histopathologic examination can provide a firm diagnosis of oral neurofibroma. Histopathologically, neurofibromas typically display ropey collagen bundles interwoven with ovoid to spindle-shaped cells that have curved nuclei, all within a myxocollagenous backdrop.

Regarding MRI patterns of neurofibroma, there is often variability in T-2 images and low to intermediate intensity in T-1 images.<sup>6</sup>

Immunohistochemically, neurofibroma shows heterogeneous expression and distribution patterns of laminin and S-100 protein. These markers are commonly used to identify malignancies that arise from the peripheral nerve sheath tumors.<sup>7,8</sup>

The preferred course of treatment for NF is surgically excising solitary lesions while attempting to preserve the nerve from which the tumor originated. Nevertheless, in certain cases, tumor invasion necessitates nerve resection. Recurrence following surgical excision is possible, and repeated recurrences particularly in patients carrying the NF-1 gene have been linked to malignant transformation.

#### 4. Conclusion

Oral neurofibroma poses a diagnostic challenge for clinicians due to its rare presence in the oral cavity. These lesions need to be closely watched and treated with great care because they have the potential to grow into neurofibromatosis and have a tendency toward malignant

change. Experts strongly recommend genetic testing for individuals who develop neurofibroma before the age of 20 years to effectively rule out the potential of neurofibromatosis.

#### 5. Declaration of Patient Consent

The authors certify that all the appropriate consents regarding the use of the images of the patient and other clinical information were taken from the patient before publishing the article.

#### 6. Source of Funding

None.


#### 7. Conflict of Interest

The authors declare that there is no conflict of interests regarding the publication of this paper.

#### References

1. Biradar MV, Dantkale SS, Abhange RS, Kamra HT, Birla K. Spindle cell carcinoma of the tongue: a rare variant of squamous cell carcinoma. *Ecancermedicalscience*. 2014;8:447.
2. Shamim T. A simple working type classification proposed for the spindle cell neoplasms of the oral cavity. *J Cytol*. 2013;30(1):85.
3. Richards D. Neurofibroma of the oral cavity. *Br J Oral Surg*. 1983;21(1):36–43.
4. Angiero F, Ferrante F, Ottonello A, Maltagliati A, Crippa R. Neurofibromas of the Oral Cavity: Clinical Aspects, Treatment, and Outcome. *Photomed Laser Surg*. 2016;34(2):56–60.
5. Venkataswamy AR, Ranganath SP, Challapalli SM, Mohanthy L. Nonsyndromic solitary neurofibromas in the oral cavity: Case series and literature review. *J Indian Acad Oral Med Radiol*. 2016;28(1):52–6.
6. Bhattacharyya I, Cohen D. Oral neurofibroma; 2011. Available from: <https://emedicine.medscape.com/article/1079193-overview?form=fpf>.
7. Campos MS, Fontes A, Marocchio LS, Nunes FD, DeSousa SC. Clinicopathologic and immunohistochemical features of oral neurofibroma. *Acta Odontol Scand*. 2012;70(6):577–82.
8. Slootweg PJ, Roboll PJ, Müller H, Lubsen H. Spindle-cell carcinoma of the oral cavity and larynx: immunohistochemical aspects. *J Craniomaxillofac Surg*. 1989;17(5):234–6.

#### Author biography

**Dipanwita Chakraborty**, Community Oncologist  
 <https://orcid.org/0009-0002-0656-3499>

**Malashri N Ghatke**, Assistant Professor

**Miriyala Satyashree Vibha**, Consultant Oral Physician and Oral Radiologist

**Shilpa Ravishankar Tayi**, Assistant Professor

**Cite this article:** Chakraborty D, Ghatke MN, Vibha MS, Tayi SR. Navigating neurofibroma: A clinical case report. *J Oral Med, Oral Surg, Oral Pathol, Oral Radiol* 2024;10(2):118–121.