



Content available at: <https://www.ipinnovative.com/open-access-journals>

Journal of Oral Medicine, Oral Surgery, Oral Pathology and Oral Radiology

Journal homepage: www.joooo.org



Case Report

Long term self-resolution of a mandibular traumatic bone cyst: A patient report

Kinan G Zeno^{1*}, Wedad Z Saab¹, Lea Al Matny², Rachid Haidar³, Joseph G Ghafari^{1,4}

¹Dept. of Dentofacial Medicine, American University of Beirut Medical Center, Beirut, Lebanon

²Carestream Dental, Austin, Texas

³Dept. of Surgery, American University of Beirut Medical Center, Beirut, Lebanon

⁴Dept. of Orthodontics, University of Pennsylvania, Philadelphia, Pennsylvania



ARTICLE INFO

Article history:

Received 30-01-2024

Accepted 27-02-2024

Available online 17-06-2024

Keywords:

Traumatic bone cyst

Simple cyst

Self resolution

Orthodontic treatment

ABSTRACT

A traumatic bone cyst (TBC) is an uncommon asymptomatic benign lesion usually diagnosed on radiographic examination as a unilocular radiolucency in the posterior mandibular region. It is classified as a pseudocyst because of absent epithelial lining. The etiology remains unclear but is often a localized aberration in normal bone remodeling or metabolism associated with trauma. We report a TBC in a boy that appeared in the first year of orthodontic treatment below the mandibular right second molar and self-healed nearly 4 years later. The patient had no history of trauma. Surgery was discarded because of difficult access and risk of nerve damage; also, the mandibular body continuity was not jeopardized. Clinical examination and periodic radiographic and CBCT imaging were performed during orthodontic treatment (25 months) and the following retention (26 months). The findings suggest a course of observation of a slow developing TBC that does not compromise mandibular anatomic integrity.

This is an Open Access (OA) journal, and articles are distributed under the terms of the [Creative Commons Attribution-NonCommercial-ShareAlike 4.0 License](https://creativecommons.org/licenses/by-nc-sa/4.0/), which allows others to remix, tweak, and build upon the work non-commercially, as long as appropriate credit is given and the new creations are licensed under the identical terms.

For reprints contact: reprint@ipinnovative.com

1. Introduction

Traumatic bone cysts are infrequently encountered intraosseous cavities diagnosed incidentally on routine radiographic dental evaluations often taken for orthodontic assessment.¹ The lesion lacks epithelial lining, which delineates it from other cysts; it is surrounded by bony walls and is either empty or contains connective tissues and liquid.² Clinically, the lesion is usually asymptomatic, presents without palpable bony expansion, and is most commonly located in the posterior region of the mandible mostly within cancellous bone.

The cyst is also known by several other names such as idiopathic bone cavity, simple bone cyst, progressive bone cyst, solitary bone disease, extravasation cyst, and

traumatic hemorrhagic cyst, reflecting the unknown precise etiology. Different etiological factors have been speculated, such as altered calcium metabolism, low-grade infections, bone tumor degeneration, local alterations in bone growth, increased osteolysis, venous obstruction, local ischemia, intramedullary bleeding, or a combination of these factors.³ Some authors suggested that any kind of trauma, including tooth extractions, can cause the cyst development.³ The most accepted theory relates the lesion to trauma-generated bleeding within the bone with subsequent bone necrosis and resorption. Although not a true cystic bone cavity, the lesion expands because of increased pressure possibly caused by poor venous drainage.⁴

The lesion is mainly diagnosed in patients under 30 years of age with a mean age of 20 years, and is prevalent between the 1st and 2nd decades of life.^{5,6} Although some studies

* Corresponding author.

E-mail address: zenokinan@gmail.com (K. G. Zeno).

did not report gender predilection, some found the lesion to occur more frequently in males.^{2,7}

Traumatic bone cysts are found in almost all bones of the body, mainly in the proximal humerus and femur. Long bone lesions are commonly associated with pathologic fractures. In the jaws, traumatic cysts are usually found in the posterior regions of the mandible, and infrequently in the anterior maxilla, zygoma, ramus, coronoid process, and condyle.⁸ The cysts are rarely associated with tooth resorption, although greater lesions can cause tooth displacement and a painless bone expansion.

Traumatic cysts are mostly unilocular lesions but may be multilocular or lobular. The diagnosis is based on radiographic, clinical, and intraoperative findings. Radiographically, the radiolucent area of the lesion is often limited, oval or rounded in shape, usually located below the roots of the mandibular teeth, but may be superimposed to or bypassing the roots. Clinically, the appearance and palpation of the adjacent oral tissues are within normal range. The teeth involved are vital and rarely displaced.⁸ During surgical exploration, the cystic cavity is empty or contains small amounts of fluid, a finding representing a diagnostic criterion of a traumatic bone cyst.

Treatment modalities of these cysts vary. Except for complete resection of the lesion, each method has a different recurrence rate.⁹ The most common approach consists of thorough curettage and bone grafting. However, spontaneous resolution of untreated TBC has been reported, raising questions about the indication for immediate surgery that increased the risk of morbidity.¹ The conservative approach is usually based on the respective clinical, radiographic, and epidemiological features¹ and requires regular and essential follow-up examinations. Curettage followed by placement of plasma-rich protein as a means of bone regeneration has been suggested in children because it reportedly leads to faster and favorable healing.¹⁰

Our aim was to present a patient report describing the clinical and radiographic findings of a traumatic cyst during orthodontic treatment, and the later total self-resolution of the lesion nearly 2 years after treatment.

2. Case Report

A 9 year 10 months old boy presented to the American University of Beirut Medical Center for orthodontic check-up. His medical history and dental history were considered non-contributory to the orthodontic problem. On clinical examination he had a symmetrical, slightly convex profile. His maxillary dental midline was coincident with the facial midline, but his mandibular midline was deviated 2 mm to the right. Canines and molars were in Class II, the overjet at 4 mm, and the overbite at 40%. The Institutional Review Board determined that the reported treatment and follow up of this patient did “not meet the federal definition of systematic investigation designed to develop or contribute

to generalizable knowledge” and that this activity is “not human subject research.” The parents and patient signed a consent form before starting the treatment and for the publication of this report.

Treatment included an initial phase of functional appliance (bionator), upon which the profile and occlusion improved, because of patient compliance and concomitant growth. A year later, the bionator was replaced with a headgear to further enhance differential growth. Another year later, the permanent teeth had erupted except for the mandibular second molars. A panoramic radiograph revealed a radiolucency below the right second molar which was still late developing with open apices (Figure 1). The decision was to observe through subsequent spaced radiographs.

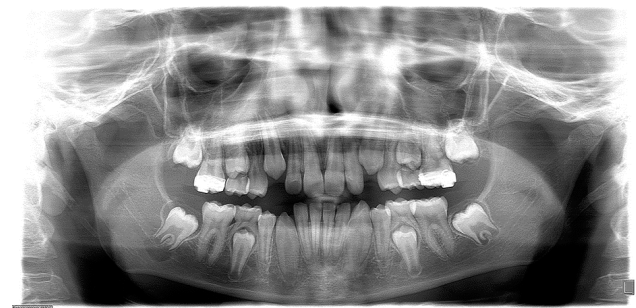

Figure 1: On panoramic radiograph, radiolucency below the developing right second molar (open apices)

Eight months later, the patient developed an inflammation in the mandibular right quadrant with palpable submandibular and cervical lymph nodes. The pediatrician prescribed antibiotics and referred the patient back to our team. On panoramic imaging, the radiolucent area apical to the second molar had increased (Figure 2). The patient was referred to an oral surgeon who ordered a CBCT, which revealed that the apices of the second molar were still developing, and its direction and follicular sac were within the norm (Figure 3 A). A partially corticated, well-defined but irregularly shaped low-density area was observed apical and lingual to the mandibular canal. Uniform thinning of the lingual cortical plate was present without expansion or interruption (Figure 3 B). The mandibular canal was in direct contact with the low-density area (Figure 3C). The periodontal ligament space of the second molar was within the normal range.

The surgeon prescribed a continuous antibiotics course for nearly one week before soft tissue exposure of the second molar. The tissues were biopsied, and the results were consistent with a traumatic bone cyst with a differential diagnosis of giant cell granuloma, or aneurismal bone cyst. One consideration by the surgeon was to perform curettage of the lesion to stimulate bleeding and promote healing. However, the irregular outline of the lesion and

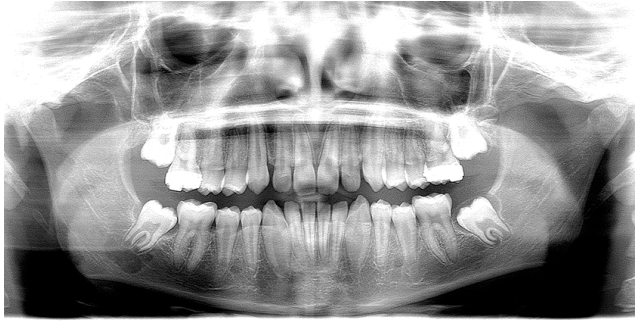

Figure 2: Panoramic view showing the increase in size of the radiolucency, 8 months after the previous radiograph (Figure 1)

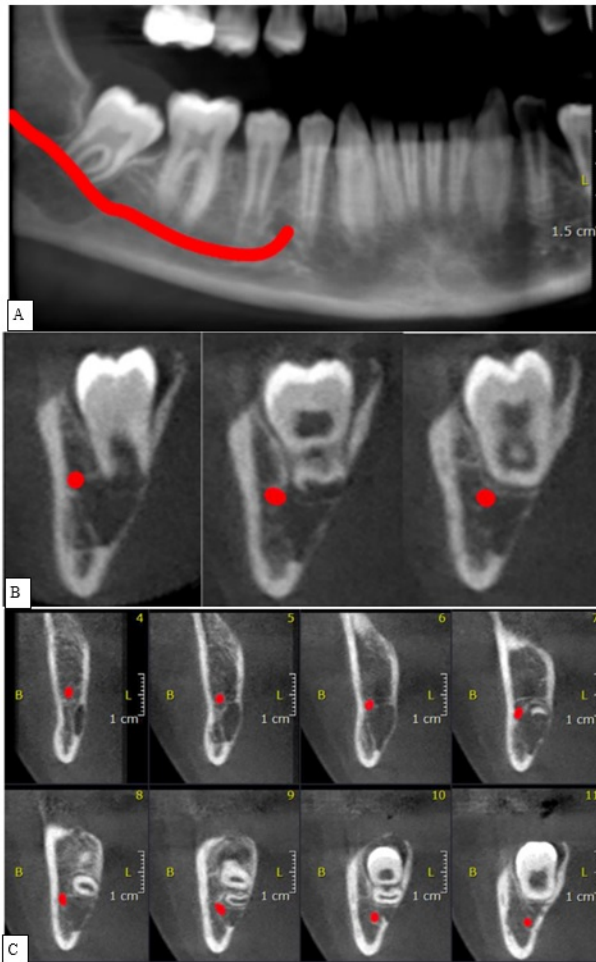


Figure 3: Reconstruction from the CBCT with tracing of mandibular canal (red). **A):** Panoramic view. **B):** Coronal view showing successive frames from more anterior to more posterior slices

its proximity to the mandibular canal made the surgical access difficult and risky. Considering the high probability of a benign pseudocyst and the possibility of spontaneous healing of traumatic bone cysts, the decision was to follow-up with radiographic imaging at 6-month intervals (Figure 4).

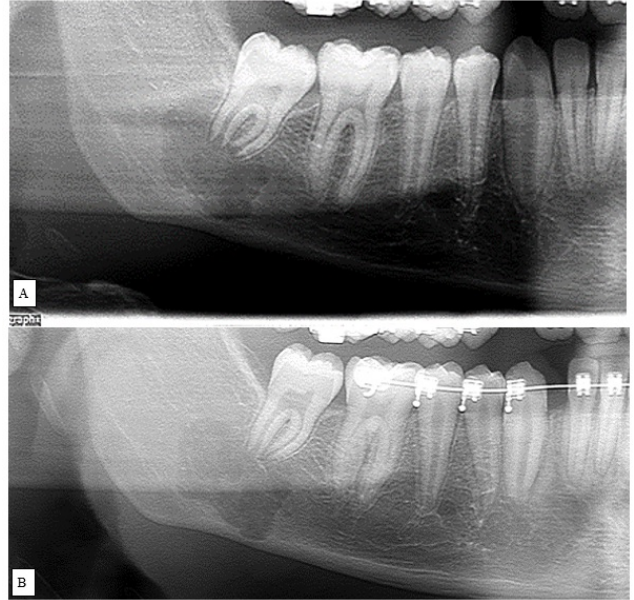


Figure 4: Follow-up panoramic radiographs taken at 6 months intervals before (A) and after (B) the placement of fixed appliances on the mandibular teeth

Two months after soft tissue exposure, the second molar started erupting. The same procedure was done on the left second molar at later stage. In the meantime, orthodontic treatment proceeded with care to use light forces to align the teeth.

Nearly 18 months later, a new CBCT, taken in lieu of a panoramic x-ray, revealed further development of the second molar but still with immature apices (Figure 5 A). The surrounding lamina dura was intact, and the periodontal ligament space was within the normal range. The underlying non-corticated lesion occupied the entire bucco-lingual width along with thinning and expansion of the lingual cortex, without evidence of interruption (Figure 5 B). The lesion was in direct contact with the mandibular cortex. The radiolucency had expanded in the mesiodistal, bucco-lingual and vertical directions in comparison with the previous scan (Figure 3).

Regular follow-up continued after completion of the orthodontic treatment, which was nearly 3 years since the discovery of the initial radiolucency. At a later visit, another CBCT scan disclosed enlargement of the irregularly shaped cystic lesion, which extended from the apical of the molar to the angle of the mandible (Figures 6 and 7). The lesion occupied nearly the entire buccolingual width resulting in a

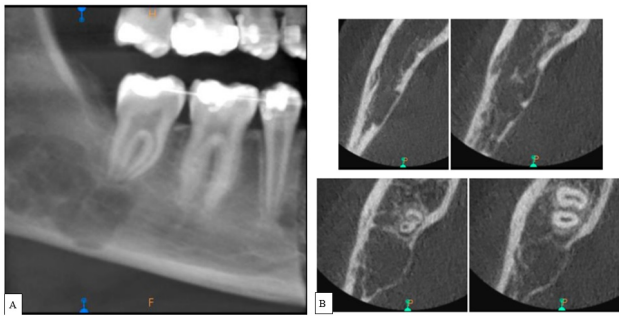


Figure 5: **A):** Panoramic reconstruction showing the mandibular right second molar with immature apices and expansion of the cyst. **B):** On axial cuts of the posterior right mandible, the lesion occupies the entire bucco-lingual width, and the lingual cortex is thinning without signs of interruption

non-uniform thinning of the lingual cortical plate. Endosteal scalloping was observed on the lingual cortex. Moreover, the lesion appeared closer to the mandibular canal compared with the previous record. The second molar had reached full maturity, with an intact lamina dura and normal periodontal ligament space. The findings were still consistent with a traumatic bone cyst, but a central giant cell granuloma could not be ruled out. For this reason, an MRI with contrast was recommended and performed nearly two months later.

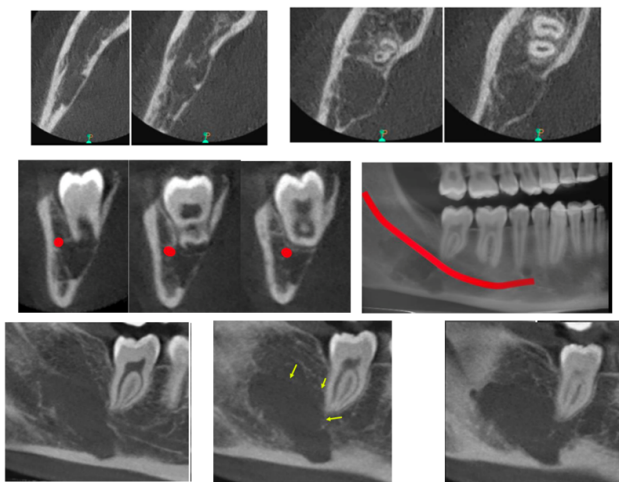

Figure 6: Coronal section and panoramic reconstruction showing the cyst inferior and posterior to the mandibular right second molar. The mandibular canal is traced in red. Note the margins of the cyst are indicated by the yellow arrows in the middle picture of the bottom row.

Multiplanar multi sequence images of the mandible were taken with and without intravenous contrasting injection to evaluate vascularization of the lesion and rule out malignancy. The MRI scan revealed a 1.8 x 1.8 x 1 cm (anteroposterior, craniocaudal, and transverse dimensions) benign appearing cystic lesion of the bone that involved the

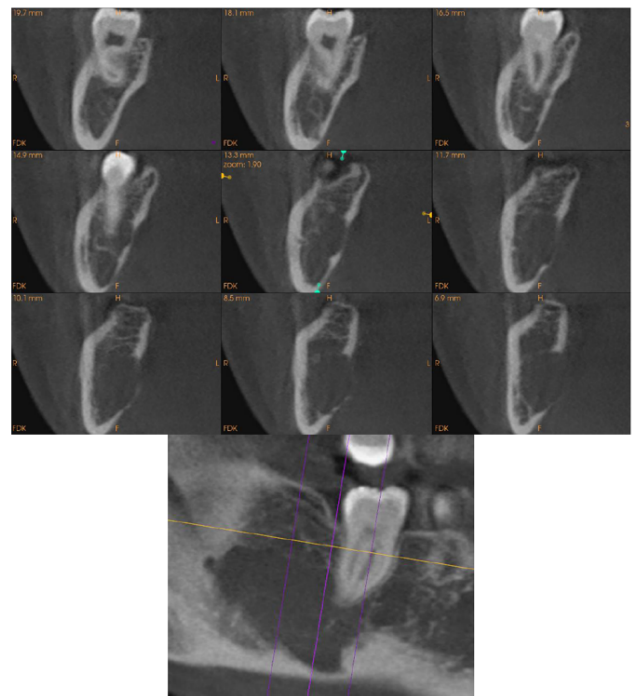


Figure 7: Axial views of the CBCT in Fig. 6. Note the expansion of the cyst and thinning of the lingual cortical plate

mandibular bone marrow with significant ballooning and thinning of the adjacent medial cortex. The lesion showed a minor amount of layering of fluid along the posterior aspect, which could likely be proteinaceous material or blood products. The lesion did not show extraosseous extension into the soft tissues and no active periostitis or adjacent bone marrow edema. The differential diagnosis included a simple bone cyst or a post-traumatic cyst.

Two years later, over six years since the lesion was initially detected, a panoramic radiograph revealed the spontaneous resolution of the cyst with bone remodeling (Figure 8). Another panoramic radiograph was taken 7 months later that confirmed the negative finding and further self-healing noted with bone remodeling and filling the space of the lesion (Figure 9).

3. Discussion

The present report suggests that a conservative approach should be considered when an asymptomatic traumatic bone cyst develops slowly, and mandibular border continuity remains generally the same over repeated check-ups. The cyst, which was found incidentally, fitted the common description and prevalence of the intraosseous cavity, in terms of location, age of patient, absence of pain (usually subsequent to microfractures), and vital non-displaced or mobile involved teeth. The fact that it developed and increased in size within the period of orthodontic treatment

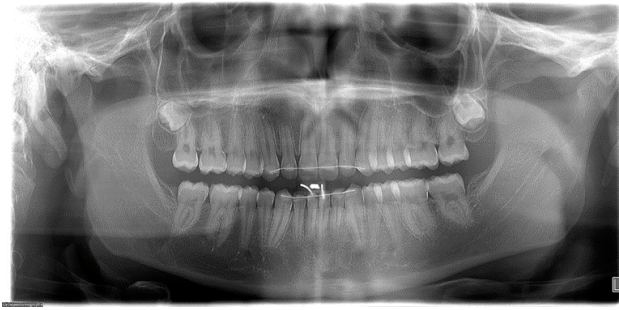


Figure 8: Panoramic radiograph taken 2 years after removal of the orthodontic appliances

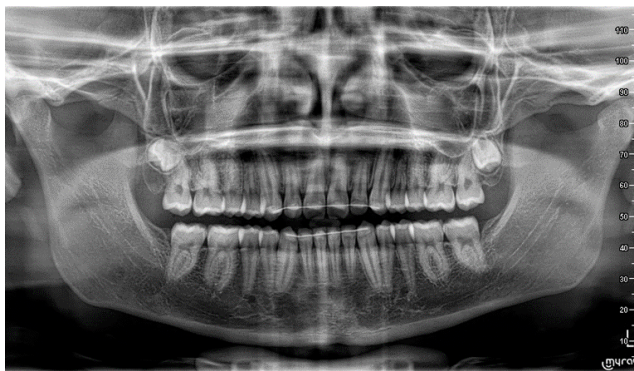


Figure 9: Panoramic radiograph taken 7 months after the record in Figure 8

warranted this report.

The genesis of the lesion was during the initial phase of growth modification with a functional appliance, and it progressed during the orthodontic treatment with fixed appliances. Whereas the origin and nature of the trauma may be multifactorial, the bionator may have generated additional trauma sustained with excellent compliance. Although treatment was interrupted for a significant period when the lesion started progressing, the continuous stresses from orthodontic treatment, even if minimal, may have contributed to supporting an ongoing pathology.

Bony expansion is rare in the early phases of the lesion and is usually seen at the later stages in about 18–50% of patients.¹¹ In our patient, the lingual expansion, documented on CBCT, was associated with endosteal scalloping on the lingual cortex, a feature suggestive but not diagnostic of traumatic bone cysts because other odontogenic lesions also have scalloped borders. Scalloping has been reported in 68% of traumatic bone cysts that occurred between and away from the teeth.¹²

Based on a review of current evidence, we contemplated surgical intervention. The common surgical approach is enucleation and curettage of the cavity to induce fresh bleeding in the operated site. The expected healing period is between 6 and 24 months.¹³ Satish et al.¹¹ associated the

invasiveness of the intervention with the cyst characteristics. A segmental resection of a large cyst was followed by free vascularized fibular reconstruction to replace substantial bone loss with only the inferior border of the mandible intact and at risk of fracture. They treated a less invasive lesion with surgical exploration and only induction of bleeding to stimulate healing.

In another variation, Llobot et al.¹⁴ implemented continuous surgical decompression in a 15-year-old patient. After adequate flap reflection, they performed bone trepanation to reach adequate spaces that allowed drainage of the fluid inside the cavity, which was then cannulated with a catheter to allow perpetual drainage and avoid the risk of obstruction. Fillers used after cyst enucleation include bone grafts or synthetic materials such as bioglass, gel foam, hydroxyapatite crystals, bone chips, platelet rich plasma, and autologous blood injections, which have been associated with favorable outcomes.¹⁵

A comparison is warranted with traumatic or simple cysts occurring in other areas of the body, most commonly the humerus and femur bones.¹⁶ They are distinguished from the more aggressive aneurismal bone cyst (ABC) which must be observed more closely through frequent imaging (every 2 months) and confirmed by biopsy.¹⁷ The common approach with simple cysts is not to intervene if the lesion is asymptomatic and does not jeopardize the integrity of the involved structure. If the cyst becomes symptomatic (pain or associated limping in lower extremities), it would be caused by microfractures. In the humerus bone, immobilization with an arm sling is used for healing, and the microfractures would actually help the healing. In the neck of the femur, surgical intervention is indicated because of potential fracture and worse morbidity. Thus, curettage is performed, followed with a graft (often allografts replace the previously prevalent synthetic substances), then fixation.¹⁸ Injection of steroids after cyst aspiration has been recommended, but the efficacy and mechanism of action are yet to be determined.¹⁸

We opted for a non-surgical conservative periodic follow-up because the surgical access of a linguallally-extended lesion was deemed invasive particularly considering the benign nature and slow progression of the lesion, and the reluctance of the parents. Moreover, the mandibular inferior border was not fractured and not completely compromised, and the lesion remained asymptomatic at all times. Should the integrity of the mandible be judged at risk during the initially more frequent, then biannual and later annual radiographic follow-ups, surgical intervention that might involve curettage, resection, grafting, and fixation would have become necessary.

Also, one of the co-authors, a pediatric orthopedic surgeon recommended this conservative approach as similar lesions in the rest of the body could self-resolve, as

also corroborated in published reports of self-healing.^{1,19} Additionally, the patient was followed-up regularly for orthodontic retention (every 6 months), the teeth in the mandibular right quadrant were tested for vitality, discoloration, and mobility, and the region around the cyst was palpated buccally and lingually all signs were normal. In total, the patient had been monitored over his orthodontic treatment (25 months) and the following retention period of (36 months) for around 5 years.

Recurrence of traumatic bone cysts is rare but was reported to vary with single (26%) and multiple (71–75%) cyst cavities 3 months post-surgery.^{7,20,21} Whether the recurrence is associated with persistent trauma or the surgical procedures, such as not enucleating the entire cyst, is not known. Complications of traumatic bone cysts may include pathological fractures and side effects of nerve injuries when major surgical intervention is required. Research is needed to determine whether such morbidity might be avoided by adopting the conservative path and for what duration.

4. Conclusion

This patient report, as others available in the literature, suggests that a course of observation should be followed in the presence of a benign slow developing traumatic bone cyst that does not compromise mandibular anatomic integrity over sequential check-ups. In this situation judicious and regular monitoring is required for a condition that might result in self-resolution.

5. Source of Funding

Funding from agencies in the public, commercial, or not-for-profit sectors was not received for this project.

6. Conflict of Interest

None.

7. Statement of Clinical Relevance

The self-resolution of a mandibular traumatic bone 2 years after completion of orthodontic treatment during which the lesion was diagnosed suggested that regular check-ups are recommended before invasive surgery.

References


- Battisti MPL, Soares MQS, Rubira CMF, Bullen I, Lauris JRP, Damante JH. Assessment of spontaneous resolution of idiopathic bone cavity. *J Appl Oral Sci.* 2018;26:e20170288.
- Ahmed KA, Al-Ashgar F. Maxillary solitary cyst: review of literature and case report. *Saudi Dent J.* 1991;3(3):109–13.
- Sandev S, Sokler K, Grgurević J. Traumatic bone cysts. *Acta Stomatol Croat.* 2001;35(3):411–5.
- Xanthinaki AA, Choupis KI, Tosios K, Pagkalos VA, Papanikolaou SI. Traumatic bone cyst of the mandible of possible iatrogenic origin: a case report and brief review of the literature. *Head Face Med.* 2001;2(1):40.


- Discacciati ED, DeFaria VM, Garcia NG, Sakai VT, Pereira AA, Hanemann JA. Idiopathic bone cavity: case series involving children and adolescents. *J Investig Clin Dent.* 2012;3(2):103–8.
- Madiraju G, Yallamraju S, Rajendran V, Srinivasarao K. Solitary bone cyst of the mandible: a case report and brief review of literature. *BMJ Case Rep.* 2014;2014:bcr2013200945.
- Dellinger TM, Holder R, Livingston HM, Hill WJ. Alternative treatments for a traumatic bone cyst: a longitudinal case report. *Quintessence Int.* 1998;29(8):497–502.
- Martins-Filho PR, Santos TS, Araújo VL, Santos JS, Andrade ES, Silva LC. Traumatic bone cyst of the mandible: a review of 26 cases. *Braz J Otorhinolaryngol.* 2012;78(2):16–21.
- Herring JA, Tachdjian MO. *Tachdjian's Pediatric Orthopaedics.* 3rd ed. Philadelphia: Saunders; 1906.
- Subramaniam P, Kumar K, Ramakrishna T, Bhadrana A. Bone regeneration with plasma-rich-protein following enucleation of traumatic bone cyst. *Eur J Dent.* 2013;7(3):377–81.
- Satish K, Padmashree S, Rema J. Traumatic bone cyst of idiopathic origin? A report of two cases. *Ethiop J Health Sci.* 2014;24(2):183–7.
- Kuttenberger JJ, Farmand M, Stoss H. Recurrence of a solitary bone cyst of the mandibular condyle in a bone graft. *Oral Surg Oral Med Oral Pathol.* 1992;74(5):550–6.
- Karthik KP, Balamurugan R, Sahanapushpa T. Traumatic bone cyst of anterior mandible: A surgical approach. *Dent Oral Maxillofac Res.* 2019;doi:10.15761/DOMR.1000306.
- Brunet-Llobet L, Lahor-Soler E, Mashala EI, Miranda-Rius J. Continuous surgical decompression for solitary bone cyst of the jaw in a teenage patient. *Case Rep Dent.* 2019;2019:9137507.
- Panneerselvam E, Panneerselvam K, Chanrashekar SS. Solitary bone cysts-A rare occurrence with bilaterally symmetrical presentation. *J Oral Maxillofac Pathol.* 2014;18(3):481.
- Farr S, Balacó IMS, Martínez-Alvarez S, Hahne J, Bae DS. Current trends and variations in the treatment of unicameral bone cysts of the humerus: a survey of EPOS and POSNA members. *J Pediatr Orthop.* 2020;40(1):68–76.
- Mascard E, Gomez-Brouchet A, Lambot K. Bone cysts: unicameral and aneurysmal bone cyst. *Orthop Traumatol Surg Res.* 2015;101(1):119–27.
- Baghdadi S, Arkader A. Unicameral Bone Cysts: Treatment Rationale and Approach: Current Concept Review. *J Pediatr Orthop Soc North Amer.* 2021;3(2):5–7.
- Sapp JP, Stark ML. Self-healing traumatic bone cysts. *Oral Surg Oral Med Oral Pathol.* 1990;69(5):597–602.
- Suei Y, Taguchi A, Tanimoto K. Simple bone cyst of the jaws: evaluation of treatment outcome by review of 132 cases. *J Oral Maxillofac Surg.* 2007;65(5):918–23.
- Noffke CE, Raubenheimer EJ, Macdonald D. Fibroosseous disease: harmonizing terminology with biology. *Oral Surg Oral Med Oral Pathol Oral Radiol.* 2012;114(3):388–92.

Author biography

Kinan G Zeno, Assistant Professor  <https://orcid.org/0000-0002-1783-885X>

Wedad Z Saab, Resident  <https://orcid.org/0009-0002-3491-3273>

Lea Al Matny, Oral and Maxillofacial Radiologist  <https://orcid.org/0000-0003-1580-8099>

Rachid Haidar, Professor and Head Division of Orthopedic Surgery  <https://orcid.org/0000-0001-5080-7441>

Joseph G Ghafari, Professor and Chairperson  <https://orcid.org/0000-0003-0606-1472>

Cite this article: Zeno KG, Saab WZ, Al Matny L, Haidar R, Ghafari JG. Long term self-resolution of a mandibular traumatic bone cyst: A patient report. *J Oral Med, Oral Surg, Oral Pathol, Oral Radiol* 2024;10(2):134-140.