



Content available at: <https://www.ipinnovative.com/open-access-journals>

Journal of Oral Medicine, Oral Surgery, Oral Pathology and Oral Radiology

Journal homepage: www.joooo.org



Case Report

Ameloblastoma: An aggressive odontogenic neoplasm with altered vickers and gorlin criteria

Cheshta Walia^{1*}, Amer Adel Al Rashidi¹, Sumaiya Waseem Akhtar Mohammed¹, Sudip Roy²

¹Dept. of Oral and Maxillofacial Pathology, Buraydah Private Colleges, College of Dentistry and Pharmacy, Buraydah, Saudi Arabia

²Dept. of Preventive Dental Sciences, Buraydah Private Colleges, College of Dentistry & Pharmacy, Buraydah, Saudi Arabia



ARTICLE INFO

Article history:

Received 06-04-2024

Accepted 30-05-2024

Available online 17-06-2024

Keywords:

Plexiform

Follicular

Mandible

Odontogenic epithelium

Multilocular lesion

ABSTRACT

Plexiform ameloblastoma is a rare aggressive odontogenic neoplasm comprising about 1% of all odontogenic lesions of the jaw arising from cells of enamel organ that has failed to differentiate to form the hard tissues of tooth. Clinically, Ameloblastoma presents as painless swelling of jaw occurring in 3rd and 4th decade in the posterior region of the mandible with equal sex distribution. It shows multiple patterns including solid, unicystic, extra osseous and desmoplastic type. Due to its varied presentation and relative risk of recurrence, it possesses a great challenge to physician for early diagnosis. Vickers and Gorlin (V and G) criteria is an integral part of diagnosis of histological types of Ameloblastoma. This article aims to highlight the variations observed in V and G criteria in the histopathological features of mixed variety of Ameloblastoma in a middle aged man.

This is an Open Access (OA) journal, and articles are distributed under the terms of the [Creative Commons Attribution-NonCommercial-ShareAlike 4.0 License](https://creativecommons.org/licenses/by-nc-sa/4.0/), which allows others to remix, tweak, and build upon the work non-commercially, as long as appropriate credit is given and the new creations are licensed under the identical terms.

For reprints contact: reprint@ipinnovative.com

1. Introduction

Ameloblastoma is a rare developmental lesion arising from odontogenic epithelium with varied spectrum of clinical presentations including benign cystic and aggressive neoplastic. Adamantinoma was first described by Malassez et al. in 1890 and later Ivey and Churchill in 1930 coined the term ameloblastoma. In 2017, World Health Organization categorized ameloblastoma as peripheral including extraosseous variety, unicystic, variety showing intraosseous bone involvement, solid/multicystic, variety extending into bone marrow spaces.¹ Microscopically, follicular and plexiform patterns along with granular, acanthomatous, desmoplastic and basal cell are observed.² Ameloblastoma are usually diagnosed based on the Vickers and Gorlin (V and G) criteria featuring the presence of

hyperchromatism of basal cell nuclei, basal cell palisading, reversal of polarity and cytoplasmic vacuolization with intercellular spacing of lining epithelium.³ However, Gardner DG highlighted that not all ameloblastoma show classic V and G criteria, cytoplasmic vacuolations and reverse polarity may not be present in all histological varieties of ameloblastoma.⁴

Clinically, ameloblastoma is usually painless, slow growing swelling while symptomatic lesions show malocclusion, pain, paresthesia with expansion and perforation of the cortical bone and infiltration of the soft tissues. Radiographically, It demonstrate a multilocular lytic lesion with scalloped margins described as a “soap bubble” or “honey comb” appearance associated with resorption of tooth roots and impacted teeth. Enucleation, curettage or surgical excision remains the mainstay of treatment depending on size and type of the lesion. The risk

* Corresponding author.

E-mail address: chesta.wallia@bpc.edu.sa (C. Walia).

of recurrence accentuates the need for long term clinical follow up.^{3,4} We aim to present a rare case of mixed variety of ameloblastoma in posterior mandible in young adult patient with varied histological features in contrast to classic V and G criteria.

2. Case Report

A 22 year old male patient presented with a slow growing swelling in relation to the right lower back tooth region for the past 2 years. The swelling was gradual in onset with no history of pain, trauma or discharge, though patient often experienced altered sensation over right side of the face. His personal history revealed that he smokes and drinks occasionally. There was no relevant medical, dental, family history of the patient. The patient was moderately built with all vitals within normal limits.

Extraoral examination showed the presence of facial asymmetry. Ill-defined solitary swelling over the right lower third of the face extending anteroposteriorly from right parasymphysis region to the angle of the mandible and superoinferiorly from ala tragus line up to the lower border of the mandible. On palpation, it was hard in consistency, non-tender and non-fluctuant. There was no regional lymphadenopathy observed and overlying skin was free with no signs of trauma or pus discharge. Intraoral examination revealed a single, well-defined, non-ulcerated oval shaped swelling with stretched normal appearing mucosa without any secondary changes. On Palpation, firm, non-tendered swelling measured about 4X 2.5 cm in relation to 44-47 was noted. Obliteration of the right mandibular buccal vestibule along with buccal and lingual cortical plate expansion was present (Figure 1). Radiographic examination performed one year apart showed presence of a well-defined expansive multilocular radiolucent resorptive lesion extending from 44-47 on orthopantomogram (OPG). Resorption of roots of 46 and 47 was evident with thinning of cortical bone (Figure 2). Keeping the clinical features in view, it was provisionally diagnosed as benign odontogenic lesion. Differential diagnosis of ameloblastoma, dentigerous cyst, calcifying odontogenic cyst, calcifying epithelial odontogenic tumor and ameloblastic fibroma was considered.

Fine Needle Aspiration Cytology was performed which yielded blood tinged fluid on aspiration (Figure 1). Assuming the cystic benign nature of the lesion, the incisional biopsy was performed under local anesthesia after obtaining informed consent from the patient and the tissue sections were stained with Hematoxylin and Eosin (H/E) for microscopic evaluation. H/E staining revealed the presence of epithelium arranged as a tangled network of anastomosing strands supported by a very delicate, vascular, connective tissue stroma predominantly. The strands showed the presence of double row of flattened basal cells with inconspicuous reverse polarization and

subnuclear vacuolization (Figure 3). On further scanning the slide, few areas were also recognized showing multiple discrete islands of tumor in the collagenous stroma enclosing central mass of polyhedral, loosely arranged cells resembling the stellate reticulum surrounded by peripheral columnar cells resembling preameloblast (Figure 4). The nuclei of these cells were located opposite to the basement membrane (reversed polarity) with few follicles undergoing microcyst formation. The histopathological features confirm the diagnosis of ameloblastoma of mixed variety.

Further, the patient was referred to oral surgery department for surgical excision of the lesion. The excised tissue showed the similar findings as that of incisional biopsy. The postoperative recovery was uneventful, and no recurrence was observed in 3 years follow-up period. The patient's consent was obtained to publish the case report.

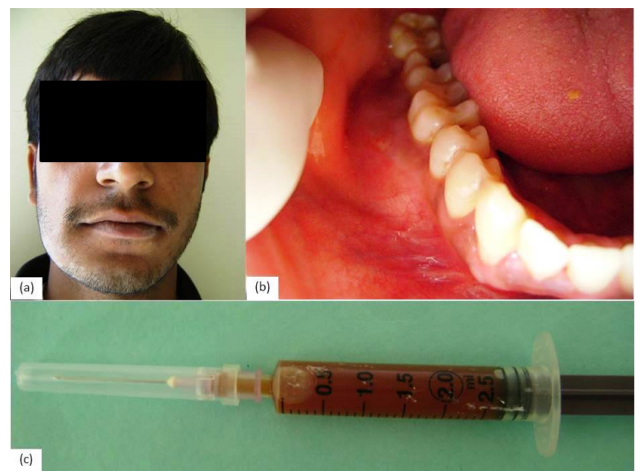

Figure 1: (a) Extraoral photograph showing diffuse swelling in right lower third of face; (b) Intraoral photograph showing large nonulcerated lesion with obliteration of buccal vestibule; (c) FNAC showing straw colored fluid

3. Discussion

Ameloblastoma is a benign but locally invasive odontogenic tumor arising from remnants of tooth forming apparatus including rests of dental lamina, developing enamel organ and the epithelial lining of odontogenic (dentigerous) cysts, or basal epithelial cells of the oral mucosa.⁵ At the molecular level, etiopathogenesis of ameloblastoma is multifactorial may occur due to mutations in genes that belong to MAPK pathway. BRAFV600E is the most common mutation noted in ameloblastoma.⁶ The conventional variety includes solid/multicystic type accounting to 90% of all ameloblastoma. The average age for the presentation is 35 years, (range 4 to 92 years) mostly located in the third molar region of mandible. Conventional ameloblastoma manifests slow painless expansion of variable sizes that range from 1–16 cm. As the lesion

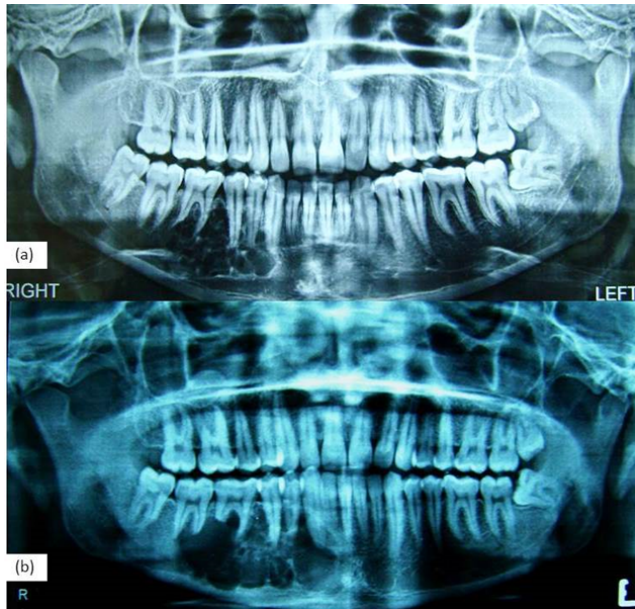


Figure 2: (a) OPG taken 1 year apart showing a well-defined multilocular radiolucency with corticated margins involving the right body of the mandible; (b) with expansion of the bony destruction and evident involvement of 47 and root resorption of 46

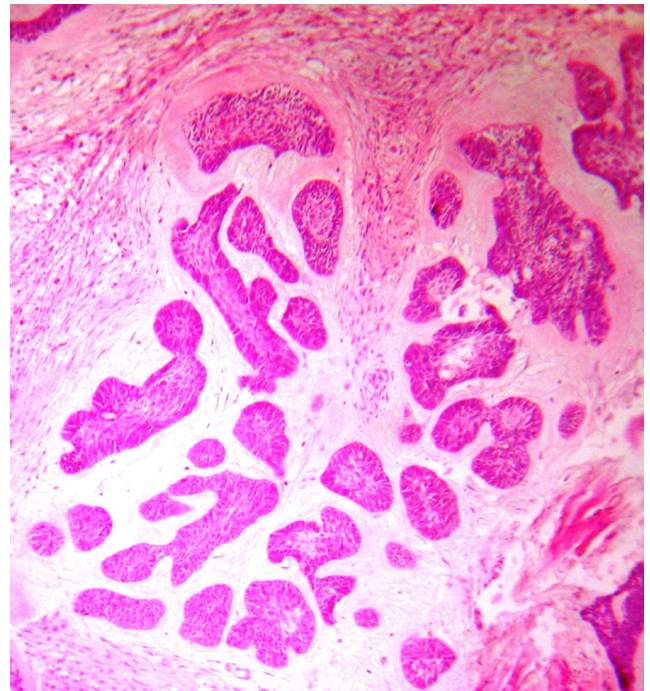


Figure 4: Histopathology showing epithelial cells arranged in small islands of peripheral layer of cuboidal or columnar cells with reversely polarized nucleus surrounding the central stellate reticulum like cells

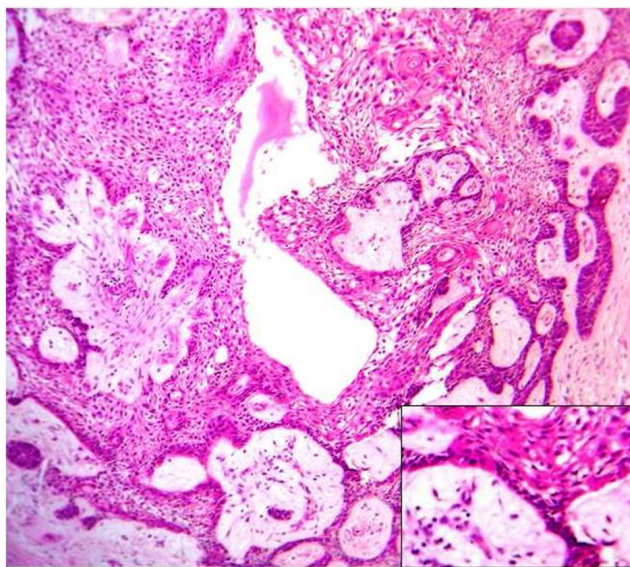


Figure 3: Histopathology showing epithelial cells are arranged in interconnecting strands with cuboidal or columnar basal cells exhibiting hyperchromatic nuclei and central stellate reticulum-like cells with budding growth pattern (Inset: Area showing flattened basal cells arranged in double row)

progresses it may show facial deformity. At first visit of the patient, he did not undergo any treatment and reported back after 1 year with a larger lesion and altered sensation of the regional teeth with root resorption of 46 and expansive osteolysis. Radiographically, a corticated multilocular radiolucency is common similar to present case however smaller lesions may show unilocular appearance.^{7,8}

Histologically, solid ameloblastoma shows the presence of epithelial odontogenic cells arranged either in discrete island or cord like masses that exhibits network of interconnecting strands of cells. Peripheral tall columnar cells with polarized nuclei appear like pre ameloblast surrounds the polyhedral, loosely arranged cells resembling stellate reticulum are observed to be embedded in a mature, connective tissue stroma. In 1970, V and G criteria was introduced to be used as a baseline to confirm the diagnosis of Ameloblastoma. It included 3 main salient features to be present including palisading columnar cells with hyperchromatic nucleus along with reversal of polarity and cytoplasmic vacuolization.³ However, it was later realized that not all histological types of ameloblastoma fulfill the strict criteria laid by V and G. In the current case, presence of double layered packed columnar cells appeared morphologically as flattened basal cells. Though the nucleus was hyperchromatic but nuclear palisading with reverse polarization and subnuclear vacuolization appears to be inconspicuous.

Reichart et al. mentioned that usually the solid tumor shows any one pattern but it is not unusual to observe both pattern in the same lesion. In the present case, follicular and plexiform patterns both were observed with odontogenic cells showing plexiform arrangement predominantly. Cystic degeneration is observed in both types, follicular variety leads to microcyst formation within the islands and in plexiform variety cystic changes are observed due to stromal degeneration. Despite its benign course, recurrence rate is almost 60% for solid ameloblastoma. Therefore, it is vital to examine primary or recurrent state of neoplasm and anatomical location with long term follow up following treatment.^{9,10}

4. Conclusion

Given the biologic behavior of ameloblastoma, the potential for clinical, radiographic and histopathological confusions to differentiate ameloblastoma from odontogenic cysts, and other odontogenic tumors is very likely to occur, where in V and G criteria can be considered useful in differential diagnosis. Complete reliability on V and G criteria must be done with vigilance as histopathological subtypes of ameloblastoma may not show all features of the gold standard criteria.

5. Source of Funding

None.

6. Conflict of Interest

None.

References

1. Adyanthaya S, Begum S, Devasia J, Sasikumar R, Smitha T, Abdulla R. Revisiting Vickers and Gorlin criteria in histopathological subtypes

- of ameloblastoma. *J Oral Maxillofac Pathol.* 2023;27:455–60.
2. Ragunathan YT, Kumar SK, Janardhanam D, Ravi A, Santhanam V, Ramdas MN. Prevalence and Epidemiological Profile of Ameloblastoma in India: A Systematic Review and Meta-Analysis. *Asian Pac J Cancer Prev.* 2022;23(11):3601–10.
3. Vickers RA, Gorlin RJ. Ameloblastoma: Delineation of early histopathologic features of neoplasia. *Cancer.* 1970;3(3):699–710.
4. Gardner DG. Some current concepts on the pathology of ameloblastomas. *Oral Surg Oral Med Oral Pathol Oral Radiol Endod.* 1996;82(6):660–9.
5. Dhanuthai K, Chantarangsu S, Rojanawatsirivej S. Ameloblastoma: a multicentric study. *Oral Surg Oral Med Oral Pathol Oral Radiol.* 2012;113:782–8.
6. Wright JM, Tekkesin M. Odontogenic tumors: where are we in 2017? *J Istanbul Univ Fac Dent.* 2017;51(3):10–30.
7. Kreppel M, Zöllner J. Ameloblastoma-Clinical, radiological, and therapeutic findings. *Oral Dis.* 2018;24(1-2):63–6.
8. Suma MS, Sundaresk KJ, Shruthy R, Mallikarjuna R. Ameloblastoma: an aggressive lesion of the mandible. *BMJ Case Rep.* 2013;2013:200483.
9. Reichart PA, Philipsen HP. Odontogenic Tumors and Allied Lesions. USA: Quintessence Pub; 2004. p. 189–97.
10. Hendra FN, Cann EMV, Helder MN, Ruslin M, Visscher JGD, Forouzanfar T. Global incidence and profile of ameloblastoma: A systematic review and meta-analysis. *Oral Dis.* 2020;26(1):12–21.

Author biography

Cheshta Walia, Assistant Professor  <https://orcid.org/0000-0002-5264-9771>

Amer Adel Al Rashidi, 3rd Year BDS Student

Sumaiya Waseem Akhtar Mohammed, 3rd Year BDS Student

Sudip Roy, Assistant Professor

Cite this article: Walia C, Al Rashidi AA, Mohammed SWA, Roy S. Ameloblastoma: An aggressive odontogenic neoplasm with altered vickers and gorlin criteria. *J Oral Med, Oral Surg, Oral Pathol, Oral Radiol* 2024;10(2):145-148.