



Content available at: <https://www.ipinnovative.com/open-access-journals>

Journal of Oral Medicine, Oral Surgery, Oral Pathology and Oral Radiology

Journal homepage: www.joooo.org



Original Research Article

Computer-assisted morphometric analysis of the relationship between the coronoid and condylar processes of the mandible

Lakshmi Rathan A C^{1*}, Devanshu Sinha², Sapna D P Somani³,
Vivek Narayanan¹, Divya V C⁴

¹Dept. of Oral and Maxillofacial Surgery, SRM Kattankulathur Dental College & Hospital, SRM Institute of Science & Technology, Tamil Nadu, India

²Dept. of Oral and Maxillofacial Surgery, Awadh Dental College and Hospital, Jamshedpur, India

³HCG ICS Khubchandani Hospital, Mumbai, Maharashtra, India

⁴Dept. of Oral Medicine and Radiology, SRM Kattankulathur Dental College & Hospital, SRM Institute of Science and Technology, Tamil Nadu, India



ARTICLE INFO

Article history:

Received 03-09-2024

Accepted 14-09-2024

Available online 15-10-2024

Keywords:

Coronoid process

Condyle

Morphometric analysis

Forensic odontology

Anthropology

TMJ

ABSTRACT

Background: The mandible is the most durable and only movable bone that constitutes the lower one-third of the face. The mandibular condyle and coronoid processes are two anatomical structures located in the superior portion of the ramus of the mandible. Morphometric understanding of these structures is key to the diagnosis of various disorders associated with the temporomandibular region. It also aids in devising a plan for the management of such disorders.

Purpose: The purpose of this study is to evaluate the anatomical correlation between the condyle and coronoid of the mandible.

Materials and Methods: This retrospective study was conducted by obtaining 100 high-resolution computed tomography images from departmental archived records between 2018 and 2024. After acquisition, these images were incorporated into MIMICS Materialize software to create stereolithography models, and morphometric analysis was carried out.

Results: Out of 100 HRCT data obtained, 87 were male and 13 were female. There is a statistically significant difference in length and angulation of the coronoid and condyle on both sides. The condyle length for males was (4 ± 5.5 mm) higher than the condyle length of females on both sides. However, the coronoid length of males and females varies in a range of 0.5-2mm on both sides of the mandible.

Conclusion: Understanding the morphological variation of mandibular condylar and coronoid processes aids in various fields of medicine like forensics, anthropology, and reconstructive maxillofacial surgery. Our study inference will aid surgeons in planning coronoid grafts for condylar reconstruction as well as other maxillofacial reconstructions. Additionally, it helps in forensic odontology to determine a person's age and gender.

This is an Open Access (OA) journal, and articles are distributed under the terms of the [Creative Commons Attribution-NonCommercial-ShareAlike 4.0 License](https://creativecommons.org/licenses/by-nc-sa/4.0/), which allows others to remix, tweak, and build upon the work non-commercially, as long as appropriate credit is given and the new creations are licensed under the identical terms.

For reprints contact: reprint@ipinnovative.com

1. Introduction

The mandible is the most durable and only movable bone that constitutes the lower one-third of the face.¹ It exhibits a

higher degree of sexual dimorphism.² It has a curved body that is connected to the ramus on either side by a mandibular angle.³ The mandibular condyle and coronoid processes are two anatomical structures located in the superior portion of the ramus of the mandible. Both of these structures are separated by a groove called a mandibular notch.⁴⁻⁷

* Corresponding author.

E-mail address: lakshmir5@srmist.edu.in (L. Rathan A C).

The anterior portion of the ramus is formed by the triangular eminence known as the coronoid process. It serves as the point of attachment for the temporalis muscle, which elevates the jaw.⁷ The condyle is a broad and wide projection forming the posterior limit of the ramus. It articulates with the glenoid fossa of the temporal bone to form the temporomandibular joint (TMJ).⁸

The bone morphology of these structures is predominantly influenced by muscle attachments and their functions.⁹ The other factors that also have an impact on the morphology are growth, dietary habits, hormones, genetic constitution, etc.¹⁰ Morphometric understanding of these structures is key to the diagnosis of various disorders associated with the temporomandibular region. It also aids in devising a plan for the management of such disorders. In recent times, the coronoid process has been utilized as an autogenous free graft for TMJ reconstruction.¹¹ In 2014, Tapas reported that the coronoid process is a suitable donor site for autologous bone grafting due to its biocompatibility and shorter operating time for harvesting.¹²

Numerous research has been documented in the literature that utilized dry mandibular skulls to study the dimensions and morphology of the coronoid and condyle processes.^{3,13,14} This assisted in identifying an individual's age, sex, and gender as well as aid in anthropological identification.¹⁵ Over the past decades, various studies have been conducted using orthopantomography (OPG) and computed tomography (CT) to analyze the morphometry and correlation between these two structures.^{1,10,16} In 2013, Stopa reported the condylar coronoid index to assess coronoid hyperplasia using CT images.¹⁷ However, there is no study in the literature that can determine the linear measurements and angulation of these structures to the mandibular notch.

The purpose of this study is to evaluate the anatomical correlation between the condyle and coronoid of the mandible. The secondary objective is to provide linear measurement and angulation of the coronoid and condylar processes to those of the sigmoid notch.

2. Materials and Methods

100 high-resolution computed tomography (HRCT) DICOM (Digital Imaging and Communication in Medicine) images were obtained from department archived data in order to conduct this retrospective analysis. The study had been approved by the institutional ethical committee (IEC No. 3054/IEC/2021). The data were obtained by reviewing clinical case record sheets and imaging records between 2018 and 2024 in department of Oral and Maxillofacial surgery, SRM Kattankulathur Dental College and Hospital. Demographic information such as age, gender, and high-resolution computed tomography (HRCT) images were included. Clinical records lacking HRCT imaging or HRCT of any anomalies related to the mandible, as well as records

from patients who were older than 80 years or younger than 18 years, had been excluded in the study.

All the HRCT scans were taken in a G-optima 128-slice machine by a single radiologist specializing in oral and maxillofacial radiology. During acquisition, the patient was in a natural head position and gently biting into a centric relation, with the lips in a relaxed position. All the images were obtained in 1mm-thick DICOM (Digital Imaging and Communications in Medicine) format.

After acquisition, these images were incorporated into the MIMICS Materialize software. The mandibular portion in each segment was masked in order to generate virtual stereolithography (STL) models. These STL models were incorporated into 3-Matic software for volumetric measurement. Two separate oral and maxillofacial surgeons with extensive training in software programming performed all of the morphometric analysis.

For all the mandible STL models, four reliable points were marked. This includes the tip of the coronoid process, the tip of the condylar process, the deepest point of the sigmoid notch, and gonion. After marking reliable points, the mandibular plane along the lower border of the mandible, the anterior ramus, and the posterior ramus plane of the mandible were drawn. A sigmoid plane was established by drawing a line perpendicular to the anterior and posterior ramus planes, crossing the deepest point in the sigmoid notch as described in Figure 1. The parameters evaluated were

1. Length of coronoid process = line X (from tip of coronoid to sigmoid plane)
2. Length of condylar process = line Y (from tip of condyle to sigmoid plane)
3. Angulation of coronoid = α (line X to sigmoid plane)
4. Angulation of condyle = β (line Y to sigmoid plane)

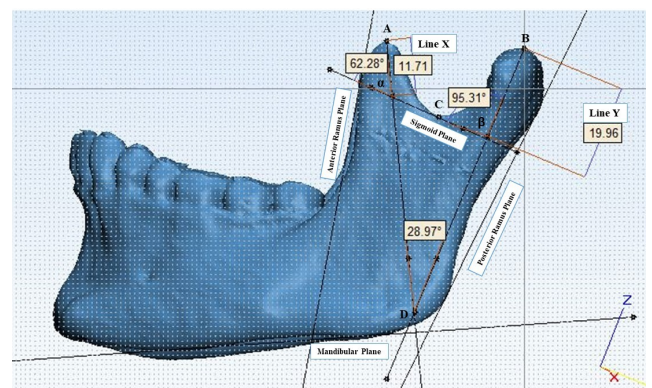


Figure 1: Morphometric measurements

2.1. Statistical analysis

The statistical analysis was performed with SPSS version 20.0. The means of condylar length and angle were compared to the coronoid length and angle for the left and right sides, respectively, using the Wilcoxon signed rank test. The means of coronoid length, coronoid angle, condylar length, and coronoid angle were compared with the gender on the left and right sides, respectively, using the Mann Whitney U test. The means of coronoid length, coronoid angle, condylar length, and coronoid angle were compared with the age groups on the left and right sides, respectively, using the Kruskal-Wallis’s test. The use of kappa analysis helped to prevent disputes or conflicts amongst examiners. On a nominal scale, the grades of agreement between two raters were evaluated using Cohen’s kappa coefficient. In order to minimize interobserver error, interrater and inter-rater reliability were evaluated.

3. Results

Out of 100 HRCT data obtained, 87 were male and 13 were female, with a mean age of 49 years. On both the left and right sides, there is a statistically significant difference ($p < 0.005$) between the length of the coronoid and the length of the condyle. On the right side, the average length of the condyle was 17.57 ± 5.22 mm, and on the left side, it was 17.81 ± 6.09 mm. The mean coronoid length observed on the right side was 15.53 ± 8.07 mm, while the average length observed on the left side was 14.61 ± 5.48 mm.

There is a statistically significant difference between condyle angle and coronoid angle on both the left and right sides, with a p value ≤ 0.005 . It was found that the condyle’s angulation to the sigmoid line was $79.75 \pm 16.61^\circ$ on the left side and $78.76 \pm 16.15^\circ$ on the right. Comparably, the coronoid’s angulation to the sigmoid line was $64.25 \pm 15.70^\circ$ on the left side and $63.90 \pm 16.97^\circ$ on the right.

There is no statistically significant difference present in the condyle length, coronoid length, condyle angle, or coronoid angle on both sides with respect to age and gender, respectively. The condyle length for males was 4 ± 5.5 mm higher than the condyle length of females on both sides. However, the coronoid length of males and females varies in a range of 0.5-2mm on both sides of the mandible.

After evaluation, the intrarater and interrater reliability values were determined to be 0.86 and 0.82, respectively. The two examiners showed a high degree of agreement, based on the kappa analysis rating.

4. Discussion

Remodelling is a term used to describe a physiological process that adapts and modifies the structure.^{18,19} The morphological variety of the anatomic structure is influenced by various factors such as developmental discrepancies, genetic determinants, and functional

Table 1: Comparison between the means of condylar length and angle with the coronoid length and angle on both sides

Parameters -	N	Mean	Std. Deviation	p-value
Left side				
Condylar Length	100	17.81	6.09	0.001*
Coronoid Length	100	14.61	5.48	
Condylar Angle	100	79.75	16.61	0.000*
Coronoid Angle	100	64.25	15.70	
Parameters -				
Right side				
Condylar Length	100	17.57	5.22	0.014*
Coronoid Length	100	15.53	8.07	
Condylar Angle	100	78.76	16.15	0.002*
Coronoid Angle	100	63.9	16.965	

N- Frequency, *Significant

Table 2: Comparison between the means of right-side condylar length, condylar angle, coronoid length & coronoid angle with the gender

Parameters –	Gender	N	Mean	Std. Deviation	p-value
Right side					
Condylar Length	Male	87	17.96	5.08	0.059
	Female	13	14.92	5.54	
Condylar Angle	Male	87	79.28	15.73	0.268
	Female	13	75.3	19.14	
Coronoid Length	Male	87	15.87	8.47	0.257
	Female	13	13.23	4.20	
Coronoid Angle	Male	87	63.72	16.99	0.947
	Female	13	65.09	17.41	

N- Frequency, *Significant

variation arising during the growth process.^{10,13} Remodelling of the mandible frequently occurs in tandem with changes in the distribution and direction of stress.^{18,19}

Based on our study, males have longer condyles than females. However, the coronoid’s length does not alter significantly. This is in line with the results published in 2023 by Yamashita et al.¹ Hormonal fluctuations together with hereditary factors are the basis of this sexual dimorphism. The female hormone oestrogen has been documented in literature to be a major factor in bone remodelling. Similarly, testosterone also affects the remodelling of the bones.^{2,20}

In relation to the age factor, our findings have also shown several intriguing remodelling processes. As one gets older, the condylar process gets shorter and less angular. On the other hand, as people age, their coronoid process’s length and angulation increases. There have been various theories that explain the elongation of the coronoid process, which includes temporalis hyperactivity, dysfunction of the temporomandibular joint caused by chronic disc displacement, dental causes like the guidance of occlusion, variation in condylar inclination, and other factors like hormonal stimulus, nutrition, and genetic inheritance.^{10,13} In 2021, Jiang et al. conducted a retrospective cohort

Table 3: Comparison between the means of left-side condylar length, condylar angle, coronoid length & coronoid angle with the gender

Parameters – Left side	Gender	N	Mean	Std. Deviation	p-value
Condylar Length	Male	87	18.29	6.10	0.051*
	Female	13	14.61	5.15	
Condylar Angle	Male	87	80.33	16.27	0.111
	Female	13	75.86	18.99	
Coronoid Length	Male	87	14.69	5.55	0.890
	Female	13	14.06	5.22	
Coronoid Angle	Male	87	64.27	15.60	0.626
	Female	13	64.13	17.08	

N- Frequency, *Significant

Table 4: Comparison between the means of left-side condylar length, condylar angle, coronoid length & coronoid angle with the age groups

Parameters – Right side	Age groups	N	Mean	Std. Deviation	p-value
Condylar Length	< 20 years	5	21.5100	4.38763	0.396
	21 to 40 years	72	17.6217	4.94254	
	41 to 60 years	18	16.9828	5.88722	
	61 to 80 years	5	14.9380	6.60422	
Condylar Angle	< 20 years	5	84.02	13.67	0.150
	21 to 40 years	72	80.34	15.48	
	41 to 60 years	18	74.33	17.02	
	61 to 80 years	5	66.8	21.09	
Coronoid Length	< 20 years	5	18.1000	16.65270	0.568
	21 to 40 years	72	14.8538	6.17969	
	41 to 60 years	18	14.9650	4.49653	
	61 to 80 years	5	24.6740	21.22366	
Coronoid Angle	< 20 years	5	60.9960	16.54119	0.715
	21 to 40 years	72	62.8910	15.28681	
	41 to 60 years	18	68.5206	18.66427	
	61 to 80 years	5	64.6540	33.10871	

N- Frequency, *Significant

Table 5: Comparison between the means of left-side condylar length, condylar angle, coronoid length & coronoid angle with the age groups

Parameters – Left side	Age groups	N	Mean	Std. Deviation	p-value
Condylar Length	< 20 years	5	21.5800	4.60042	0.235
	21 to 40 years	72	17.9112	6.25328	
	41 to 60 years	18	17.2494	6.01743	
	61 to 80 years	5	14.6080	4.20620	
Condylar Angle	< 20 years	5	83.2200	13.26901	0.225
	21 to 40 years	72	81.4653	15.95880	
	41 to 60 years	18	75.0289	18.64773	
	61 to 80 years	5	68.6160	18.20009	
Coronoid Length	< 20 years	5	12.3300	5.40198	0.780
	21 to 40 years	72	14.7488	5.72464	
	41 to 60 years	18	14.5889	4.95824	
	61 to 80 years	5	14.9480	4.70121	
Coronoid Angle	< 20 years	5	60.2140	14.74081	0.267
	21 to 40 years	72	62.7947	14.94803	
	41 to 60 years	18	68.1339	17.71271	
	61 to 80 years	5	75.3180	17.55617	

N- Frequency, *Significant

study to assess the regrowth of the coronoid process following coronoidectomies in 57 cases. In a total of 96 coronoidectomies, he found 74 coronoid processes (77.1%) showed complete (n = 44, 45.8%), non-union (n = 19, 19.8%), or partial (n = 11, 11.5%) regrowth, whereas no evidence of regeneration was found in 22 sites.²¹ The most frequent cause of condylar remodelling is stress and functional over load generated by the masticatory muscles.²² Milam et al. (1998) postulated that condylar resorption is caused by free radicals produced in the TMJ.²³

In forensic medicine and anthropology, the mandible is one of the bones that is used to determine the age and gender of an individual, as well as racial determination.^{5,9,15} Our study inference will contribute to determining the gender and age of the individual by analyzing the length and angulation of the condyle and coronoid processes.

Understanding the complex morphology of the TMJ region is essential in the field of oral and maxillofacial surgery. This aids surgeons in the proper planning and management of TMJ abnormalities. It also aids in customizing prostheses for individuals who require total joint replacement. Currently, the coronoid process is utilized as a free graft for all types of reconstructive maxillofacial surgical procedures, such as orbital floor reconstruction, paranasal augmentation, TMJ ankylosis, trauma, tumors, facial paralysis, alveolar defects, non-union fracture of the mandible, and osseous defect reconstruction.¹¹ In 2008, Zhu et al. reported a study in which they utilized the coronoid process as a free bone graft following gap arthroplasty in a TMJ ankylosis patient.²⁴ Similarly, in 2017, Yang et al. conducted the study to assess any disturbance in the mandibular growth of the children with TMJ ankylosis who had undergone reconstruction of the condyle with an autologous coronoid graft. He reported that the rate of growth of the mandible was not affected.²⁵ The limitations of our study are a smaller sample size and a lack of a diverse population.

5. Conclusion

To conclude, understanding the morphological variation of the mandibular ramus region, especially condylar and coronoid processes, aids in various fields of medicine like forensics and anthropology, reconstructive maxillofacial surgery, etc. In recent times, with advanced imaging technology and the advent of various simulation software, harvesting coronoid grafts for various maxillofacial defects has become much easier. Furthermore, our study inference will aid surgeons in planning coronoid grafts for condylar reconstruction as well as other maxillofacial reconstructions. Additionally, it helps in forensic odontology to determine a person's age and gender.

6. Source of Funding

None.

7. Conflict of Interest


None.

References


1. Yamashita FC, Yamashita AL, Romanichen IM, Tolentino ED, Chicarelli M, Iwaki LC. Three-dimensional evaluation of mandibular condyle and coronoid process according to sex, age, and skeletal deformities. *CRANIO*. 2023;41(1):26–31.
2. Gomes AF, Nejaim Y, Brasil DM, Groppo FC, Caria PH, Neto FH. Assessment of volume and height of the coronoid process in patients with different facial types and skeletal classes: a cone-beam computed tomography study. *J Oral Maxillofac Surg*. 2015;73(7):1395.
3. Jadhav DS, Shashank BV. Variations in the shapes of the coronoid process of adult human mandible in Marathwada and Western Maharashtra region. *Int J Anat*. 2017;4(2):17–9.
4. Sanmugam K. A study of morphological variation of lingula and coronoid process of adult human dry mandibles. *J Pharm Sci Res*. 2015;7(11):1017.
5. Pradhan S, Bara DP, Patra S, Nayak S, Mohapatra C. Anatomical study of various shapes of mandibular coronoid process in relation to gender & age. *IOSR J Dent Med Sci*. 2014;13(8):9–14.
6. Ishwarkumar S, Pillay P, Gama BD, Satyapal KS. Osteometric and radiological study of the mandibular notch. *Int J Morphol*. 2019;37(2):491–7.
7. Tassoker M, Kabakci AD, Akin D, Sener S. Evaluation of mandibular notch, coronoid process, and mandibular condyle configurations with cone beam computed tomography. *Biomed Res*. 2017;28:8327–35.
8. Wangai L, Mandela P, Butt F, Ongeti K. Morphology of the mandibular condyle in a Kenyan population. *Anat J Afr*. 2013;2(1):71–9.
9. Manoj M, Mathew L, Natarajan S, Yellapurkar S, Shetty S, Denny C, et al. Morphometric analysis of mandibular coronoid, condyle and sigmoid shape using panoramic view for personal identification in south Indian population. *J Clin Imaging Sci*. 2022;12:25.
10. Al-Saedi AI, Riad AL, Al-Jasim N, Bahaa AL. A panoramic study of the morphology of mandibular condyle in a sample of population from Basrah city. *Int J Morphol*. 2020;38(6):1707–2.
11. Sabhlok S, Waknis PP, Gadre KS. Applications of coronoid process as a bone graft in maxillofacial surgery. *J Craniofac Surg*. 2014;25(2):577–80.
12. Yang X, Hu J, Yin G, Hu J, Luo E. Computer-assisted condylar reconstruction in bilateral ankylosis of the temporomandibular joint using autogenous coronoid process. *Br J Oral Maxillofac Surg*. 2011;49(8):612–7.
13. Tapas S. Morphological variations of coronoid process in dry adult human mandibles. *Indian J Basic Appl Med Res*. 2014;3(2):401–5.
14. Prajapati VP, Malukar O, Nagar SK. Variations in the morphological appearance of the coronoid process of human mandible. *Natl J Med Res*. 2011;1(2):64–6.
15. Sahithi D, Reddy S, Teja DD, Koneru J, Praveen KN, Sruthi R. Reveal the concealed-Morphological variations of the coronoid process, condyle and sigmoid notch in personal identification. *Egypt J Forensic Sci*. 2016;6(2):108–13.
16. Jawahar A, Maragathavalli G. Analysis of Condylar Morphological Variations Using Digital Panoramic Radiographs-A Retrospective Study. *Indian J Public Health Res Dev*. 2019;10(11):3450.
17. Stopa Z, Wanyura H, Kowalczyk P. Coronoid-condylar index in assessing of mandibular coronoid hyperplasia. Preliminary result. *Adv Med Sci*. 2013;58(2):429–33.
18. Alexiou KE, Stamatakis HC, Tsiklakis K. Evaluation of the severity of temporomandibular joint osteoarthritic changes related to age using cone beam computed tomography. *Dentomaxillofac Radiol*. 2009;38(3):141–7.
19. Weijs WA, Hillen B. Correlations between the cross-sectional area of the jaw muscles and craniofacial size and shape. *Am J Phys Anthropol*.


- 1986;70(4):423–31.
20. Nakawaki T, Yamaguchi T, Isa M, Kawaguchi A, Tomita D, Hikita Y, et al. Growth hormone receptor gene variant and three-dimensional mandibular morphology. *Angle Orthod.* 2017;87(1):68–73.
 21. Jiang Z, Long X, Ke J, Cai H, Fang W, Meng Q. The Regrowth of Mandibular Coronoid Process After Coronoidectomy: A Retrospective Analysis of 57 Cases. *J Oral Maxillofac Surg.* 2022;80(1):151–61.
 22. Gunson MJ, Arnett GW, Milam SB. Pathophysiology and pharmacologic control of osseous mandibular condylar resorption. *J Oral Maxillofac Surg.* 2012;70(8):1918–34.
 23. Milam SB, Zardeneta G, Schmitz JP. Oxidative stress and degenerative temporomandibular joint disease: a proposed hypothesis. *J Oral Maxillofac Surg.* 1998;56(2):214–23.
 24. Zhu SS, Hu J, Li J, Luo E, Liang X, Feng G. Free grafting of autogenous coronoid process for condylar reconstruction in patients with temporomandibular joint ankylosis. *Oral Surg Oral Med Oral Pathol Oral Radiol Endod.* 2008;106(5):662–7.
 25. Yang YT, Li YF, Jiang N, Bi RY, Zhu SS. Grafts of autogenous coronoid process to reconstruct the mandibular condyle in children with unilateral ankylosis of the temporomandibular joint: long-term effects on mandibular growth. *Br J Oral Maxillofac Surg.* 2018;56(2):107–12.


Author biography

Lakshmi Rathan A C, Assistant Professor  <https://orcid.org/0000-0001-6289-399X>

Devanshu Sinha, Assistant Professor

Sapna D P Somani, Fellow, Head and Neck Surgical Oncology  <https://orcid.org/0000-0002-1473-3032>

Vivek Narayanan, Professor and Head  <https://orcid.org/0000-0002-1454-3984>

Divya V C, Associate Professor  <https://orcid.org/0000-0001-7042-6435>

Cite this article: Rathan A C L, Sinha D, Somani SDP, Narayanan V, Divya V C. Computer-assisted morphometric analysis of the relationship between the coronoid and condylar processes of the mandible. *J Oral Med, Oral Surg, Oral Pathol, Oral Radiol* 2024;10(3):191-196.