



Content available at: <https://www.ipinnovative.com/open-access-journals>

Journal of Oral Medicine, Oral Surgery, Oral Pathology and Oral Radiology

Journal homepage: www.joooo.org



Case Report

Osteomyelitis of maxilla: A rare entity

Pradeep Christopher¹, Minu Kumari^{1*}

¹Thai Moogambigai Dental College and Hospital, Chennai, Tamil Nadu, India



ARTICLE INFO

Article history:

Received 20-07-2024

Accepted 21-08-2024

Available online 15-10-2024

Keywords:

Osteomyelitis

Maxilla

Bone

Inflammation

ABSTRACT

The term "osteomyelitis" refers to inflammation of the bone marrow as well as the periosteum, cortical, and cancellous regions of the bone. Osteomyelitis of the jaws is more common in developing countries, and treatment can be difficult and time-consuming. Osteomyelitis occurs more frequently in the mandible than in the maxilla because of the latter's lower likelihood of infection due to its large collateral blood flow, thin cortical bones, and scattered bone marrow. To treat this condition, sequestrectomy, debridement of the necrosed bone, and extraction of the affected teeth, along with antibiotic therapy and adjuvant therapy, are needed. Here, we present a rare case of osteomyelitis of the maxilla in an elderly male. The patient was treated with sequestrectomy and no recurrence was observed during the follow up.

This is an Open Access (OA) journal, and articles are distributed under the terms of the [Creative Commons Attribution-NonCommercial-ShareAlike 4.0 License](https://creativecommons.org/licenses/by-nc-sa/4.0/), which allows others to remix, tweak, and build upon the work non-commercially, as long as appropriate credit is given and the new creations are licensed under the identical terms.

For reprints contact: reprint@ipinnovative.com

1. Introduction

Osteomyelitis describes an inflammation of the entire bone, including the bone marrow and the periosteum, cortical, and cancellous parts of the bone.¹ A common infectious cause of osteomyelitis is inflammation of the bones. In 1847, Rees described maxillary osteomyelitis.² The mandible is more likely than the maxilla to develop osteomyelitis because of the latter's lower risk of infection because of its wide collateral blood flow, thin cortical bones, and dispersed bone marrow.^{3,4} Osteomyelitis was rather common prior to the development of antibiotic therapy. It was an illness that might be fatal before the discovery of antibiotics; however, if handled effectively in the modern period, it can, resolve satisfactorily.⁵ Here, we report a rare case of an elderly patient with maxillary osteomyelitis.

2. Case Report

A 55 year old male patient reported to the Department of Oral and Maxillofacial Surgery, Thai Moogambigai Dental College and Hospital, Chennai, complaining of swelling for the past two weeks on the right side of his face. He had a history of slight pain which was dull in nature that got worsened on having food but relieved on medications. The patient visited the dental clinic 4 months prior for the same complaint, where he underwent uneventful extraction and root canal treatment in the upper right back tooth region along with antibiotic coverage and was prescribed medication on and off due to pain and swelling for a period of 4 months. There was no gross facial asymmetry visible during extraoral examination. Palpation revealed a slight tenderness over the right maxillary sinus region. Intra-oral examination revealed a lesion appearing as an exposed bony sequestrum and missing 14,15 (Figures 1 and 2).

On radiographical examination, IOPA revealed the extraction socket with respect to regions 14 and 15. OPG revealed radiopacity in the right maxillary sinus (Figure 3). Evident intertrabecular bone formation noted in relation

* Corresponding author.

E-mail address: nidhi07109125@gmail.com (M. Kumari).



Figure 1: (a-c): Extraoral clinical pictures of the patient

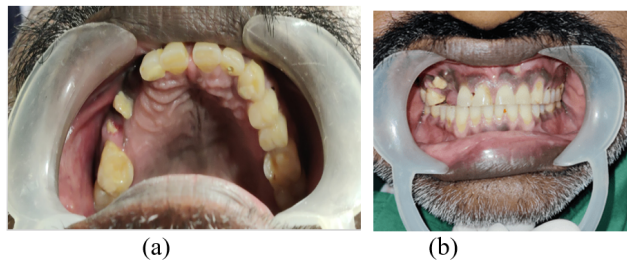


Figure 2: (a, b): Intraoral clinical pictures of the patient. The pictures shows lesion appearing as an exposed bony sequestrum

to the 14 and 15 extraction sockets. CT revealed bony destruction in the right maxillary sinus (Figure 4).

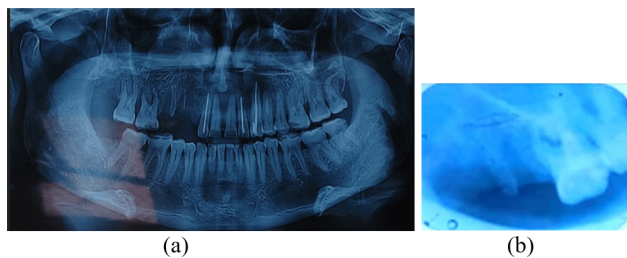


Figure 3: (a): OPG revealed radiopacity in the right maxillary sinus; **(b):** IOPA suggestive of extracted socket in 14 and 15 region

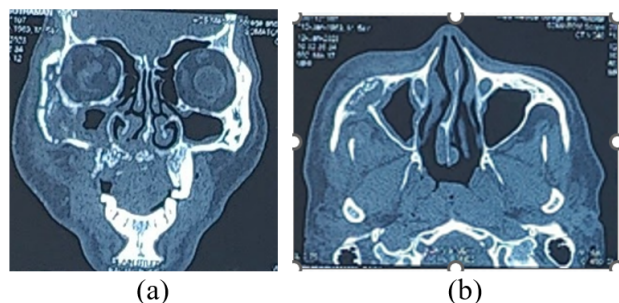


Figure 4: (a, b): CT images showing bony destruction in the right maxillary sinus

Surgical intervention was planned under local anaesthesia. The next day, patient underwent local anaesthesia and the extraction of 16, 17, and complete excision of sequestered bone were done (Figure 5). Complete curettage of the lesion was performed and wound toileting was done using betadine and regular saline. Roller gauze soaked with bismuth oxide paste was used to fill the cavity, with the end of the gauze left outside. 3-0 vicryl sutures were used to approximate the flaps. Regular dressing and irrigation was done and post operatively followed by inj. Clindamycin 600mg i.v. 6 hourly for 5 days and then clindamycin capsules 300mg 6 hourly for 7 days. Regular follow up showed satisfactory results (Figures 6 and 7).

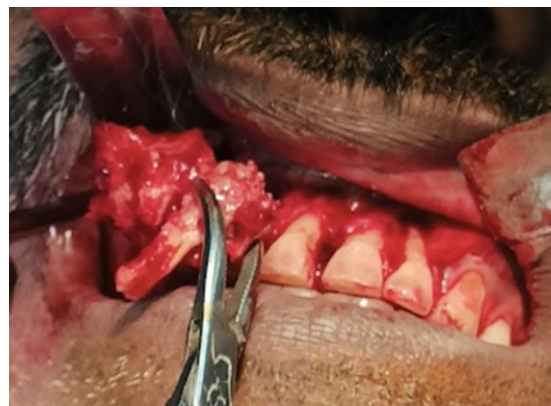

Figure 5: Complete sequestered bone removal was done along with extraction of 16, 17

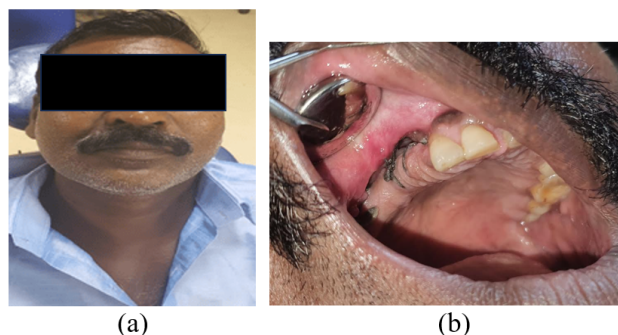


Figure 6: (a): Extraoral post-operative picture of the patient; **(b):** Intraoral post-operative picture of the patient

3. Discussion

The term "maxillary osteomyelitis" refers to osteomyelitis of the maxilla, which is an inflammation of the entire bone, including the periosteum, bone marrow, cortical and cancellous bones. This condition was life threatening prior to the development of antibiotic therapy.⁶⁻⁸ The British doctor Sir Benjamin Brodie wrote the first report

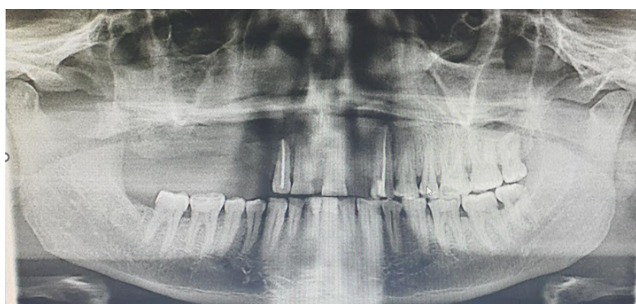

Figure 7: Post-operative OPG of the patient

on osteomyelitis in 1832.⁹ Osteomyelitis can be caused by bacterial infections, with common pathogens, including *Staphylococcus aureus*, *Streptococcus*, and anaerobic bacteria.¹⁰ Clinical features may include pain, swelling, redness, and warmth around the affected area of the face. Intraoral symptoms can manifest as gum swelling, tooth mobility, and purulent discharge. In our patient, pain and swelling over the hard palate were observed.

Clinical evaluation, imaging studies (CT scans, MRI), and sometimes dental X-rays are used to diagnose maxillary osteomyelitis. On panoramic radiographs, an irregular or moth-eaten appearance of the maxillary bone, and increased density in the affected area due to new bone formation as a response to infection and thinning or perforation of the cortical bone are also observed. CT provides more detailed and three-dimensional images than panoramic radiographs. The presence of lytic lesions or areas of bone destruction and the formation of sequestra within the affected bone are observed. MRI is effective in visualizing soft tissue involvement, including the presence of abscesses. Additionally, a combination of imaging techniques may be utilized to provide a comprehensive assessment of maxillary osteomyelitis.

Antibiotics are a crucial component of maxillary osteomyelitis treatment. In order to remove dead bone tissue and drain abscesses, surgery could be required, or address any underlying dental or sinus issues contributing to the infection. In our case, the patient was treated with a course of antibiotics combined with surgical intervention and regular follow up.

4. Conclusion

Maxillary osteomyelitis is rare condition linked to extensive antibiotic usage, prompt diagnosis, and treatment. With prompt and appropriate treatment, many cases of osteomyelitis can be successfully resolved. However, delays

in diagnosis or inadequate treatment may lead to chronic infections, bone damage, and complications. The severity of the illness, the patient's general condition, and the efficacy of the selected course of therapy are some of the variables that affect the prognosis.

5. Source of Funding

None.

6. Conflict of Interests

The authors declare that there are no conflicts of interest regarding the publication of this paper.

References

1. Topazian RG, Goldberg MH, Hupp JR. Oral and Maxillofacial Infections. 4th ed. Philadelphia: WB Saunders Company; 2002.
2. Mandrekar PN, Gavhane S, Fernandes TB, Dhupar A. A diagnostic dilemma in pediatric osteomyelitis: a case report. *J Korean Assoc Oral Maxillofac Surg.* 2022;48(2):117–21.
3. Pattnaik B, Padmavathi BN, Kumari M, Sharma SS. Osteomyelitis of maxilla: A rarity. *Ann Int Med Den Res.* 2017;3(3):7–10.
4. Manimaran K, Kannan PS, Kannan R. Osteomyelitis of maxilla bilateral involvement: a case report. *JIADS.* 2011;2(2):57–58.
5. Koorbusch GF, Fotos P, Goll KT. Retrospective assessment of osteomyelitis. Etiology, demographics, risk factors, and management in 35 cases. *Oral Surg Oral Med Oral Pathol.* 1992;74(2):149–54.
6. Harvey BR, Ephros H, Defalco RJ. Tetracycline bone labeling in surgical management of chronic osteomyelitis: a case report. *J Oral Maxillofac Surg.* 2004;62(6):752–4.
7. Eyrich GKH, Baltensperger MM, Bruder E, Graetz KW. Primary chronic osteomyelitis in childhood and adolescence: A retrospective analysis of 11 cases and review of the literature. *J Oral Maxillofac Surg.* 2003;61(5):561–73.
8. Neville BW, Damm DD, Allen CM, Bouquet JE. Oral and Maxillofacial pathology. Philadelphia: W.B. Saunders; 2002.
9. Harris MC, DeRosa DC, West PA. Subacute Osteomyelitis of the Pediatric Talus: A First Report of Brodie's Abscess from *Morganella morganii*. *Case Rep Orthop.* 2019;2019:7108047.
10. Gupta V, Singh I, Goyal S, Kumar M, Singh A, Dwivedi G. Osteomyelitis of maxilla - A rare presentation: Case report and review of literature. *Int J Otorhinolaryngol Head Neck Surg.* 2017;3(3):771–6.

Author biography

Pradeep Christopher, HOD

Minu Kumari, Post Graduate

Cite this article: Christopher P, Kumari M. Osteomyelitis of maxilla: A rare entity. *J Oral Med, Oral Surg, Oral Pathol, Oral Radiol* 2024;10(3):206-208.