

Lobular capillary haemangioma on gingiva: A case report

Shweta Thakare^{1,*}, Amit Mhapuskar², Santosh Jadhav³, Versha Rani Giroh⁴

^{1,4}PG Student, ²Professor & Head, ³Assistant Professor, Dept. of Oral Medicine & Radiology, Bharati Vidyapeeth Deemed University Dental College & Hospital, Pune

***Corresponding Author:**

Email: shwetathakare116@gmail.com

Abstract

Pyogenic granuloma is one of the inflammatory hyperplasias affecting the oral mucosa. It is common tumor-like growth of oral mucosa or skin that is considered to be non-neoplastic. The term pyogenic granuloma may be a misnomer because the lesion is unrelated to infection and it arises from local irritation or traumatic injury. It is not related to pus as its name suggests and histologically resembles to angiomatous lesion. It includes fibrous inflammatory dysplasia (fibroma, epulis fissuratum, pulp polyp), palatal papillary hyperplasia, giant cell granuloma and pregnancy epulis. Its occurrence in young female patients especially in second decade of life suggests that hormonal imbalance may play role in its pathogenesis. Clinically it appears as a lobulated, sessile or pedunculated, exophytic growth with surface color ranging from red to purple. Surgical excision is a line of treatment, while other treatment modalities includes Nd: YAG optical laser, electrodesiccation, intralesional injection of alcohol or steroids, sodium tetradecyl sulphate sclerotherapy.

Keywords: Inflammatory hyperplasia, Lobular capillary haemangioma, Pyogenic granuloma, Oral cavity.

Case Report

A 23years old female patient reported to the outpatient department of Oral Medicine and Radiology with a chief complaint of growth on lower front region of gingiva since last one month. The growth was painless but progressively increasing in size. Intraoral examination revealed a sessile, lobulated gingival overgrowth extending on the interdental papilla in between 32-33 region. The growth was about 1×0.7 cm in dimension and extending anterioposteriorly from middle half of cervical portion of crown of 32 to the anterior one third of crown of 33. The growth was reddish pink in colour and surface was smooth, soft in consistency and non-tender. There was minimal bleeding on provocation.(Fig. 1)

Medical history was not significant and also history of pregnancy was not reported. Radiographically, there were no visible abnormalities and the alveolar bone in the region of the growth appeared normal. Routine hemogram was found to be normal. Based on the above findings the growth was provisionally diagnosed as pyogenic granuloma. The differential diagnosis included peripheral ossifying fibroma, peripheral giant cell granuloma. The case was prepared for surgery on the basis of the clinical and radiographic evidence. Oral prophylaxis was completed. Excisional biopsy was performed under local anesthesia followed by curettage with patient's consent.(Fig. 2)

Microscopic examination of the incised specimen under 10X (Fig. 3) showed the hyperplastic parakeratinized epithelium. The underlying connective tissue showed collagen fibers interspersed with fibroblasts, plenty of inflammatory cell infiltration seen chiefly consisting of lymphocytes, plasma cells. Under 40X showed plenty of dilated and engorged blood vessels along with proliferating endothelial cells and

extravasated red blood corpuscle's.(Fig. 4) The above features were suggestive of lobular capillary haemangioma.

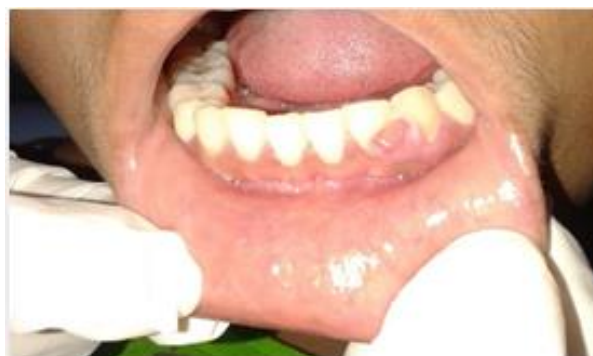

Fig. 1: Intraoral photo showing gingival overgrowth in relation to 32, 33 region

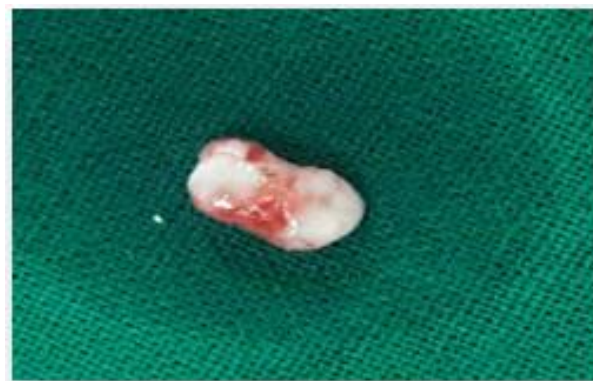

Fig. 2: Excised biopsy specimen

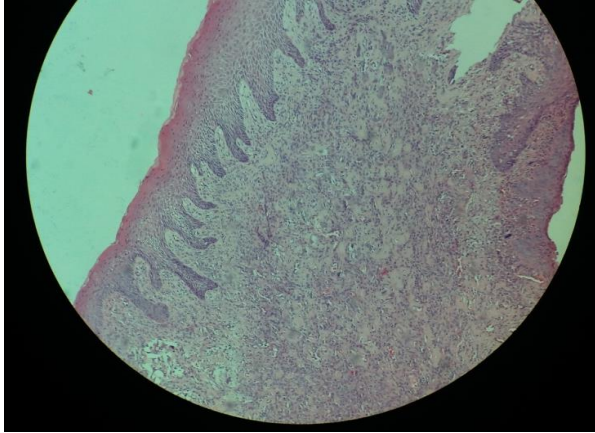


Fig. 3: Photomicrograph under 10X showing hyperplastic epithelium (red arrow), Parakeratinised epithelium (blue arrow), inflammatory cell infiltrate (yellow arrow), collagen fibres interspersed with fibroblast (black arrow)

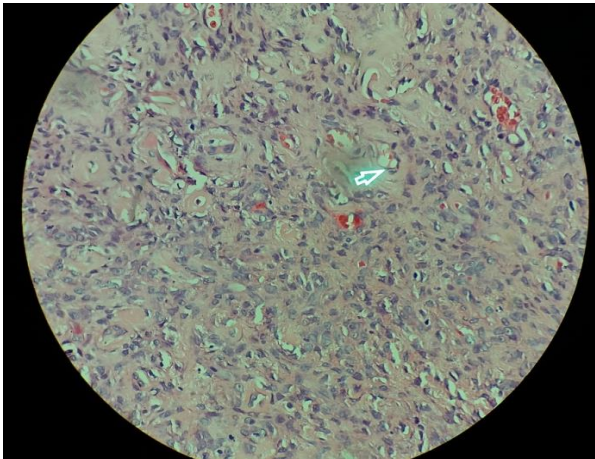


Fig. 4: Photomicrograph under 40X showing dilated and engorged blood vessels (green arrow), Proliferating endothelial cells (orange arrow)

Discussion

Pyogenic granuloma (PG) is known by a range of names and first given by Crocker as Hartzell's disease, lobular capillary haemangioma, tumor pyogenicum, tumor pediculatum benignum, 'pyogenic' benign vascular tumor and during pregnancy as granuloma gravidarum.⁽¹⁾ Depending on its rate of proliferation and vascularity, there are 2 histological variants of pyogenic granuloma called Lobular Capillary Haemangioma (LCH type) and Nonlobular Capillary Haemangioma (non-LCH type).⁽¹⁾ Incidence of lobular capillary haemangioma in man was initially delineated in 1897 by Poncet and Dor.⁽²⁾ Regezi et al. stated that lobulated capillary haemangioma is caused by a stimulant or injury due to calculus or foreign bodies inside the gingival crevice leading to exuberant proliferation of epithelial tissue and also routine tooth brushing habits causes continuous trauma to the epithelial tissue leading to irritation and formation of those lesions.⁽³⁾

There are number of causative factors for pyogenic granuloma such as release of endogenous substances and angiogenic factors caused disturbances within the affected area, trauma to deciduous teeth, aberrant tooth development, occlusal interferences.⁽⁴⁾

Lobular capillary haemangioma occur in young to adults, however more often encountered in females in their second decade because of the raised levels of sex hormones and progesterone.⁽⁵⁾ Bhaskar and Jacoway demonstrated the presence of gram positive and gram negative bacilli within the superficial areas of the ulcerated kind of pyogenic granuloma, instead of the non-ulcerated type suggesting that these organisms may be contaminants from the oral cavity. This most likely justifies the inclusion of the term "pyogenic" in PG.⁽⁶⁾ Oral pyogenic granuloma shows capillary growth inside a granulomatous mass instead of pyogenic organisms and pus, therefore the term pyogenic granuloma is a misnomer as name but it's not a granuloma in the real sense.⁽⁷⁾

Lobular capillary haemangioma of the oral mucosa appears as an elevated, smooth or exophytic, sessile or pedunculated growth lined with red hemorrhagic and compressible erythematous papules, lobulated and wart like growth showing ulcerations and lined by yellow fibrinous membrane. The colour varies from red, purplish to pink depending on the property of the expansion.⁽⁸⁾ Particularly the marginal gingiva is affected over the alveolar half. Besides the gingiva it is additionally located on the lips, tongue or buccal mucosa, most commonly on the anterior region than the posterior with the buccal surfaces being affected over the lingual surfaces.⁽⁹⁾ The dimensions varies from some millimeters to centimeters and it is typically slow growing, symptomless, painless growth, however it grows quickly.⁽¹⁰⁾

Surgical excision is the line of treatment for lobular capillary haemangioma. The various alternative treatment modalities including Nd: YAG optical laser, CO₂ optical laser, cryotherapy, electrodesiccation, sodium tetradeacyl sulfate sclerotherapy and use of intralesional steroids. Taira et al. have shown a recurrence rate in 16% of excised lesions. Incomplete excision, failure to get rid of etiologic factors or recurrent trauma contributes to recurrence of these lesions. Vilmann et al. stated the follow-up is necessary particularly in pyogenic granuloma of the gingiva because of its higher recurrence rate.⁽¹¹⁾

The present case was followed up for a period of three months and no recurrence was observed.

Conclusion

Pyogenic granuloma is a common non-neoplastic lesion of the oral mucosa, especially on the gingiva. The term pyogenic granuloma is frequently used which is not associated with pus and histologically it resembles angiomatous lesion rather than granulomatous lesion

indicating that the term “pyogenic granuloma” is a misnomer.

References

1. Chaudhari DRS, Hebbale DM, Hiremutt D, Kulkarni D. Lobular Capillary Haemangioma - A Series of Three Cases. *SEAJCRR* 2015;4(2):1426-1436.
2. Gomes SR, Shakir QJ, Thaker PV, Tavadia JK. Pyogenic granuloma of the gingiva: A misnomer?- a case report and review of literature. *J Indian Soc Periodontol* 2013;17:514-519.
3. Punde PA, Malik SA, Malik NA, Parkar S. Idiopathic huge pyogenic granuloma in young and old: An unusually large lesion in two cases. *J Oral Maxillofac Pathol.* 2013;17(3):463-466.
4. Kamal R, Dahiya P, Puri A. Oral pyogenic granuloma: Various concepts of etiopathogenesis. *J Oral Maxillofac Pathol* 2012;16(1):79-82.
5. Mubeen K, Vijayalakshmi KR, Abhishek RP. Oral pyogenic granuloma with mandible involvement: An unusual presentation. *J Dent Oral Hyg.* 2011 Jan 31;3(1):6-9.
6. Rachappa MM, Triveni MN. Capillary hemangioma or pyogenic granuloma: A diagnostic dilemma. *Contemp Clin Dent* 2010;1(2):119-122.
7. Dojcinovic I, Richter M, Lombardi T. Occurrence of a pyogenic granuloma in relation to a dental implant. *J Oral Maxillofac Surg.* 2010;68(8):1874-6.
8. Jafarzadeh H, Sanatkhan M, Mohtasham N. Oral pyogenic granuloma: a review. *J Oral Sci* 2006;48(4):167-174.
9. Parisi E, Glick PH, Glick M. Recurrent intraoral pyogenic granuloma with satellitosis treated with corticosteroids. *Oral diseases.* 2006;12(1):70-2.
10. Epivatianos A, Antoniadis D. Pyogenic granuloma of the oral cavity: Comparative study of its clinicopathological and immunohistochemical features. *Pathol Int* 2005;55:391-397.
11. Pagliai KA, Cohen BA. Pyogenic granuloma in children. *Pediatr Dermatol* 2004;21:1-4.
12. Sato H, Takeda Y, Satoh M. Expression of the endothelial receptor tyrosine kinase Tie-2 in lobular capillary hemangioma of the oral mucosa: An immunohistochemical study. *J Oral Pathol Med* 2002;31:432-438.
13. Yuan K, Jin YT, Lin MT. Expression of Tie-2, angiopoietin-1, angiopoietin-2, ephrinB2 and EphB4 in pyogenic granuloma of human gingiva implicates their roles in inflammatory angiogenesis. *J Periodontal Res* 2000;35:165-17.