

Metastatic Ewing's Sarcoma of Mandible: A rare case report

Ravi Prakash S.M.^{1,*}, Sankalp Verma², Sumit Goel³, Swati Gupta⁴, Pooja Aggarwal⁵

¹Professor & Head, ^{3,4,5}Reader, ^{1,3,4}Dept. of Oral Medicine & Radiology, ⁵Dept. of Pathology, Subharti Dental College & Hospital, Meerut, ²Assistant Professor, Consultant, Sai Hospital, Moradabad

***Corresponding Author:**

Email: sasan_ravi@rediffmail.com

Abstract

Ewing's Sarcoma (ES) is one of the most aggressive bone tumors which usually occur in children and young adults. The extensive literature search indicates occurrence of only 2-7% cases in the maxillofacial region. Also, very few cases of metastatic Ewing's sarcoma have been reported till date. This article reports a case of Ewing's sarcoma that had metastasized from left humerus to the right side of mandible.

Keywords: Ewing's Sarcoma, Metastatic, Humerus, Mandible.

Introduction

While best remembered by his eponym, James R. Ewing, an eminent American pathologist in New York City, in 1921 gave a definitive description of a series of bone tumors which he called 'diffuse endothelioma'. In 1928, to limit the proliferation of empirical names like endothelioma, perithelioma, reticular sarcoma, intramedullary sarcoma; Oberling introduced the term Ewing's sarcoma which was a non-committal name in regard to the cell of origin.⁽¹⁾ ES is the second most common malignant bone tumor occurring in children and young adults. Males are most commonly affected than females (1.5:1).^(2,3) About two-thirds of all Ewing's sarcoma appears in the lower skeleton and the facial skeleton involvement is quite rare.⁽³⁾

Rapid growth and propensity for metastasis are dominant features of this primary malignant bone tumor. The possibility exists that the jaw involvement may represent metastasis from another skeletal site. Here we report a rare case of metastatic Ewing's sarcoma of the mandible, the primary site being left humerus.

Case Report

A 19 year old boy reported to the outdoor patient department with a chief complaint of swelling on the right side of face since 2 months. Patient also complained of intraoral swelling in right lower jaw. Past dental history revealed extraction of teeth 2 months back from the same region because of pain. Since then he started developing a gradually increasing swelling over the right cheek. Past medical history revealed Ewing's sarcoma of left humerus 2 years back which was operated and was followed by radiotherapy. General physical examination revealed deformity in left hand.

Extraorally, a swelling was present on right side of face measuring approx 4 cm x 3.5 cm and was extending from infraorbital region up to lower border of the mandible and antero-posteriorly from corner of mouth to tragus area (Fig. 1a). Overlying skin over the swelling was normal. On palpation, swelling was tender, firm in

consistency, non-pulsatile, non-compressible with no evidence of secondary changes. The right submandibular lymph node was noted to be enlarged, soft, mobile and tender on palpation. There was no clicking of the temporomandibular joint but there was a restriction on opening, closing, and lateral excursions. Intraorally, a swelling measuring approximately 3.5 cm x 2.5 cm was present extending from distal of right lower first molar to ramus area (Fig. 1b). Mobility was present in respect to right lower first molar. The ulceration was present on the overlying mucosa secondary to trauma from maxillary molars.

Taking into consideration the above findings, the patient was subjected to radiographic investigations. Panoramic radiograph revealed a poorly defined osteolytic lesion on the right side of ramus and body of mandible with a sun ray spicule pattern of the periosteal bone (Fig. 1c). Full characterization of the lesion was not possible because of superimposition of the soft palate & hyoid bone. Additional investigations included computed tomographic scan, ultrasonography, magnetic resonance imaging and technetium radionuclide bone scan.

Contrast enhanced computed tomography (CECT) of neck and face (Fig. 2c) revealed a large heterogeneously enhancing soft tissue density mass with necrotic areas epicentered at ramus and body of mandible on right side with soft tissue component extension into right infratemporal fossa, lateral wall of right maxillary sinus with involvement of pterygoid plates, pterygoid muscles, temporalis and muscles of masticator space. The lesion was also causing destruction of the cortex of mandible with multiple linear areas of calcification (sun ray appearance). CECT scan of the paranasal sinuses (Fig. 2d) revealed a large ill-defined osteolytic expansile lesion (8.4 x 6.6 cm) with cortical and marrow lysis of the angle, ramus, condyle and coronoid process of right side of mandible with periosteal reaction in the form of sun ray specules which was suggestive of Ewing's sarcoma. Color doppler

ultrasonography (Fig. 2a) of the affected site revealed the presence of hyperechoic area. Multiplanar MR images (Fig. 3) of the face were obtained using T1W, T2W & STIR sequences. They revealed nearly defined large marrow infiltrating soft tissue mass lesion along right side of ramus, body of mandible and condyle with no intracranial extension or skull bone involvement.

After diagnosis, radionuclide bone scan (Fig. 2b) was performed in whole body mode in anterior and posterior views after intravenous administration of 20mCi of Tc-99m MDP. This revealed abnormal increased inhomogeneous uptake in the right mandibular lesion (site of metastasis) and mildly increased uptake in the mid-shaft of left humerus (primary site). Rest of the skeleton showed physiological tracer distribution.

Surgical treatment with right hemimandibulectomy with upper alveolectomy with PMMC flap reconstruction was done. Histopathological specimen revealed extremely cellular connective tissue stroma comprising of solid sheets of small round cells with very little stroma. The cells were small round with scanty cytoplasm and relatively large hyperchromatic nucleus. Areas of haemorrhage and necrosis were also evident (Fig. 4a & b). Immunohistochemistry of the tumor cells showed equivocal positivity for synaptophysin and CD99 consistent with Ewing's sarcoma.

All the above findings confirmed the diagnosis of metastatic Ewing's sarcoma in which the primary site was left humerus.

After surgery, the patient was advised for radiotherapy. He received 40Gy in 20 fractions to the tumor drainage area followed by boost of 18 Gy in 9 fractions using 6 MV photon beams. He received a total dose of 62 Gy in 31 fractions during one and half month's period. For a year the patient was on follow up.

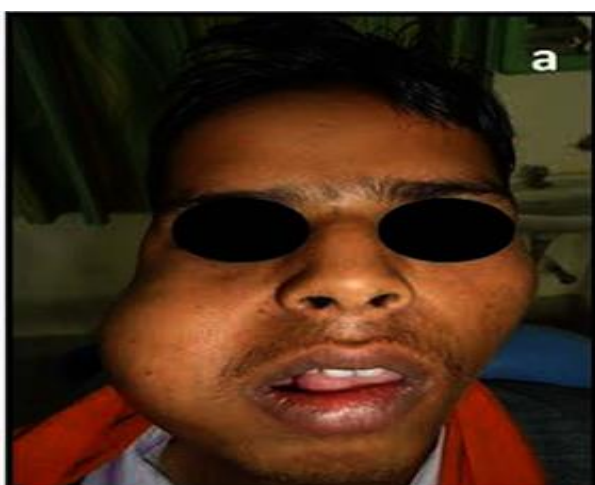

Fig. 1a: Profile photograph showing swelling in right side of face

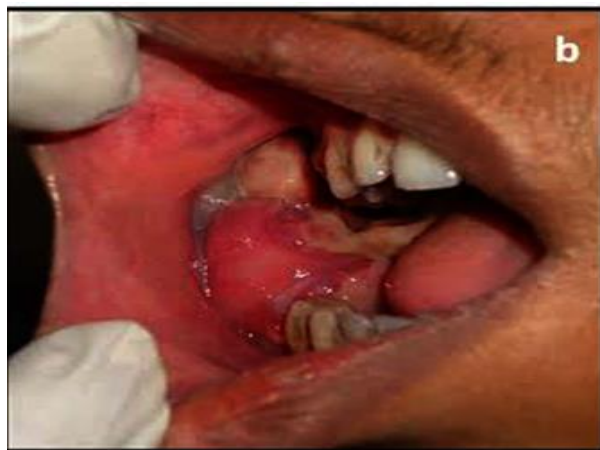

Fig. 1b: Intraoral photograph showing the extent of swelling from distal of right 1st molar extending to the ramus area

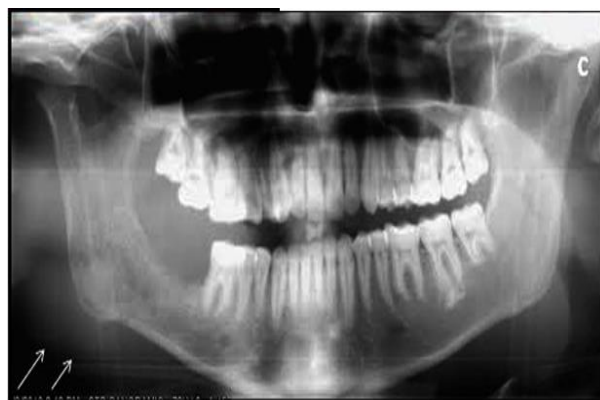

Fig. 1c: Orthopantomograph shows a poorly defined osteolytic lesion in the right ramus and body of mandible with a sun ray spicule pattern of the periosteal bone

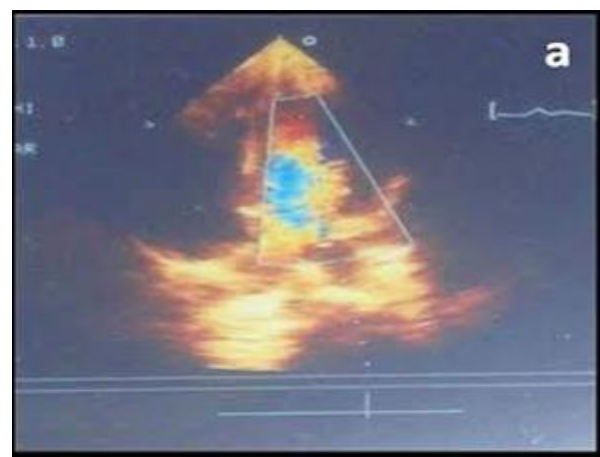


Fig. 2a: Color doppler ultrasonography showing a hyperechoic area

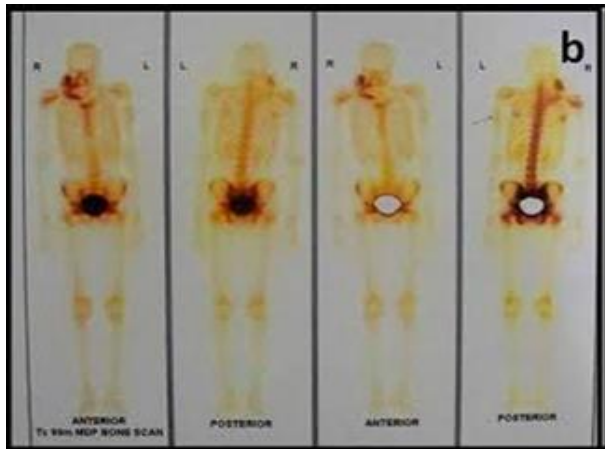


Fig. 2b: Tc 99m bone scan showing an abnormal increased inhomogeneous uptake in the right side of the mandibular (site of metastasis) and a mildly increased uptake in the mid-shaft of left humerus (primary site). Rest of the skeleton showed physiological tracer distribution

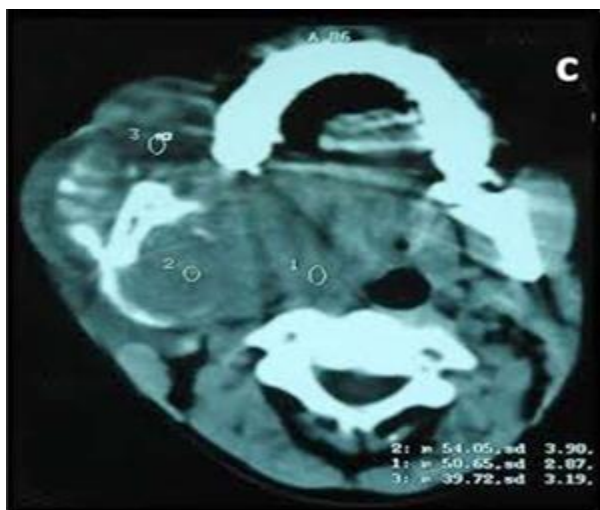


Fig. 2c: Axial CECT of neck and face showing large heterogeneously soft tissue density mass with necrotic areas epicentered at ramus and body of mandible

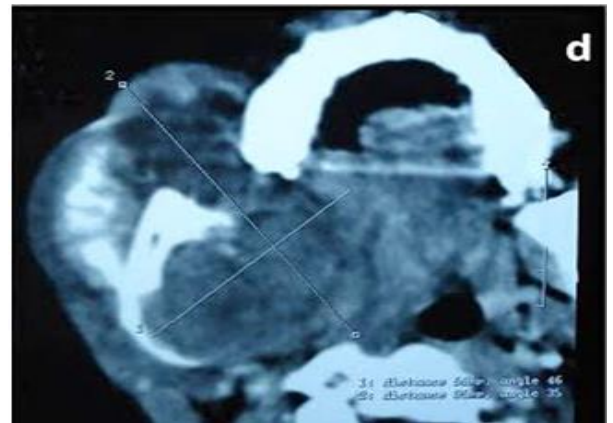


Fig. 2d: Contrast enhanced axial CT of paranasal sinuses showing a large ill-defined expansile lesion (8.4 x 6.6 cm) in right ramus and condylar region with sun ray pattern of periosteal reaction

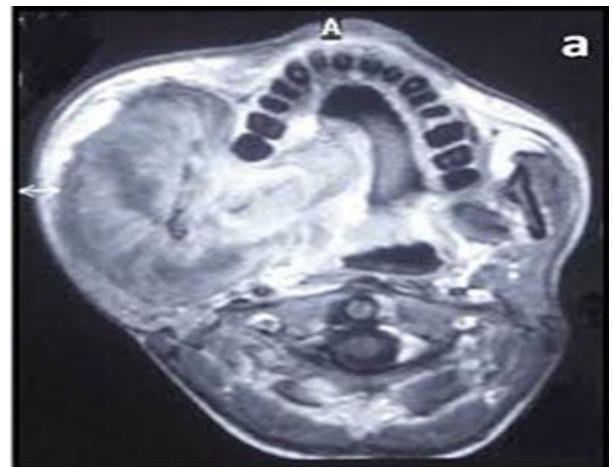


Fig. 3: MRI of face showing nearly defined large marrow infiltrating soft tissue mass along right side of ramus, body of mandible and condyle measuring approx 10.1(CC x 8.1(TR) x 10.3(AP) cm in size(a: Axial view)

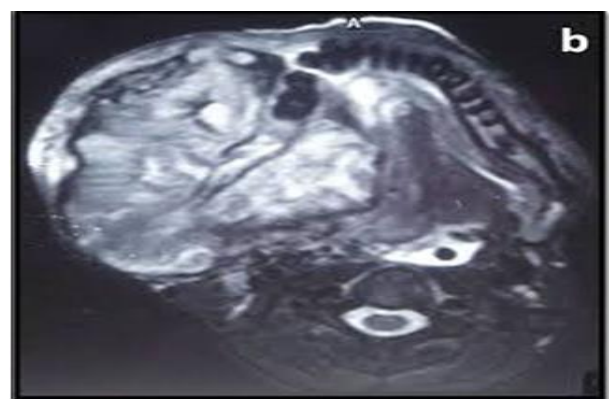


Fig. 3: MRI of face showing nearly defined large marrow infiltrating soft tissue mass along right side of ramus, body of mandible and condyle measuring approx 10.1(CC x 8.1(TR) x 10.3(AP) cm in size(b: Axial view)

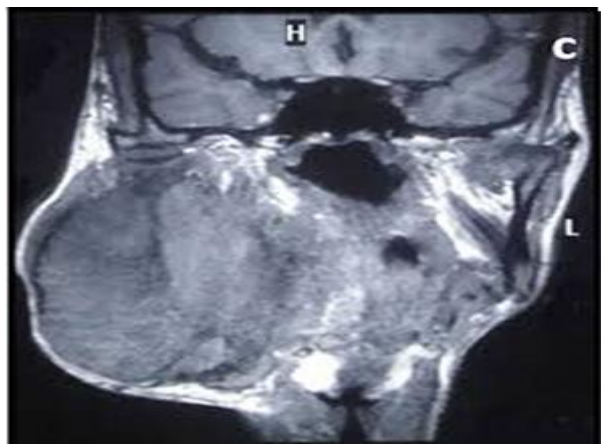


Fig. 3: MRI of face showing nearly defined large marrow infiltrating soft tissue mass along right side of ramus, body of mandible and condyle measuring approx 10.1(CC x 8.1(TR) x 10.3(AP) cm in size(c: Coronal view)

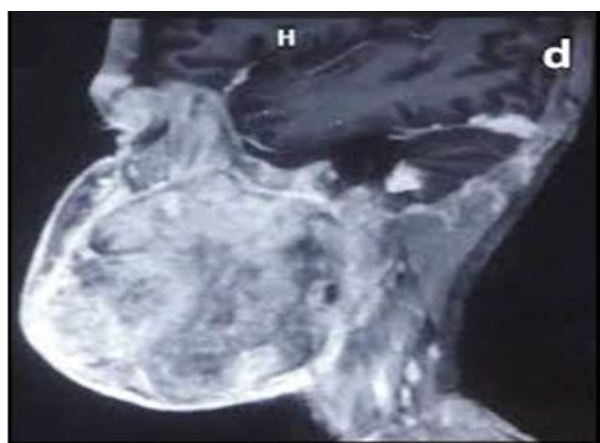


Fig. 3: MRI of face showing nearly defined large marrow infiltrating soft tissue mass along right side of ramus, body of mandible and condyle measuring approx 10.1(CC x 8.1(TR) x 10.3(AP) cm in size(d: Saggital view)

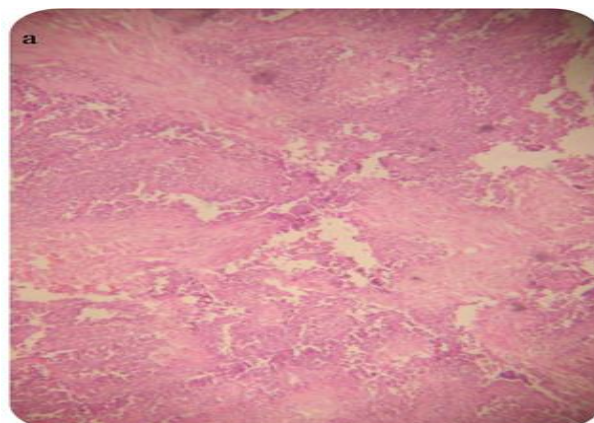


Fig. 4a: H and E(4x)-cellular mesenchymal tissue showing solid sheets of round cells with areas of necrosis

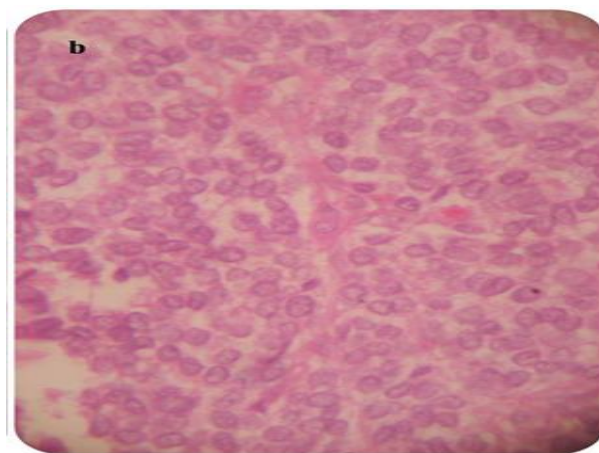


Fig. 4b: H and E(40x)-small round tumor cells with scanty cytoplasm and dispersed chromatin

Discussion

A review of the literature revealed more than 120 reported cases of primary and metastatic Ewing's sarcoma to the jaw. Only 11 of those cases appeared to be metastatic tumors.⁽³⁾ ES affecting jaw is uncommon in Indian population. Till date very few cases of ES involving the jaws in Indian population have been reported, but none of them have reported the metastatic ES to the jaw (Table 1).⁽⁴⁻⁸⁾ To the best of our knowledge this is the only case reported in literature of metastatic Ewing's sarcoma of mandible that originated from the left humerus.

Table 1: Summary of all reported cases of ES involving jaws in India till date (modified from Mukhejee A et al, Prashant BV et al, Yeshvanth SK et al, Jairamdas Nagpal DK et al)⁽⁴⁻⁸⁾

S no.	Age (yr.)/ sex/Site	Author	Clinical features	Radiological features	Metastasis/ Primary site
1	6-20/M/Mandible	Potdar G.G et al, 1970	Bony hard swelling in affected site	Osteolytic destruction of bone	No
2	17/F/Mandible	Sidhu S.S et al.,1976	Swelling in right side of face	Ill-defined radiolucency with	No

				root resorption of adjacent teeth	
3	15/M/Zygoma	Narasimhan A et al.,1993	Swelling on zygoma	Ill-defined radiolucency in zygoma and infratemporal fossa	No
4	20/F/Ramus area	Singh et al,2003	Swelling in right side of face	Osteolytic lesion of ramus	No
5	15/M/Mandible and maxilla	Sharada P et al, 2006	Swelling in right side of face crossing the midline	Ill-defined osteolytic lesion with floating tooth in both jaws	No
6	18/Maxilla	Prasad BV et al,2008 ⁵	Bony hard swelling	Radiolucent lesion involving nasal bone and maxilla	No
7	15/F/Zygoma	Deshingkar et al.,2009	Swelling in right side of face	Osteolytic lesion in right zygoma and orbit	No
8	30/M/Maxilla	Gupta et al,2009	Hard pedunculated mass in posterior palate crossing midline	Ill-defined radiolucency in naso-maxillary complex	No
9	12/M/Maxilla	Dadhe et al.,2010	Painful swelling in maxillary tuberosity region	Mixed radiolucent-radiopaque lesion	No
10	11/F/Mandible	Rao et al., 2011	Bony hard swelling, expansion of cortical plate, mobility of teeth	Radiolucent lesion in body and ramus area	No
11	16/F/ Maxilla	Pampori et al.,2011	Bony hard swelling on face	Radiolucent lesion in maxilla	No
12	8/F/ Mandible	Mukherjee et al.,2012	Hard swelling in anterior mandibular region	Ill-defined radiolucent lesion with sunburst appearance	No
13	29/F/sinonasal tract	Yeshvanth SK et al ⁶ , 2012	Nasal obstruction and epistaxis, fleshy pedunculated mass in the right middle meatus	Computerized tomography (CT) revealed soft tissue density lesion in the right nasal cavity, maxillary, frontal, ethmoidal and bilateral sphenoid sinuses with bony erosions of medial and posterior wall of the right maxillary sinus	no
14	14/M/Mandible	Bhanderkar G.P. et al.,2012	Progressively enlarging swelling in right side of mandible	Poorly demarcated osteolytic lesion with floating tooth	No
15	15/M/Mandible	Jairamdas Nagpal DK et al, ⁽⁷⁾	Facial asymmetry with	osteolytic lesion with focal areas of	no

		2014	a well-circumscribed swelling measuring about 8 × 5 cm on the right cheek.	opacification in right maxilla and nasal cavity	
16	11.5(5-16 years)/6 mandible and 5 maxilla	Qureshi SS et al, 2014 ⁽⁸⁾	Facial asymmetry	Not available	no
17	8/F/ anterior mandible	Mukherjee A et al	Painless, gradually increasing swelling in the mandibular anterior region.	ill-defined mixed radiodensity lesion, Destruction of cortical plates and 'sun-ray' appearance	no
18	19/M/Mandible	Present case	Bony hard swelling in right side of face	Poorly defined osteolytic lesion in the right side of ramus and body of mandible with a sun ray spicule pattern in the periosteal bone	Yes, Primary site was left humerus

Ewing sarcoma comprises 4% to 15% of all primary bone tumors and less commonly arises in soft tissues also. Long bones of the extremities (58%) and pelvis (20%) exhibit a particular predisposition. On the other hand, 3% arise in the skull and 7% occur in the ribs.^(3,4) It also affects the jaws varying from 1% to 10% of cases and usually involves the mandibular ramus area, with a few cases reported which involve the maxilla.^(5,9,10)

Eighty percent of all Ewing's tumors occur in the first two decades of life.⁽²⁾ Malignant changes of Ewing's sarcoma start in the bone diaphyses and spread through the marrow spaces. This is followed by osteolytic action on the cortical plate and soft tissue involvement around the site of periosteal destruction. In the jaw, mandible is most commonly affected either as a primary or as metastatic disease. This rarity is thought to be due to the paucity of hematopoietic marrow, its usual site of origin, in the mandible. This explanation may account for the propensity of mandibular Ewing's sarcoma to occur in the posterior portion of the mandible.^(2,3) The present case was rare with metastatic involvement of mandible.

Patients with Ewing's sarcoma have a high incidence of relapse, which may appear as long as 10 to 15 years after the initial diagnosis. This has led to a hypothesis that a somatic defect predisposes the human cells to a molecular abnormality that in turn gives rise to tumour formation and favours oncogenesis.⁽³⁾ In the present case, metastasis occurred in the mandible 2 years after the initial diagnosis.

In the jaws, swelling of the involved area and pain, paresthesia, ulceration, loose teeth are frequent symptoms of Ewing's sarcoma.^(3,4) Other signs and symptoms include fever, anemia, leukocytosis and an increased erythrocyte sedimentation rate (ESR).^(9,10,11)

Radiographically, most common feature is poorly defined osteolytic lesion. The lesion may produce a diffuse irregular radiolucency or a moth-eaten destructive radiolucency with ill-defined margins and cortical destruction or expansion.^(5,9,10) Several types of periosteal reactions have been observed: (i) an 'onion skin' or 'onion-peel appearance' is a prominent multi-layered reaction, (ii) a 'sunburst' or 'spiculae' pattern is a perpendicular reaction, while (iii) 'Codman's triangle' is a triangular lifting of the periosteum from the bone at the site of detachment. Onion skin appearance is a common feature in long bones but is rarely found in jaws.^(3,9,10)

Mandibular tumors typically show only an osteolytic lesion and occasionally a "sun-ray" appearance.^(2,9,11) Other radiographic features of Ewing's sarcoma of jaw may include localized honeycomb appearance, cortical erosion, a soft tissue mass adjacent to bony destruction, displacement or destruction of unerupted tooth follicles, advanced eruption of a tooth with immature root development and widened periodontal ligament space.^(3,5) In our case also, osteolytic lesion with soft tissue mass adjacent to bony destruction was present in right mandibular region along with marked destruction of periodontal ligament of distal surface of first molar.

The extent of both intraosseous and adjacent soft tissue involvement can be underestimated if scintigraphy or CT is not used.^(5,9,10) In our case, both axial and coronal CT sections revealed presence of lytic lesion in the right side of body and ramus area. Bone scintigraphy is necessary to detect skeletal metastasis.^(9,10) In our case,⁽⁹⁾ Tc bone scan revealed presence of increased bone activity in right side of mandible and mid shaft of left

humerus. Magnetic resonance imaging is the imaging modality of choice to evaluate the extent of the lesion and to monitor the response to neoadjuvant chemotherapy.^(9,11) In our case, large nearly defined marrow infiltrating soft tissue mass lesion was present along right side of mandible.

Histologically, Ewing's sarcoma is a diffuse mass of uniform, small round cells often associated with significant areas of coagulative necrosis and marked vascularity.⁽³⁾ Histopathologically the tumor must also be differentiated from other small round cell tumor such as mesenchymal chondrosarcoma, rhabdomyosarcoma, malignant lymphoma, eosinophilic granuloma, neuroendocrine tumors and metastatic neuroblastoma. In general, the tumor cells are positive for vimentin and CD99 and negative for neural, skeletal, vascular and lymphoid cell markers.⁽⁷⁾

The differential diagnosis of Ewing's sarcoma of the mandible includes other mass lesions of the jaw such as osteosarcoma, Burkitt's lymphoma, mesenchymal chondrosarcoma, and metastatic childhood tumors such as Wilm's tumor, retinoblastoma, or neuroblastoma.^(2,3)

Treatment for mandibular Ewing's sarcoma has consisted of various single and combination therapies involving radiation, chemotherapy, and surgery.⁽²⁾ In mandible, complete surgical resection is preferred to irradiation for local control in those instances when surgery can be performed with minimal loss of function and disfigurement and also requires a multidisciplinary approach with a option for reconstructive surgery explored early.^(5,10)

The lethal nature of Ewing's sarcoma dictates early intervention to improve the prognosis. Appropriate diagnostic tests are essential when there is a reasonable cause for concern. A thorough review of the medical history may aid in the diagnosis of metastatic lesions. Management by a multidisciplinary oncology team

produces an optimal result that eliminates disease & restores function, aesthetics & quality of life.

References

1. Hajdu SI. A note from history: The enigma of Ewing's sarcoma. *Ann Clin Lab Sci* 2006;36:108-110.
2. Berk R, Heller A, Heller D, Schwartz S., Klein EA. Ewing's sarcoma of mandible: A case report. *Oral Surg Oral Med Oral Pathol* 1995;79:159-62.
3. Wang CL, Yacobi R, Pharoah M, Thorner P. Ewing's sarcoma: Metastatic tumor to the jaw. *Oral Surg Oral Med Oral Pathol* 1991;71:597-602.
4. Mukherjee A, Ray JG, Bhattacharya S, Dev T. Ewing's sarcoma of mandible: A case report and review of Indian literature. *Contemp Clin Dent* 2012;3:494-98.
5. Prasad BV, Ahmed BR, Bastian TS, Tauro DP. Ewing's sarcoma of the maxilla. *Indian J Dent Res* 2008;19:66-9.
6. Yeshvanth SK, Ninan K, Bhandary SK, Lakshinarayana KP, Shetty JK, Makannavar JH. Rare case of extraskeletal Ewings sarcoma of the sinonasal tract. *J Cancer Res Ther.* 2012 Jan-Mar;8(1):142-4.
7. Jairamdas Nagpal DK, Prabhu PR, Palaskar SJ, Patil S. Ewing's sarcoma of maxilla: A rare case report. *J Oral Maxillofac Pathol.* 2014 May;18(2):251-5.
8. Qureshi SS, Kembhavi S, Bhagat M, Laskar S, Chinnaswamy G, Vora T, Prasad M, Ramadwar M, Desai S, Khanna N, Kurkure P, Shah S, Shankdhar V, Yadav P. Primary non-metastatic Ewing sarcoma of the jaw in children: results of surgical resection and primary reconstruction. *J Surg Oncol.* 2014 Nov;110(6):689-95. doi: 10.1002/jso.23698. Epub 2014 Jun 25.
9. Singh JP, Garg L, Shrimali R, Gupta V. Radiological appearance of Ewing's sarcoma of the mandible. *Indian J Radiol Imaging* 2003;13:23-5.
10. Talesh KT, Motamedi MHK, Jeihounian M. Ewing's Sarcoma of the Mandibular Condyle: Report of a Case. *J Oral Maxillofac Surg* 2003;61:1216-19.
11. Gorospe L., Fernández-Gil MA, García-Raya P, Royo A, López-Barea F., García-Miguel P. Ewing's sarcoma of the mandible: Radiologic features with emphasis on magnetic resonance appearance. *Oral Surg Oral Med Oral Pathol Oral Radiol Endod* 2001;91:728-34.