

## Peripheral ameloblastoma of mandible – A case report

Suresh Menon<sup>1,\*</sup>, Deepika Bendwal<sup>2</sup>, Veerendra Kumar<sup>3</sup>

<sup>1</sup>Professor & Head, <sup>2</sup>Consultant, <sup>3</sup>Reader, Dept. of Oral & Maxillofacial Surgery, Vydehi Institute of Dental Sciences & Research Centre, Bangalore

**\*Corresponding Author:**

Email: psumenon@gmail.com

### Abstract

Peripheral ameloblastoma is a rare odontogenic tumour with very little bony involvement and good prognosis after surgical excision. The nonspecific clinical picture of the condition can lead to error in diagnosing this odontogenic tumour.

The proper diagnosis of this entity is significant in its pathogenesis and potential recurrence if treated like other similar pathologies. This paper reports a case of peripheral ameloblastoma of the mandibular alveolar region with a brief review of literature.

**Keywords:** Ameloblastoma, Alveolus, Odontogenic Epithelium.

### Introduction

Peripheral ameloblastoma (PA) is a relatively uncommon odontogenic tumor that is histologically similar to the classic intraosseous type but it occurs primarily in the soft tissues overlying the tooth bearing regions of maxilla and mandible without exhibiting the invasive and aggressive behavior of its intraosseous counterpart.<sup>(1)</sup>

There are less than 100 cases reported in English literature. The primary importance of these tumours is the non-specific clinical appearance that can mimic any of the non odontogenic swellings on the gingiva and lead to incomplete treatment and lack of long term follow up if wrongly diagnosed. They account for approximately 2% to 10% of all ameloblastomas.<sup>(2)</sup>

The first documented case of PA can be attributed to Kuru in 1911<sup>(3)</sup> though Stanley and Krogh<sup>(4)</sup> were the first to adequately document a case of ameloblastoma that was located entirely within soft tissue overlying bone but separate from it.

The strict definition of PA according to Buchner and Scuibba<sup>(5)</sup> excludes lesions in extragingival locations. However, some authors believe the term PA should be used not only to describe a neoplasm arising in the soft tissues overlying the tooth-bearing regions of the maxilla and mandible, but also for those found in other parts of the oral mucosa such as the cheek, palate and floor of the mouth. They base their belief on experimental findings that oral epithelium has the potential to differentiate into ameloblasts and to form odontogenic lesions.<sup>(6)</sup>

### Case History

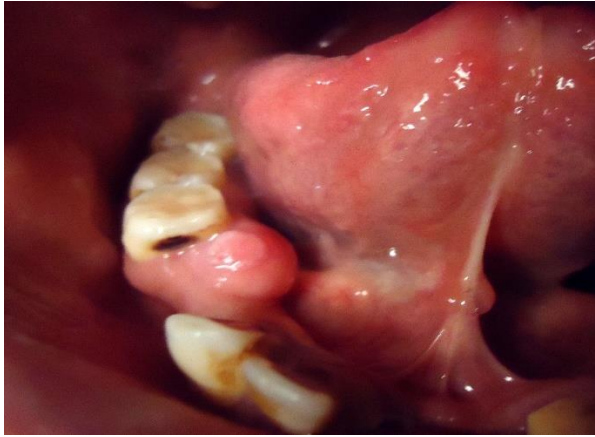A 44 year old man reported to the hospital with a complaint of a swelling in the right posterior region of the mandible. The patient gave a history of a painless swelling appearing 3 years ago and growing very gradually in size, resulting in difficulty in chewing (Fig. 1). The patient had reported to a dentist six months back and both lower right premolars which were

approximating the swelling were extracted. On examination, there was a well-defined swelling involving the lingual aspect of the right mandible, measuring 2 x 2 centimetres. It extended from the alveolar mucosa of the missing second premolar to the distal aspect of the first molar. The swelling was firm in consistency with normally appearing overlying mucosa. It was fixed to the underlying mucosa and was painless. The mandibular right first molar was asymptomatic and vital. There was no regional lymphadenopathy. Intra oral radiographs of the region showed no obvious bony involvement (Fig. 2). A provisional diagnosis of peripheral ossifying fibroma was made with a probable differential diagnosis of pyogenic granuloma.

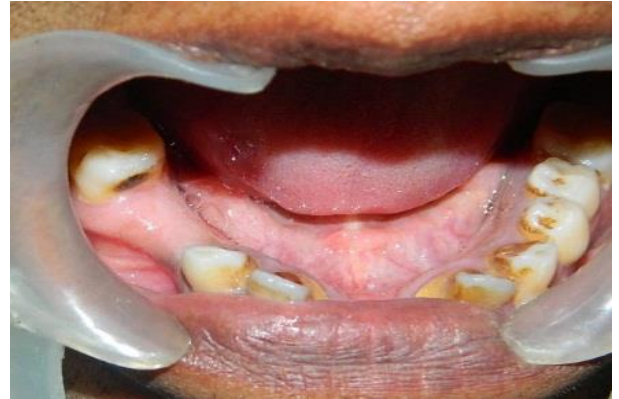An excisional biopsy of the lesion was planned under local anaesthesia. The excision was done subperiosteally with a safe margin of 5 millimetres from the edge of the swelling leaving a raw alveolar surface for secondary epithelisation. The healing of the area was uneventful.

The histopathological examination revealed a hyperkeratotic stratified squamous epithelium with underlying connective tissue stroma. Plenty of odontogenic follicles with peripheral tall columnar cells with reverse polarity and central stellate reticulum like areas were seen (Fig. 3). The odontogenic epithelial cells were arranged in plexiform pattern. In addition sheets of odontogenic epithelial islands were seen and a diagnosis of peripheral ameloblastoma was made.

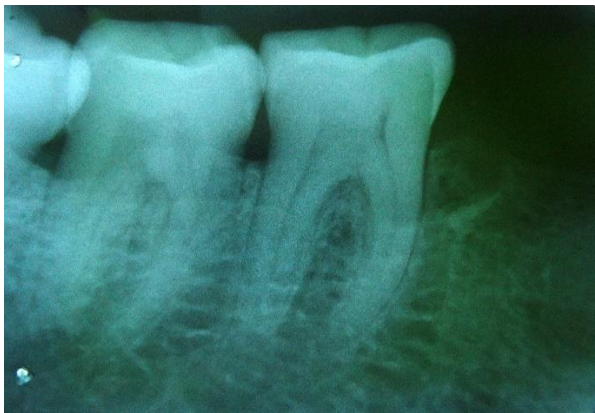The patient reported after 6 months for a review. The mucosal area on the operated site showed good healing (Fig. 4) with no evidence of recurrence or any bony involvement (Fig. 5). The patient has been reviewed after another 6 months and there is no sign of recurrence. The patient has been asked to follow up for review every 6 months for at least a couple of years.



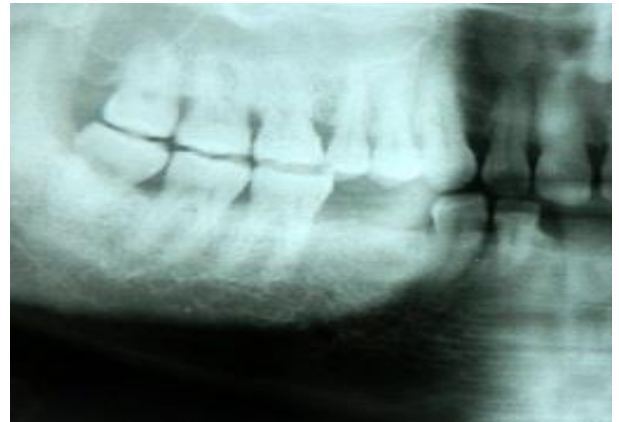**Fig. 1: Preoperative view of the lesion**



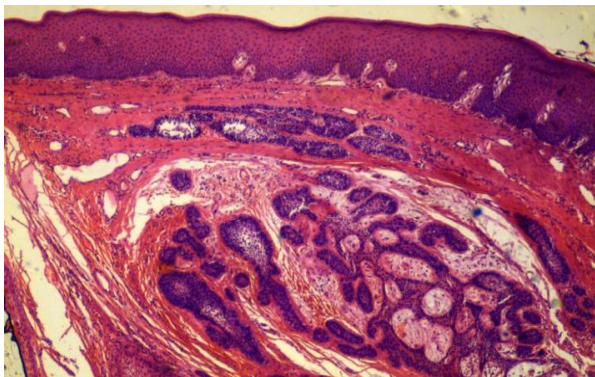
**Fig. 4: Postoperative view of the region**



**Fig. 2: Preoperative radiograph**



**Fig 5. Postoperative radiograph**



**Fig. 3: Hyperkeratotic stratified squamous epithelium with odontogenic cells in a plexiform pattern**

### Discussion

Peripheral ameloblastoma arises from the extraosseous remnants of the dental lamina or the basal cell layer of oral epithelium.<sup>(5)</sup> According to Fumio Ide et al,<sup>(7)</sup> under exceptional conditions, an uncommitted subset of basal cells in the adult gingival epithelium reverts to the fetal form capable of ameloblastic differentiation. The subsequent clonal proliferation and eventual uncontrolled growth gives rise to peripheral ameloblastoma.

Origin from the basal cell layer of the oral mucosa is further supported by the findings by Ficarra G & Hansen LS<sup>(8)</sup> where there was an epithelial continuity between the tumour and the basal epithelial cells that can be detected in serial sections.

Peripheral ameloblastomas are more common in males<sup>(9)</sup> and are most often found in the older age groups than the classic intraosseous ameloblastoma with an age range of 23 to 92 years.<sup>(10)</sup>

The most common site of their occurrence is the mandibular mucosa in the region of lingual gingiva of the canine, premolar area, followed by the molar-retromolar region.<sup>(11)</sup> This was similar to our patient. PA can also be seen infrequently in the maxilla.<sup>(12)</sup>

There have also been rare instances (Less than 6 reported cases) of the lesion occurring in extra gingival regions like the buccal floor and floor of the mouth.<sup>(13)</sup>

While peripheral ameloblastoma usually appears as a single lesion, there are also case reports of simultaneous peripheral and intraosseous forms of the entity occurring together.<sup>(14)</sup>

These lesions are usually asymptomatic and appear as an exophytic condition with the overlying mucosa being normal in colour and smooth surfaced. Their size can be up to 5 cm and the larger ones usually become symptomatic because of the trauma due to their interference with occlusion.

Very rarely do these lesions involve the underlying bone. The radiographic picture is usually negative under the lesion. However, superficial saucerisation of the underlying bone has been reported and is attributable to pressure resorption rather than invasion.<sup>(15)</sup>

The clinical picture of peripheral ameloblastomas is non-specific and can be similar to fibrous nodules, gingival tumours, peripheral odontogenic fibromas, peripheral ossifying fibromas, pyogenic granuloma, peripheral giant-cell granuloma, etc.<sup>(16)</sup>

The diagnosis is based on the origin from the overlying epithelium and histopathological picture showing the presence of odontogenic epithelium islands in the lesion and lack of a potential to bone infiltration.

One of the most significant differences between the peripheral and intraosseous variety is in their clinical behaviour. Peripheral ameloblastomas do not exhibit the aggressive behaviour as shown by the intra osseous variety thus exhibiting a better prognosis.<sup>(1)</sup> As a result of this, recurrence rate in these lesions is low as compared to the very high recurrence rates attributed to the intra osseous variety. This could be attributed to the fact that being clinically evident easily they are treated earlier. In addition, the dense fibrous connective tissue of gingiva resists their spread and bone is an efficient barrier to invasion.

The histopathological picture of these lesions can be either the acanthomatous, plexiform or follicular types. Because of the location and its histopathologic features it is possible to mistake it with basal cell carcinoma.<sup>(17)</sup> Like the basal cell carcinoma of the skin, the PA shows proliferation of basal cells often arranged in nests included in a fibrous stroma with areas of contact with the epidermis. The arrangement of the rim cells of the nests are palisading, but in contrast with the basal cell carcinoma, these cells have the nuclei located on the basis of the cytoplasm, the rim cells of the peripheral ameloblastoma have the nuclei located on the upper part of the cytoplasm. In addition, the immunohistochemical analysis establishes the differences between these two types of tumors. The basal cell carcinoma shows diffuse and marked positivity for Ber-Ep4 and negativity for cytokeratin 19; on the contrary, the peripheral ameloblastoma is always negative for Ber-EP4, except very focal areas in which a true basaloid differentiation is present, and diffusely and markedly positive for the cytokeratin 19.<sup>(18)</sup>

Peripheral ameloblastomas show similar histopathologic features of subtypes of intraosseous ameloblastoma. However, the desmoplastic variant has rarely been reported in peripheral ameloblastomas and therefore, it is unknown if biologic behavior of peripheral ameloblastomas vary based on histopathologic subtype.<sup>(19)</sup>

The malignant transformation of peripheral ameloblastoma is rare and has been reported in literature.<sup>(20)</sup> There is also a reference to metastasis to supra clavicular lymph nodes.<sup>(21)</sup>

As far as management of this condition is concerned, histologically, the PA consists of proliferating odontogenic epithelium exhibiting the same histomorphological cell types and patterns as seen in the intraosseous type. The indolent biological behaviour dictates a conservative therapeutical approach.<sup>(22)</sup>

The current treatment of choice for peripheral ameloblastoma is conservative supraperiosteal excision with adequate margins. Long-term clinical follow-up is recommended because of the paucity of literature on the long term follow up.<sup>(23)</sup>

## References

1. El-Mofty S, Gerard N, Farish S, et al: Peripheral ameloblastoma: A clinical and histologic study of 11 cases. *J Oral Maxillofac Surg* 48:970,1991.
2. Ueno S, Nakamura S, Mushimoto K, et al: A clinicopathologic study of ameloblastoma. *J Oral Maxillofac Surg* 44:361,1986.
3. Zhu EX, Okada N, Takagi M: Peripheral ameloblastoma: Case report and review of literature. *J Oral Maxillofac Surg* 53:590,1995.
4. Stanley HRJ, Krogh HW: Peripheral ameloblastoma. Report of a case. *Oral Surg Oral Med Oral Pathol* 12:760-765,1959.
5. Buchner A, Scuibba JJ: Peripheral epithelial odontogenic tumors: A review. *Oral Surg* 63:688,1987.
6. Zhu EX: Dental lamina as presumptive source of odontogenic cyst. *J Stomatol Soc Jpn* 57:549,1990.
7. Fumio Ide, Kenji Mishima, Yuji Miyazaki, Ichiro Saito and Kaoru Kusama, Peripheral ameloblastoma in-situ: an evidential fact of surface epithelium origin *Oral Surg Oral Med Oral Pathol Oral Radiol Endod* 108:763-767,2009.
8. Giuseppe Ficarra, Louis S. Hansen Peripheral Ameloblastoma A Case Report. *J. Cranio-Max.-Fac. Surg.* 110-112,1987.
9. Castner D, McCully AC, Hiatt W: Intracystic ameloblastoma in the young patient. *Oral Surg Oral Med Oral Pathol* 23:127,1967.
10. Philipsen HP, Reichart PA, Nikai H, et al: Peripheral ameloblastoma: Biologic profile based on 160 cases from the literature. *Oral Oncol* 37:17,2001.
11. Kiran Holikatti, Swapnil Deore, Pavan Gothe, Nageshkumar Shinde. Ameloblastoma masquerading as gingival enlargement: A case report with unusual presentation. *Journal of Oral & Maxillofacial Surgery, Medicine and Pathology*, in press, corrected proof, Available online 2 Jan 2015.
12. Bryan J Vanoven, Noah P Parker, Guy J Petruzzelli. Peripheral ameloblastoma of the maxilla: a case report and literature review. *American journal of Otolaryngology* Vol 29 Issue 5,357-360, Sep-Oct 2008.

13. Emiko Tanaka Isomura, Masaya Okura, Syunsuke Ishimoto, Chiaki Yamada, Yudai Ono, Mitsumobu Kishino, and Mikihiko Kogo Case report of extragingival peripheral ameloblastoma in buccal mucosa Oral Surg Oral Med Oral Pathol Oral Radiol Endod 108:577-579,2009.
14. Ibrahim E. El-Hakim and Mostafa M. El-Khashab Peripheral and Mural Ameloblastoma in the Mandibular Canine Region of a 13-Year-Old Boy. J Oral Maxillofac Surg 58:1150-1154,2000.
15. Patrikiou, S Papanicolaou, E Stylogianni and S Sotririadou Peripheral ameloblastoma Case report and review of the literature. Int. J. Oral Surg, 12:51-55,1983.
16. Yasuchika, Kaneko, and Shigeru Ueno, Peripheral Ameloblastoma Resembling a Papilloma: Report of Case. J Oral Maxillofac Surg 44:737-739,1986.
17. Simpson HE. Basal cell carcinoma and peripheral ameloblastoma. Oral Surg Oral Med Oral Pathol 38:233-40,1974.
18. M. Lentini, A. Simone, G. Carrozza Peripheral ameloblastoma: use of cytokeratin 19 and Ber-EP4 to distinguish it from basal cell carcinoma Oral Oncology EXTRA 40 79-80,2004.
19. Steven E. Smullin, William Faquin, Srinivas M. Susarla, and Leonard B. Kaban, Peripheral desmoplastic ameloblastoma: report of a case and literature review Oral Surg Oral Med Oral Pathol Oral Radiol Endod 105:37-40,2008.
20. Ernest Baden, John L. Doyle, and Victor Petriella. Malignant transformation of peripheral ameloblastoma Oral Surg Oral Med Oral Pathol 75:214-9,1993.
21. Song-Chyr Lin, Chen-Mei Lieu, Liang-Jiunn Hahn And Hsueh-Wan Kwan Peripheral ameloblastoma with metastasis Int. J. Oral Maxillofac. Surg. 16:202-204,1987.
22. HP Philipsen, RA Reichart, H Nikai, T Takata, Y Kudo, Peripheral ameloblastoma: biological profile based on 160 cases from the literature, Oral oncology Vol 37, Issue 1, 17-21, Jan 2001.
23. Herculio Martelli-Junior, Leandro N. Souza, Luis Antonio Nogueira Santos, Ma'rio R. Melo-Filho, Alfredo M. B. De Paula, Peripheral ameloblastoma: A case report Oral Surg Oral Med Oral Pathol Oral Radiol Endod, 99:E31-3,2005.