

An extra tooth in mixed dentition- A case report

Puneet Kumar^{1,*}, Kanika G. Verma², Pradhuman Verma³, Sonali Anand⁴, Sonam Sethi⁵

¹PG Student, ^{2,3}Reader, ^{4,5}UG Student, ^{1,2}Dept. of Paediatrics & Preventive Dentistry, ³Dept. of Oral Medicine & Radiology, ^{4,5}Private Practitioner, Surendera Dental College and Research Institute, Sri Ganganagar, Rajasthan

***Corresponding Author:**

Email: puneetgdr01@gmail.com

Abstract

Supernumerary tooth refers to an extra tooth in the arch. It is considered to be a developmental anomaly with multiple etiological factors. Supernumerary teeth can be present in any region of dental arches but most commonly they are located in the anterior maxillary region. They can erupt or remain embedded in the alveolar bone. The embedded supernumerary commonly affect developing dentition, whereas those which are erupted can cause various esthetic or functional problems. Occurrence of supernumerary teeth is more frequently in the permanent dentition than in the primary dentition. These are considered as one of the most significant dental anomaly when found in primary dentition or mixed dentition stages. Its significance is considered to be of great concern to the parents and dentists because of associated disturbances. Various classifications are available considering their form and location. Detection of these teeth can be achieved by thorough clinical and various radiographical examination. Their management should be done by outlining a comprehensive treatment plan. Here, we are discussing a unique case of supernumerary tooth associated with mixed dentition.

Keywords: Supernumerary Tooth, Mixed Dentition, Conical, Crossbite, Maxilla.

Introduction

Various morphologic stages and physiologic growth processes interplay to achieve the final tooth form and structure during the development of tooth. There are various etiological factors associated with supernumerary teeth like “Phylogenetic process of atavism”, the dichotomies of the tooth bud, hereditary and a combination of various genetic and environmental factors etc.⁽¹⁻⁴⁾ Most accepted etiology of the supernumerary teeth is a localized and independent hyperactive dental lamina is present.^(2,4,5)

A supernumerary tooth is one that is an extra tooth to the normal series of teeth in an arch and can be present anywhere in the dental arch.^(6,7) In the primary dentition, the incidence of supernumerary teeth is found to be 0.3%-0.6%, and in the permanent dentition it is 1.5%-3.5%.^(6,8) The reason behind the low prevalence of supernumerary teeth in primary dentition may be because it is less reported and it is many times overlooked, because they appear to be in proper alignment, they are often of normal shape (supplemental type), erupt normally and can be misinterpreted with germination and fusion.^(6,9,10) There is no significant sex distribution in primary supernumerary teeth; however, males are reported to be affected more in the permanent dentition than females with a predilection of 2 : 1 for male sex.^(11,12)

The reported most common region of supernumerary teeth is the premaxilla region, which may lead to development of pathological conditions like failure of permanent maxillary incisors eruption and displacement or rotation of permanent tooth.^(11,13) Displacement or rotation of permanent teeth (28–63%), delayed or impaired eruption of permanent teeth (26–52%), crowding, diastema, or premature closure of

space, dilaceration or abnormal root development of a permanent tooth, formation of cyst (4–9%), or eruption into nasal cavity can be caused by the supernumerary teeth. Thus, early recognition and its management is important as a preventive measure for the development of normal permanent dentition.^(12,14)

Case Report

A seven year old male patient reported to the Department of Pedodontics and Preventive Dentistry, Surendera Dental College and Research Institute, Sri Ganganagar, Rajasthan, with the chief complaint of irregular placement of teeth in upper and lower front teeth region. There was no history of trauma. His medical and family history was not relevant with no deleterious habits present. Intraoral examination revealed mixed dentition with a conical shaped supernumerary tooth present distal to 11 and anterior single tooth cross-bite was present w.r.t 11 (Fig. 1). Intraoral radiographic analysis was done. Intraoral periapical radiograph and maxillary occlusal radiograph revealed the presence of conical supernumerary tooth distal to 11 (Fig. 2 & 3). Orthopantomograph was done to rule out the presence of any other supernumerary teeth in the arch (Fig. 4). The extraction of the supernumerary tooth and correction of single tooth crossbite with the help of catlan’s appliance was planned.

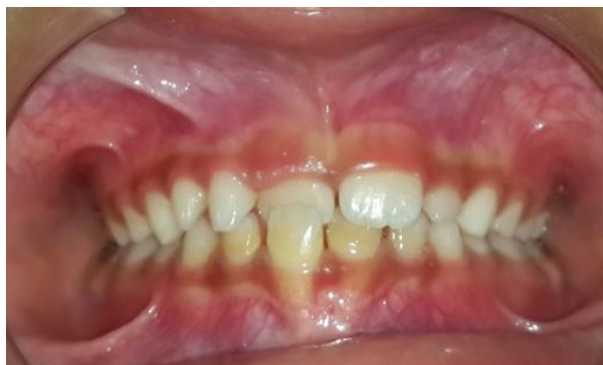

Fig. 1: Intraoral photograph showing anterior single tooth crossbite w.r.t 11 in occlusion view

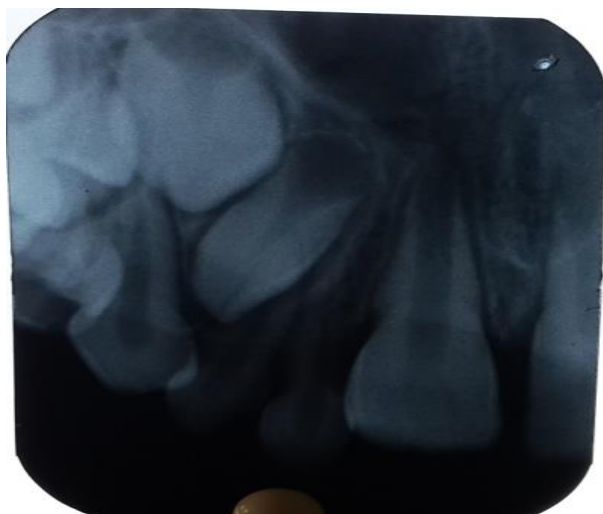

Fig. 2: Intraoral periapical radiograph w.r.t 11

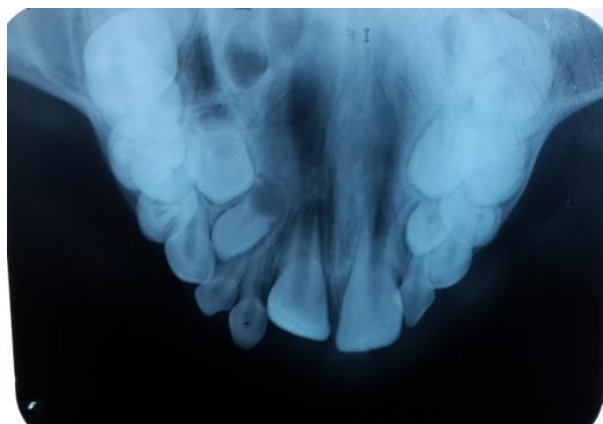


Fig. 3: Intraoral maxillary occlusal radiograph

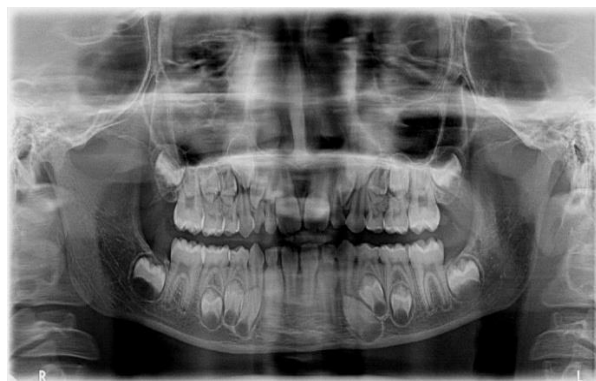

Fig. 4: Orthopantomograph

Discussion

The spacing present in the primary dental arches may be utilized in the eruption of supernumerary tooth or teeth with reasonable alignment that could be the possible explanation for the under reporting of supernumerary teeth in deciduous and mixed dentition. Many children have their dental examination after the eruption of permanent anterior teeth, so presence of anterior deciduous supernumerary teeth would not be detected, because they have been erupted and exfoliated.^(11,12)

Supernumerary tooth is of great concern in the maxillary anterior region to both the patient and dentists it can lead to problems like failure of eruption of adjacent teeth, crowding, spacing, rotation of teeth, dentigerous cyst formation, esthetics and midline shift.^(11,15,16)

It is essential not only to enumerate but also to identify the supernumerary teeth present in the dental arch clinically and radiographically before a definitive diagnosis and formulation of its treatment plan. Early diagnosis of such conditions is essential to prevent these problems and minimize complications. If any of the above complications are present, a supernumerary tooth should be extracted immediately.⁽⁶⁾

Conclusion

The presence of supernumerary teeth is rare in deciduous and mixed dentition period. The treatment of supernumerary tooth varies and depends upon the cooperation of patient, his age, position of supernumerary tooth and its effects. A thorough knowledge is necessary to diagnose supernumerary teeth and its implications, so as to formulate the required treatment plan.

References

1. Smith JD. Hyperdontia: Report of a case. *J Am Dent Assoc* 1969;79(5):1191-2.
2. Liu JF. Characteristics of premaxillary supernumerary teeth: A survey of 112 cases *ASDC J Dent Child*. 1995;62(4):262-5.
3. Brook AH. A unifying etiological explanation for anomalies of human tooth number and size. *Arch Oral Biol* 1984;29(5):373-8.

4. Kumar A, Namdev R, Bakshi L, Dutta S. Supernumerary teeth: Report of four unusual cases. *Contemp Clin Dent* 2012;3(Suppl1):S71-S77.
5. Scheiner MA, Sampson WJ. Supernumerary teeth: A review of the literature and four case reports. *Aust Dent J* 1997;42(3):160-5.
6. Fazliah SN. Supernumerary tooth: report of a case. *Arch OrofacSci* 2007;2(4):54-8.
7. Garvey MT, Barry HJ, Blake M. Supernumerary teeth- an overview of classification, diagnosis and management. *J Can Dent Assoc* 1999;65(11):612-6.
8. Mason C, Azam N, Holt RD, Rule C. A retrospective study of unerupted maxillary incisors associated with supernumerary teeth. *Br J Oral Maxillofac Surg* 2000;38(1):62-5.
9. Taylor GS. Characteristics of supernumerary teeth in primary and permanent dentition. *Dent Pract Dent Record* 1972;22(5):203-8.
10. Humerfelt D, Hurlen B, Humerfelt S. Hyperdontia in children below four years of age: a radiographic study. *ASDC J Dent Child* 1985;52(2):121-4.
11. Hattab FN, Yassin OM, Rawashdeh MA. Supernumerary teeth: Report of three cases and review of the literature. *ASDC J Dent Child* 1994;61(5-6):382-93.
12. Bahadure RN, Thosar N, Jain ES, Kharabe V, Gaikwad R. Supernumerary teeth in primary dentition and early intervention: A series of case reports. *Case Rep Dent* 2012.
13. Koch H, Schwartz S, Klausen B. Indications for surgical removal of supernumerary teeth in the premaxilla. *Int J Oral Maxillofac Surg* 1986;15(3):273-81.
14. Mitchell L. Supernumerary teeth. *Dent Update* 1989;16(2):65-8.
15. Shanmugha Devi G, Arangannal P, Muthu MS, Nirmal L. Supernumerary teeth associated with primary and permanent teeth: A case report. *J Indian Soc Pedo Prev Dent* 2002;20(3):104-6.
16. Erkmén N, Olmez S, Onerci M. Supernumerary tooth in the maxillary sinus: A case report. *Aus Dent J* 1998;43(6):385-6.