

## Unicystic Ameloblastoma – A case report

Asish R<sup>1,\*</sup>, Vinimol C<sup>2</sup>, Akhilanand Chaurasia<sup>3</sup>

<sup>1</sup>Assistant Professor, Govt. Dental College, Thiruvananthapuram, Kerala, <sup>3</sup>Assistant Professor, Dept. of Oral Medicine & Radiology, King George's Medical University, Lucknow, Uttar Pradesh, <sup>2</sup>Assistant Insurance Medical Officer, Insurance Medical Services Dept., ESI Dispensary, Karamana, Thiruvananthapuram, Kerala

**\*Corresponding Author:**

Email: asishrajasekharan12@gmail.com

### Abstract

Ameloblastoma is the most significant and common odontogenic tumor of epithelial origin. It is a benign, locally invasive neoplasm. Its persistent local growth produces marked deformity. Its frequent recurrence occurs after conservative surgery. Unicystic ameloblastoma, a variant of ameloblastoma is believed to be less aggressive and responds more favorably to conservative surgery than the solid or multicystic types. The neoplastic nature of the lesion became evident only when the enucleated material was available for histopathologic examination. Here we present a case along with a review of the literature.

**Keywords:** Ameloblastoma, Unicystic

### Introduction

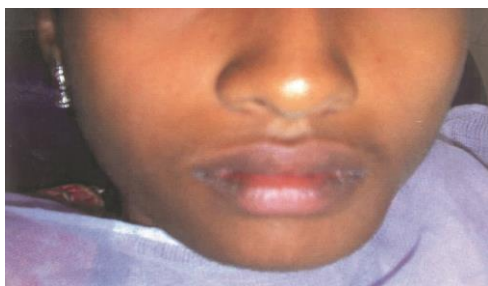Unicystic ameloblastoma, a variant of ameloblastoma first described by Robinson and Martinez in 1977. It refers to those cystic lesions that show clinical and radiologic characteristics of an odontogenic cyst. But in histopathologic examination show a typical ameloblastomatous epithelium lining part of the cyst cavity, with or without luminal and/or mural tumor proliferation. This variant is believed to be less aggressive. It affects generally patients at a younger age.

### Case Report

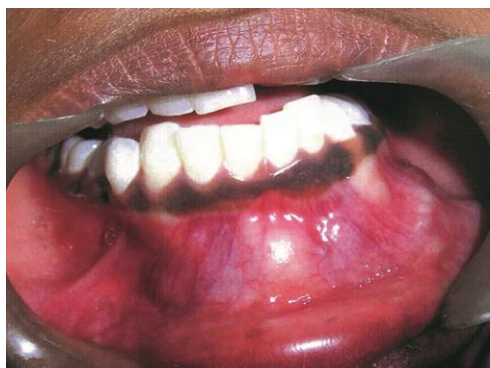
A 16 year old girl came to the department with complaints of painful swelling in the chin of 6 month duration. The swelling started as a small one 6 month's back which was not painful initially. There was no associated toothache or paresthesia or associated symptoms. She consulted with a local dentist and referred to Govt. Dental College for expert opinion and management. There was no relevant history of trauma.

Medical, family history was non-contributory. Sleep, appetite, bowel and bladder habits, menstrual cycles were normal. No history of any ill habits. Extraoral examination shows a diffuse swelling of 4 x 2.5 cm in the mandibular anterior region (Fig. 1). Palpation revealed a tender firm swelling of 4 x 2.5 cm with diffused and smooth. Skin over the swelling was normal with no pigmentation, scars or sinuses. Intraoral examination revealed firm swelling of 5 x 2.5 cm extending from 34 – 44 region (Fig. 2). Prominent buccal and lingual cortical plate expansion was noticed. The swelling obliterated the mandibular labial sulcus inferiorly and alveolar mucosa superiorly. The mucosa over the swelling was normal with no pus discharge or sinus tract. Buccal mucosa, tongue, floor of mouth, palate were appears to be normal. The hard tissue examination shows full complement of teeth up to the

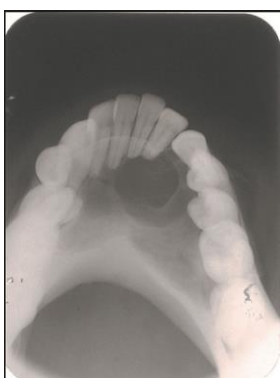chronological age. Retained 75 and 85 noticed. No mobility of tooth was noticed. A clinical impression of an odontogenic cyst or a tumor was considered. The Routine blood and urine examinations were within the normal limits. Panoramic view revealed a unilocular radiolucent lesion of 7 x 2.5 cm which extends from 35 – 44 regions (Fig. 5). One impacted premolar, supernumerary teeth noticed on 35 and premolar on 45 regions. Root resorption was noted from mesial root of 36 – 44 (Fig. 3, 4). Mandibular occlusal view shows buccal and lingual cortical plate expansion. The radiographic diagnosis of ameloblastoma was considered. The patient was sent to Department of Oral Surgery for biopsy. The biopsy was taken and the specimen sent for histopathological examination in Department of Oral Pathology. The histopathologist give the report as the section shows a densely collagenous connective tissue stroma lined by a thin layer of odontogenic epithelium (Fig. 6). The epithelial lining consists of tall columnar basal cells and the supra basal layer consists of stellate reticulum like cells (Fig. 7). No ghost cells or calcifications were noticed in the supra basal layers. The subepithelial connective tissue shows a thin layer of hyalinization. A few island of odontogenic cells made up of tall columnar basal cell enclosing stellate reticulum like cells are also noticed in the connective tissue stroma (Fig. 7, 8). The connective tissue shows a very scant to minimal inflammatory infiltration and a few blood vessels engorged with RBCs are noticed particularly close to the lining epithelium. The report was suggestive of unicystic ameloblastoma.



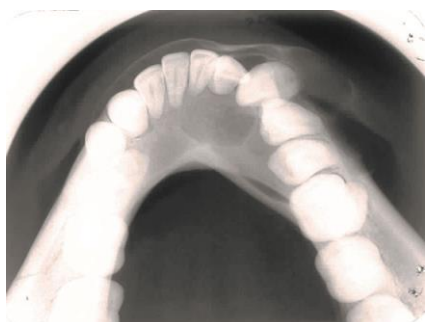**Fig. 1:** Photograph showing swelling in the mandibular anterior region



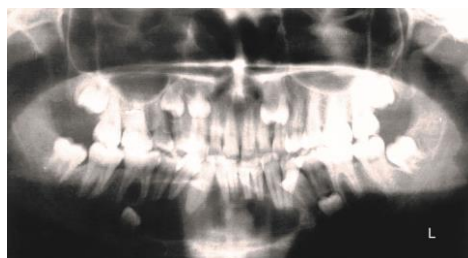
**Fig. 2:** Intra oral photograph showing obliteration of mandibular labial sulcus extending from 34 to 44 region



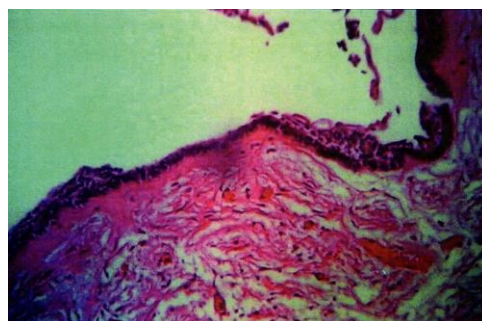
**Fig. 3:** Occlusal radiograph shows well defined radiolucency extending from 34 to 44 region



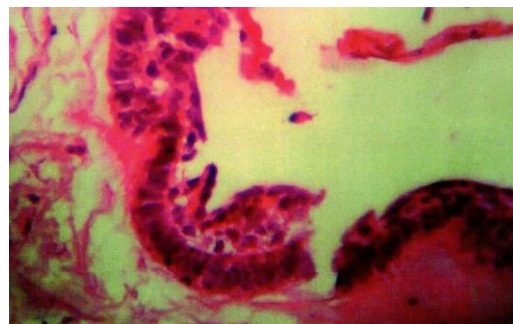
**Fig. 4:** Occlusal radiograph shows buccal and lingual cortical plate expansion



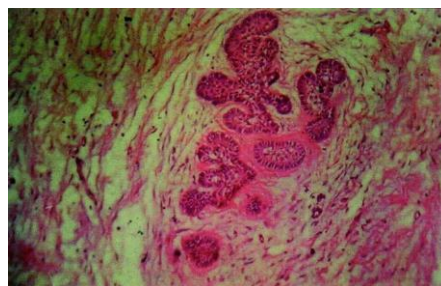
**Fig. 5:** Panoramic view showing a well-defined unilocular radiolucency with impacted supernumerary tooth in relation to 35 & 45 regions and root resorption of 36 to 44



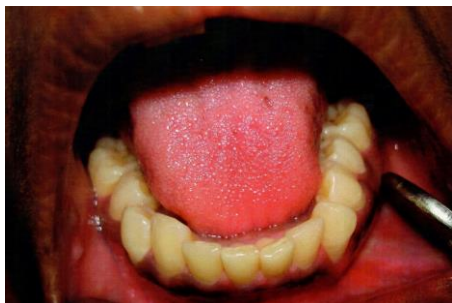
**Fig. 6:** Photomicrograph showing cystic lining and adjacent connective tissue



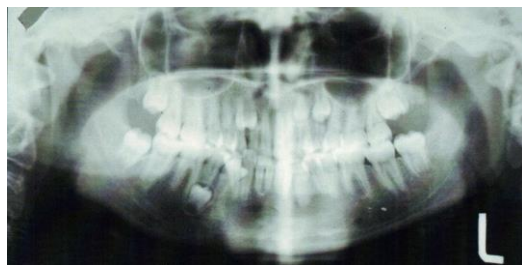**Fig. 7:** Cystic lining showing tall columnar basal cells and suprabasal stellate reticulum like cells



**Fig. 8:** Ameloblastic follicles in the connective tissue



**Fig. 9: Post treatment intraoral photograph**



**Fig. 10: Post treatment Panoramic radiograph**

## Discussion

Ameloblastoma is a true neoplasm of enamel organ type tissue.<sup>(1,2,3)</sup> It was recognized in 1827 by Cusack. This type of odontogenic neoplasm was designated as an adamantinoma in 1885 by the French physician Louis-Charles Malassez. It was finally renamed to the modern name ameloblastoma in 1930 by Ivey and Churchill. Ameloblastoma is also termed as adamantinoma by Malassez, odontoblastoma and multilocular cyst.<sup>(4,5,6,7,8,9,10)</sup> Robinson described this tumor as 'usually unicentric, nonfunctional, intermittent in growth, anatomically benign and clinically persistent. It is the second most common odontogenic neoplasm. These tumors are grouped into conventional solid or multicystic, unicystic and peripheral (extraosseous) types.<sup>(10)</sup>

Ameloblastoma is of varied origin. The tumor may be derived from: cell rests of enamel organ-either remnants of dental lamina or remnants of Hertwig's sheath, epithelial rests of Malassez, Epithelium of odontogenic cysts – dentigerous cyst, odontomas, Disturbances of developing enamel organ, Basal cells of surface epithelium of jaws, Heterotrophic epithelium – Pituitary gland.<sup>(5,6,7,8,9,10)</sup> Ameloblastoma occur in a wide range of age groups.<sup>(4,7,9,10)</sup> The average age at diagnosis is 33-39 years. No significant sex predilection has been reported. Ameloblastoma occur in all areas of jaws. Ameloblastomas are often associated with unerupted teeth. Symptoms include painless swelling, facial deformity if severe enough, pain if the swelling impinges on other structures, loose teeth and ulcers. Most of lesions occur in the ascending ramus area and will result in extensive and grotesque deformities. In the maxilla it can extend into the maxillary sinus and floor of the nose. Mandible is affected more commonly with molar – angle – ramus area.<sup>(7,8,9,10)</sup> While these

tumors are rarely malignant or metastatic and progress slowly, the resulting lesions can cause severe abnormalities of the face and jaw. Sometimes abnormal cell growth easily infiltrates and destroys surrounding bony tissues. There are three main clinical subtypes of ameloblastoma: unicystic, multicystic, peripheral.<sup>(2,4,5,8,9,10)</sup> The peripheral subtype composes 2% of all ameloblastomas. Of all ameloblastomas in younger patients, unicystic ameloblastomas represent 6% of the cases.

Peripheral (Extraosseous) ameloblastoma occurs in soft tissue outside the overlying alveolar bone.<sup>(9-11)</sup> This tumor appears to originate from either surface epithelium or remnants of dental lamina. Mandible is frequently involved that maxilla with ratio of 2:1. The lesions usually appear as nodules on gingiva of varying site. Pituitary Ameloblastoma is a neoplasm involving the central nerve system.<sup>(9,10,11,12)</sup> It is also known as craniopharyngioma or Rathke's pouch tumor. It is usually situated in suprasellar areas, often destroys pituitary gland. It is originated from the portion of fetal craniopharyngeal duct. The presence of islands and nests of 'ghost' cells are characteristic. Admantinoma of tibia is also been reported.<sup>(13)</sup>

Unicystic ameloblastoma is the second most type of intraosseous form.<sup>(3,4,5,8,9,10)</sup> It generally accounts for 10-15% of all intraosseous forms. It tends to occur in younger populations. Most of the lesions occur in the posterior region of mandible. It appears as a circumscribed radiolucency that surrounds the crown of unerupted teeth.

A fourth subtype, malignant, has been considered by some oncologic specialists, however, this form of the tumor is rare and may be simply a manifestation of one of the three main subtypes. The common pathologic subtypes are follicular, acanthomatous, granular cell, basal cell, desmoplastic and plexiform.<sup>(5,7,8,9,10,15)</sup> The cells that have the tendency to move the nucleus away from the basement membrane and referred to as "Reverse Polarization". The follicular (simple) is the most common encountered variant. It is composed islands of odontogenic epithelium in a mature fibrous connective tissue stroma. A single layer of cuboidal or columnar cells surrounds the central core resembling ameloblasts or preameloblasts. Central area composed of polyhedral, loosely arranged cells resembling stellate reticulum. In the plexiform type ameloblasts like tumor cells are arranged in irregular masses arranged as a network of interconnecting strands of cell-- "Fish Net Pattern". Each of these mass surrounded by columnar cells.

Acanthomatous pattern shows extensive squamous metaplasia associated with Keratin formation in the central portion of tumor islands.<sup>(3,5,9,10)</sup> Occasionally keratin or epithelial pearl may be observed; such a lesion may be confused with squamous cell carcinoma or squamous odontogenic tumor. In granular cell ameloblastoma cytoplasm of stellate reticulum like cells

shows coarse, granular, eosinophilic appearance. This variant is seen in clinically aggressive tumors. The basal cell pattern is the least common type composed of nests of uniform basal cells with considerable resemblance to basal cell carcinoma of skin.<sup>(9,10)</sup> The desmoplastic variant is characterized by dense hyalinized collagen stroma which contains islands of odontogenic epithelium. The central cells scant in epithelial proliferation and cuboidal cells making up the periphery.

The histologic variants of unicystic type are luminal, intraluminal and mural ameloblastomas.<sup>(3,5,9,10)</sup> Typically these lesion shows lining epithelium exhibiting alterations, nodules projecting intraluminally and islands of ameloblastoma occurring isolated in connective tissue wall. The tumor is confined to the lumen of the cyst in the intraluminal variety. These patterns also named as plexiform unicystic ameloblastoma. The mural cystic ameloblastoma, the fibrous wall of the cyst is infiltrated by follicular or plexiform ameloblastoma.

Ameloblastoma is tentatively diagnosed through radiographic examination and must be confirmed by histological examination.<sup>(5,7,8,9,10,14,15)</sup> The ameloblastomas are classically demonstrated on roentgenograms as multilocular cyst like lesions. The tumor exhibits a compartmented appearance with septae of bone extends into the radiolucent mating. Usually periphery of the lesion appears to be smooth and expansion of cortical plates noticed in advanced stages of lesion. The characteristic picture described as 'soap bubble' or honey comb in appearance. Resorption of roots of adjacent teeth is common. Desmoplastic type showed mixed radiolucent and radiopaque appearance on roentgenograms. The lesion has a tendency to expand the bony cortices because slow growth rate of the lesion. It allows time for periosteum to develop thin shell of bone ahead of the expanding lesion. This shell of bone cracks when palpated and this phenomenon is referred to as "Egg Shell Cracking" or crepitus.

The various treatment modalities range from simple enucleation, curettage to resection.<sup>(9,10,16,17,18,19)</sup> Marginal resection is the commonly used treatment. It remains the most definitive treatment for this condition. Because of the invasive nature of the growth, excision of normal tissue near the tumor margin is often required. It had a tendency to spread to adjacent bony and sometimes soft tissues without metastasizing. Ameloblastomas are suspected to spread to adjacent areas of the jaw bone via marrow spaces. Margin of resection should be 1.0 cm beyond the roentgenographic margin. Thus, wide surgical margins that are clear of disease are required for a good prognosis. This is very much like surgical treatment of cancer. Often, treatment requires excision of entire portions of the jaw. The attempts to remove tumor by curettage results in recurrence. Maxillary lesions have the more tendencies for spreading due to the high

cancellous bone rather than dense cortical plates of mandible.

The probable reason for a good prognosis is that the unicystic ameloblastoma is generally cystic, well-localized, and surrounded by a fibrous capsule. However, once the tumor has broached the periphery of the capsule, it can infiltrate the surrounding cancellous bone. Thus, it is crucial for pathologists to carefully examine all biopsy or excision specimens, by multiple sampling and even serial sectioning, to search for the mural tumor islands. Their presence should indicate additional management procedures, possibly involving a second operation to remove surrounding bone and/or a long period of follow-up.<sup>(7,8,9,10,17,18,19)</sup>

### Conclusion

Ameloblastomas account for about one percent of all oral tumors and about 18% of odontogenic tumors. Men and women tend to be equally affected. The long term follow up of the patient is necessary regardless of type and management.

### References

1. Baden E. Terminology of ameloblastoma. History and current usage. *J Oral Surg* 1965;23:40.
2. Gardner DG. Critique of the review by Reichart et al. of the biologic profile of 3677 ameloblastomas. *Oral Oncol* 1999;35(4):443-449.
3. Pindborg JJ, Clausen F. Classification of odontogenic tumors: a suggestion. *Acta Odont Scand* 1958;16:29-301.
4. Regezi JA. Odontogenic cysts, odontogenic tumors, fibrous and giant cell lesions of jaws. *2002;15(3):331-341.*
5. Regezi JA, Kerr DA, Courtney RM. Odontogenic tumors: analysis of 706 cases. *J Oral Surg* 1978;36:771.
6. Spouge JD. Odontogenic tumors. *Oral* 1967;1:887-894.
7. Small IA, Waldron CA. Ameloblastomas of jaws. *Oral Surg* 1955;8:281.
8. Thoma KH. Tumors of odontogenic origin. *Oral pathology St. Louis (Mo): Mosby* 1941;945-6.
9. Neville, Damm, Allen, Bouquot. *Oral Maxillofacial pathology* 2<sup>nd</sup> edition.
10. R. Rajendran, B. Sivapathasundaram. *Shafer's Text book of Oral Pathology* 5<sup>th</sup> edition.
11. Wettan HL, Patella PA, Freedman PD. Peripheral ameloblastoma; review of literature and report of recurrence of severe dysplasia. *J Oral Maxillofacial Surg* 201;59(7):811-815.
12. Cricechley M, Ironside RN. The pituitary admantinoma. *1926;49:473.*
13. Huvos AG, Marcove RI. Admantinoma of long bones. A clinicopathological study of fourteen case with vascular origin suggested. *J Bone Joint Surg* 1975;57:148.
14. Struthers P, Shear M. Root resorption by ameloblastomas and cysts of jaws. In *J Oral Surg* 1976;5:128.
15. Kramer IRH, Pindborg JJ, Shear M. *Histologic typing of odontogenic tumors.* Berlin: Springer 1992.
16. Robinson L, Martines M. Unicystic ameloblastoma is a prognostically distinct entity. *Cancer* 1977,40(5):2278 – 2285.
17. Philpsen HP, Reichart PA. Unicystic ameloblastoma: a review of 193 cases from the literature. *Oral Med* 1998;34(5):312-325.

18. Ackerman GH, Altini M, Shear M. The unicyclic ameloblastoma a clinopathologic study of 57 cases. J Oral Pathol 1988;17:541-2519.
19. Gardner DG, Pecak AMJ. The treatment of ameloblastoma based on pathologic and anatomic principles. Cancer 1980;46:2514-2519.