

Assessment of complications occurring after third molar removal: A retrospective study

Khemraj Agarwal¹, Hemanth Kumar HR^{2,*}, Rakesh Sharma³, Chandrakala TP⁴

¹Assistant Professor, Dept. of Oral & Maxillofacial Surgery, Triveni Institute of Dental Sciences & Research Centre, Bilaspur, Chhattisgarh, ²Assistant Professor, Dept. of Dentistry, Karwar Institute of Medical Sciences, Karwar, ³Clinician, Dept. of Oral Medicine & Radiology, Orocare, Bangalore, ⁴Dental Health Officer, Dept. of Community Health Centre, Bellur

*Corresponding Author:

Email: dr_hemanth82@yahoo.com, kr7514915@gmail.com

Abstract

Introduction: Removal of third molar is the most frequently performed procedure associated with a wide array of complications. The most commonly encountered complications are pain, paresthesia, trismus, swelling and mandibular fractures. The aim of present study was to evaluate and estimate the prevalence of complication associated with wisdom tooth removal and its association with age.

Materials and Method: This study was conducted in the Triveni Institute of Dental Sciences, Hospital & Research Centre, Bilaspur, Chhattisgarh. All the surgical removal of third molars which were performed in the Department of Oral and Maxillofacial Surgery during 1 year period from April 2016 - March 2017 were retrospectively analysed and included in the study. Presence of post operative complications like pain (more than 3 days), paresthesia, mandibular fracture, Alveolar osteitis (dry socket), bleeding, trismus or edema along with demographic features and the type of impaction were noted. The data was arranged in a tabulated form and analyzed using SPSS software. The variables were analyzed and P value of less than 0.05 was considered significant.

Result: There were 117 males and 113 females who underwent transalveolar extraction of third molar. The mean age of females was 47.21 +/- 12.2 years and males were 48.32 +/- 11.5 years. In our study pain was the most commonly encountered complication, seen in 57.4% of the subjects. Pain was followed by swelling which was seen in 42.2% of the subjects. Trismus ranked third, seen in 23.2% of subjects. There was a significant difference in pain levels amongst the three age groups in which pain most frequently seen in less than years of age 20 (21.6%) and least frequently seen amongst 20-40 years of age (15.2%).

Conclusion: Pain was the most common complication followed by swelling and Trismus.

Keywords: Pain, Paresthesia, Swelling, Trismus, Wisdom

Introduction

Third molar removal is one of the most routinely performed procedures by Oral and Maxillofacial surgeon and one of the most feared dental procedures. Good planning and skills, during preoperative diagnosis intraoperative treatment and postoperative management is required.⁽¹⁾ Various factors such as patient's age, surgical technique, habits like smoking or drinking alcohol, gender, position of tooth etc influence the type of complication.⁽²⁾ Complication can range from minor to severe discomfort that can lead to permanent damage or sometimes even require hospitalization.⁽³⁾ Complications associated with surgical removal of third molar are alveolitis, dry socket, infection, paresthesia of the inferior alveolar nerve, haemorrhage, persistent pain, swelling and edema. Some of the less common complications are trismus, iatrogenic damage to adjacent tooth, temporomandibular joint injury and iatrogenic mandibular fracture.^(4,5,6)

Age of patient and the position of the tooth most directly affect the complication rate.⁽⁷⁾ Some author's have shown mesioangular and distoangular impactions have double the chances of complication than any other tooth position.⁽⁸⁾ According to Mercier et al⁽⁹⁾ and Tetsch et al,⁽¹⁰⁾ the chances of intraoperative and postoperative complications are three times more in mandible compared to maxilla this is due the fact that poor blood

circulation, more retention of saliva and food particles leading to difficulty in maintaining oral hygiene in mandible. It has also been observed that as the age advances the incidence of complication also increases, this may be due to increase in bone density and complete root formation therefore more abnormality in root curvature leading to difficulty in extraction.⁽¹¹⁾ The most commonly encountered complications are pain, paresthesia, trismus, swelling and mandibular fracture.⁽¹²⁻¹⁴⁾

The aim of this study was to evaluate and estimate the incidence of complication associated with removal of impacted third molar in Bilaspur area.

Materials and Method

This study was conducted in the Department of Oral & Maxillofacial Surgery Triveni Institute of Dental Sciences & Research Center, Bilaspur. All the cases of surgical removal of third molar which were performed in the Department of Oral and Maxillofacial surgery during a period of 1 year from April 2016 - March 2017 were retrospectively analysed and included in the study, 310 cases of surgical removal of mandibular third molar were included. All the data from the patient's document were reviewed and sorted as per the variables included in the study.

The demographic data like age, sex, address and socioeconomic status was noted, medical history was also collected. The study was approved by the Institutional Ethical committee. All the cases assessed had a history of medications, one hour pre operatively of tablet Augmentin 625 mg as standard antibiotic and Ketorolac tromethamine 10mg as analgesic agent, post-operatively Augmentin 625 mg was given for 4 days and Ketorolac tromethamine dosage was prescribed as and when required basis. Radiographs like Ortho Pantomo Graph (OPG), Intra oral peri-apical radiographs and Cone Beam Computed Tomography had been carried out as per the requirement and all the surgical instruments were sterilised by autoclaving prior to the procedure. The type of impaction, presence of post operative complications like pain (more than 3 days), paresthasias (lips or tongue), mandibular fracture, alveolar osteitis (dry socket), bleeding, trismus or edema had been noted. Pain was recorded by VAS (Visual analogue scale). Slight pain after 3rd day was not taken into consideration. All the reported complications were addressed at the earliest possible and managed accordingly. All the patient details were entered in a predefined form. The data was arranged in a tabulated form and analyzed using SPSS software. The variables were analyzed and P value of less than 0.05 was considered significant.

Result

In this study, a total of 230 subjects were enrolled in which 310 mandibular third molar surgeries were

performed. Both unilateral and bilateral impactions were included. There were 117 males and 113 females who underwent transalveolar extraction of third molar. The mean age of females was 47.21+/- 12.2 years and males were 48.32 +/- 11.5 years.

Table 1 and Fig. 1 shows the most frequently encountered complications and the percentage of each complication. In our study pain was the most commonly encountered complication even after the administration of analgesics, seen in 57.4% of the subjects. Pain was followed by swelling for a period of 3 days which was seen in 42.2% of the subjects. Trismus ranked third, seen in 23.2% of subjects. Mandibular fracture was the least common complication following removal of wisdom teeth, seen only in 0.3% of the subjects. Transient paresthasia (lip or tongue) was seen in 7.3% of the subjects with a follow up to 3 weeks.

Table 1: Incidence of complications after third molar surgery

	Complication	Incidence (n=310)	Percentage
1	Pain	178	57.4
2	Paresthasia	22	7.3
3	Mandibular fracture	1	0.3
4	Alveolar Osteitis	39	12.5
5	Bleeding	7	2.2
6	Swelling	131	42.2
7	Trismus	72	23.2

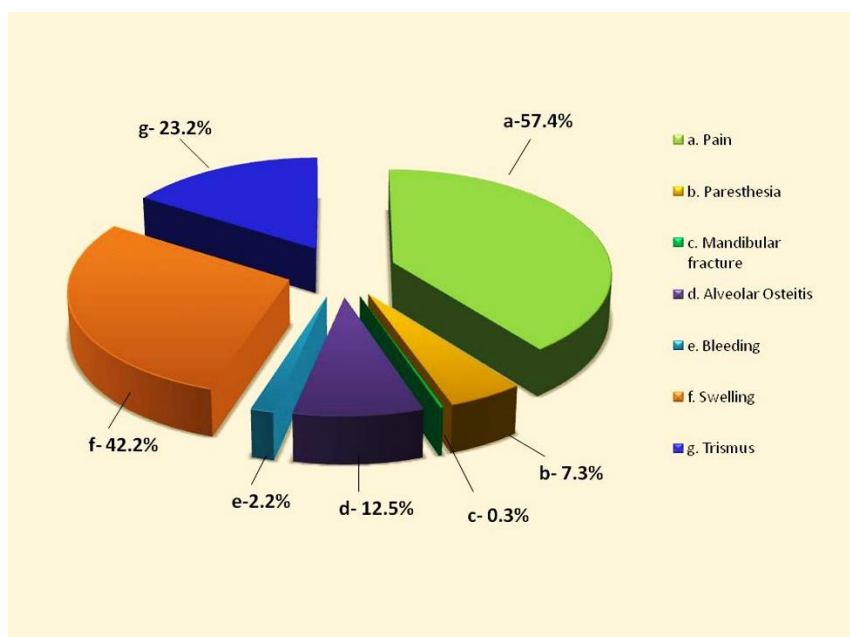


Fig. 1: Incidence of complications after third molar surgery

In our study there was a significant difference in pain levels amongst the three age groups in which pain was most frequently seen in age group less than 20 years (21.6%), followed by age group more than 40 years (20.6%) and least frequently seen amongst 20-40 years of age (15.2%). There was a single case of mandibular fracture, seen in a patient

more than age group of 40 years. Swelling was seen in 18.7% of subjects who were less than 20 years of age, 10.6% subjects between the age of 20-40years and 12.9% in subjects who were more than 40 years of age. There was no significant difference in the Trismus index and swelling as seen in Table 2 and Fig. 2.

Table 2: Incidence of complications in different age groups

	Complication	Less than 20 years	20-40 years	Greater than 40 years	P value
1	Pain	67(21.6%)	47(15.2%)	64(20.6%)	<0.05
2	Paresthesia	5(1.6%)	7(2.2%)	10(3.2%)	>0.05
3	Mandibular fracture	0	0	1(0.3%)	>0.05
4	Alveolar Osteitis	8(2.5%)	13(4.1%)	18(5.8%)	>0.05
5	Bleeding	3(0.9%)	2(0.6%)	2(0.6%)	>0.05
6	Swelling	58(18.7%)	33(10.6%)	40(12.9%)	>0.05
7	Trismus	32(10.3%)	13(4.1%)	27(8.7%)	>0.05

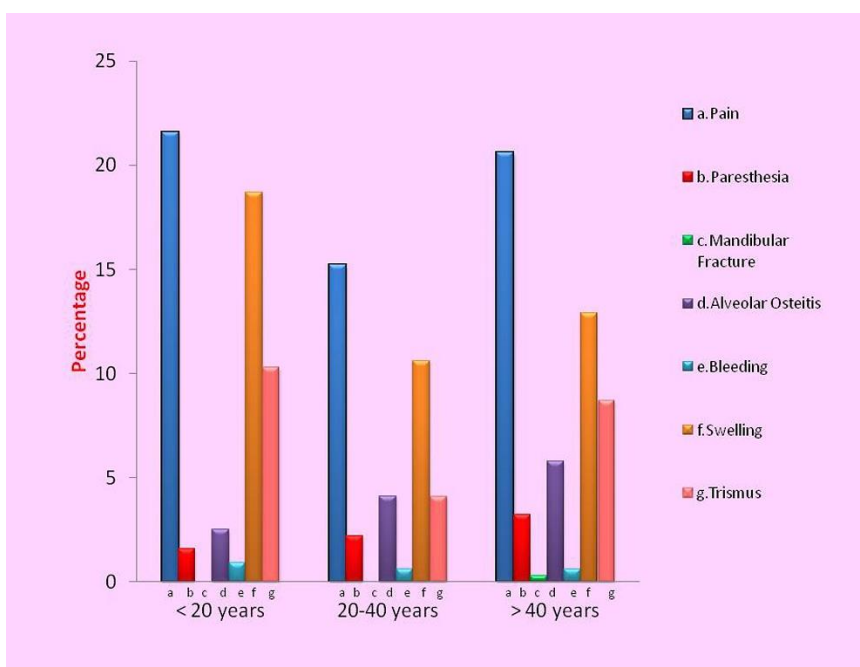


Fig. 2: Incidence of complications in different age groups

Table 3 and Fig. 3 shows the percentage of most common type of impactions among the study group that is Mesioangular impaction 59.03% (183 impactions) followed by Horizontal 19.67% (61 impactions), Vertical impaction 11.61% (36 impactions), and Distoangular 9.67% (30 impactions).

Table 3: Type of Impaction

Type of impaction	N	%
Mesioangular	183	59.03%
Vertical	36	11.61%
Horizontal	61	19.67%
Distoangular	30	9.67%
Total	310	

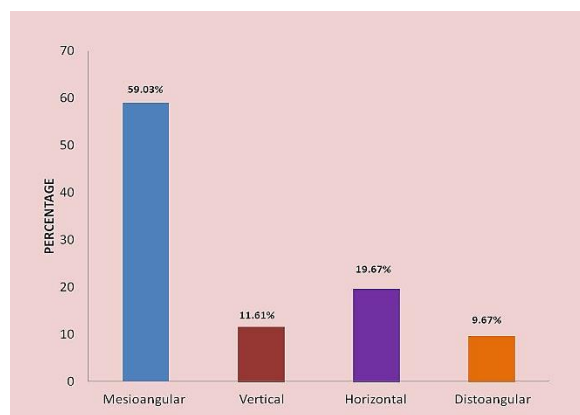


Fig. 3: Type of Impaction among the study group

Discussion

Third molar also known as wisdom teeth are the last teeth to develop in the human jaw. These teeth are most

frequently impacted because of lack of space. A practitioner should have the complete understanding and knowledge about the complication so that he is able to identify and isolate the high risk group and manage any kind of complication and also should assess complete information from the investigations such as Ortho Pantomo Graph (OPG) for determining height of mandible, Intra oral peri-apical radiographs (for determining better angulation of impacted teeth) and Cone Beam Computed Tomography (for 3 dimensional imaging of nerve relation to impacted tooth and its root) and other Blood investigation for determining the glycemic status along with Bleeding and Clotting time which will reduce the associated post operative bleeding and healing complications. It has been seen that wisdom tooth complications generally occur between the ages of 18 to 25 years.⁽⁸⁾ Incidence of complication following the removal of third molar has been reported between 2.6% to 30.9%. Pain and swelling are one of the frequent and unpleasant complications. This is generally due to following mechanism, extraction of teeth leads to injury to cell wall and inflammatory changes in periodontium,⁽¹⁵⁻¹⁷⁾ which leads to conversion of phospholipids into prostaglandins and thromboxane and which in turn cause pain and swelling.⁽¹⁸⁾ Trismus is seen as a result of trauma and inflammation of the muscles of mastication⁽¹⁹⁾ and was difficult to manage without mouth opening exercises. Swelling is maximum during 2-3 days and subsides after 7 days.⁽²⁰⁾ Alveolar osteitis is another major complication in which the patient complains of severe throbbing pain 3-5 days after extraction.⁽¹⁸⁾ The incidence of Alveolar osteitis varies between 1%-30%.⁽²²⁾

In a study by Valmaseda et al⁽²³⁾ the overall incidence of complication after third molar removal was 10%. Study conducted by Avendano et al⁽²⁴⁾ showed the overall complication rate was 15.62% and the most frequent complication was pain and its overall incidence was 57.3%, which is concurrent with present study with the incidence of 57.4%. In a study conducted by Khalesiet al⁽²⁵⁾ the incidence of pain was 28% after third molar surgery. Benediktsdottir et al⁽²⁶⁾ showed mild pain in 53% cases, severe pain in 47% cases and there were 15.2% cases who had severe pain even a week after surgery. In a study by Capuzzip et al,⁽²⁷⁾ the most frequent complication after wisdom tooth removal was pain, inflammation and Trismus which is similar to our study.

In our study there was 1(0.3%) patient with mandibular fracture which is similar to study by Krimmel M et al.⁽²⁸⁾ where mandibular fracture was one of the reported complications but the incidence was low. Another study by Khalesi et al⁽²⁵⁾ showed the incidence of mandibular fracture was 0.4%. Similar trends have been reported in various other studies.⁽²⁹⁾ The type of impaction gives a prediction of the difficulty of extraction and hence the severity of postoperative tissue reactions. In this study the commonest type of impaction,

was Mesioangular impaction followed by Horizontal, Vertical and Distoangular impactions and is similar to the reports from earlier studies.^(30,31)

Therefore it is mandatory to assess the operative difficulties and to assess the incidence and chances of implications such that they can be avoided.

Conclusion

In conclusion some of the complications are bound to occur after removal of wisdom teeth. A detailed dental and medical history with advanced imaging modalities, gentle surgical techniques with minimal to no damage to adjacent normal structures and strict sterilisation methods are key factors involved in minimising the complications arising during and after surgical removal of impacted teeth. Pain was the most common complication followed by swelling and Trismus.

References

1. Susarla SM, Dodson TB. Risk factors for third molar extraction difficulty. *J Oral Maxillofac Surg.* 2004;62:1363-71.
2. Azenha MR, Kato RB, Bueno RBL, Neto PJO, Ribeiro MC. Accidents and complications associated to third molar surgeries performed by dentistry students. *Oral Maxillofac Surg.* 2014 Dec;18(4):459-464.
3. Song F, Landes DP, Glenney AM, Sheldon TA. Prophylactic removal of impacted third molars: an assessment of published reviews. *Br Dent J.* 1997;182:339-46.
4. Contar C, De Oliveira P, Kanegusuku K, Berticelli R, Azevero – Alanis L, Machado M. Complications in third molar removal: a retrospective study of 588 patients. *Med Oral Patol Oral Cir Bucal* 2010;15: 74-78.
5. Woldenberg Y, Gatot I, Bodner L. Iatrogenic mandibular fracture associated with third molar removal. Can it be prevented. *Med Oral Patol Oral Cir Bucal* 2007; 12: 70-72.
6. Blondeau F. Extraction of Impacted Mandibular Third Molar: Postoperative complication and their risk factors. *JCDA* 2007;73(4):325a-325e.
7. Miloro M, Ghali GE, Larsen PE, Waite PD. Peterson's principles of oral and maxillofacial surgery Vol I, 3rd ed (Special Indian Edition). New Delhi: CBS; Publishers & Distributors Pvt Ltd, 2012.P 107.
8. Blondeau F, Daniel NG. Extraction of impacted mandibular third molars: postoperative complications and their risk factors. *J Can Dent Assoc.* 2007 May;73(4):325.
9. Mercier P, Precious D: Risks and benefits of Removal of impacted third molars. A critical review of the literature. *Int J Oral Maxillofac Surg.* 21: 17–27.
10. Tetsch P, Wagner W: Die operative Weisheitszahnentfernung. Carl Hansen Verlag, Munchen Wien. *Swiss Dental Journal.* 2014 Vol 124 (10):1047.
11. Deliverska EG, Petkova M. Complications after extraction of impacted third molars- literature review. *J of IMAB.* 2016 Jul-Sep;22(3):1202-1211.
12. Goldberg M, Nemarich A, Marco 2nd W. Complications after mandibular third molar surgery: a statistical analysis of 500 consecutive procedures in private practice. *J Am Dent Assoc.* 1985, 111:277-279.
13. Christiaens I, Reyckler H. Complications after third molar extractions: retrospective analysis of 1,213 teeth. *Rev Stomatol Chir Maxillofac.* 2002, 103:269-274.
14. Trybek G, Chrusciel-Nogalska M, Machnio M et al. Surgical extraction of impacted teeth in elderly patients. A

- retrospective analysis of perioperative complications - the experience of a single institution. *Gerodontology*. 2015. doi: 10.1111/ger.12182.
15. Hargreaves K, Abbott P. Drugs for pain management in dentistry. *Aust Dent J*. 2005, 50(4 Suppl 2): S14-S22.
 16. Singla NK, Desjardins PJ, Chang PD. A comparison of the clinical and experimental characteristics of four acute surgical pain models: Dental extraction, bunionectomy, joint replacement, and soft tissue surgery. *Pain*. 2014, 155:441-456.
 17. Rashwan WA. The efficacy of acetaminophen-caffeine compared to Ibuprofen in the control of postoperative pain after periodontal surgery: a crossover pilot study. *J Periodontol*. 2009, 80:945-952.
 18. Haas DA. An update on analgesics for the management of acute postoperative dental pain. *J Can Dent Assoc*. 2002, 68:476-482.
 19. Peterson LJ, Ellis E, Hupp JR, Tucker MR. Contemporary oral and maxillofacial surgery. In: Peterson LJ. Postoperative patient management. 4th ed. United States of America: Linda Duncan; 2003. p.219.
 20. Peterson LJ. Postoperative patient management. In: Peterson LJ, Ellis III E, Hupp JR, et al, editors. Contemporary oral and maxillofacial surgery. 3rd edition. New York: Mosby; 1998. p. 249– 56.
 21. Larsen PE. Alveolar osteitis after surgical removal of impacted mandibular third molars: identification of the patient at risk. *Oral Surg Oral Med Oral Pathol* 1992; 73:393–7.
 22. Catellani JE, Harvey S, Erickson S, et al. Effect of oral contraceptive cycle on dry socket (localized alveolar osteitis). *J Am Dent Assoc* 1980;101:777– 80.
 23. Valmaseda-Castellon E, Berini-Aytes L, Gay- Escoda C. Inferior alveolar nerve damage after lower third molar surgical extraction: a prospective study of 1117 surgical extractions. *Oral Surg Oral Med Oral Pathol Oral Radiol Endod* 2001; 92(4): 377-83.
 24. Avendano, AV. Garcia, SP. Castellon, EV. Leonardo Berini Aytes, Cosme Gay Escoda. Morbidity of third molar extraction in patient between 12 and 18 years of age. *Med Oral Pathol Pral Cir Bucal* 2005; 10: 422-31.
 25. Azam AN, Ezoddini F, Khalesi M, Gholami L, Momtaz A. Evaluation of the complications after mandibular third molar surgical extraction. *Avicenna Journal of Dental Research*.;2(2):29-34.
 26. Benediktsdóttir I, Wenzel A, Petersen J *et al*. Mandibular -third molar removal: risk indicators for extended operation time, postoperative pain, and complications. *Oral Surg Oral Med Oral Pathol Oral Radiol Endod*. 2004, 97:438-446
 27. Sittitavornwong, S. Peter D. Waite, John D. Holmes, Josbua C. Kalpow. The necessity of routine clinic follow-up visits after third molar removal. *J Oral Maxillofac Surg* 2005; 63: 1278-1282.
 28. Osborn TP, Frederickson G Jr, Small IA, Torgerson TS. A prospective study of complications related to mandibular third molar surgery. *J Oral Maxillofac Surg* 1985; 43(10): 767-9.
 29. Krimmel M, Reinert S. Mandibular fracture after third molar removal. *J Oral Maxillofac Surg* 2000; 58:1110– 2.
 30. Quek SL, Tay CK, Tay KH, Toh SL, Lim KC. Pattern of third molar impaction in a Singapore Chinese population: a retrospective radiographic survey. *Int J Oral Maxillofac Surg*. 2003 Oct;32(5):548-52.
 31. Saheeb, B.D.O. and Obuekwe, O.N. (2001). An audit of mandibular third molar. *Nigerian Journal of Surgical Research*, 3, 66-74.