

Occurrence of Oral Mucosal Changes among the Smokeless Tobacco Users in Patients Visiting Saveetha Dental College

Shamara Aysha^{1,*}, T.N.Uma Maheswari²

¹Final year BDS student, Saveetha Dental College, Saveetha University, Chennai

²Professor, Department of Oral Medicine and Radiology, Saveetha Dental College, Saveetha University, Chennai

***Corresponding Author:**

Email: shamava.shayahan@gmail.com

ABSTRACT

Background: Smoking and smokeless tobacco products are commonly used by the Indian population and both are considered to be predisposing factors for oral carcinoma. There are many oral mucosal lesions which are observed before the development of oral carcinoma such as chewer's mucosa, lichenoid reaction, tobacco pouch keratosis, leukoplakia, oral sub mucous fibrosis, etc.

Aim and Objective: To evaluate all the oral mucosal changes caused by various types of smokeless tobacco products and to find out the commonly used smokeless tobacco and commonly associated oral manifestations.

Materials and Methodology: A total of 140 subjects (114 males and 26 females) were included in the study. A proforma was prepared to document their demographic and clinical examination findings.

Result: Among the 140 subjects, 114 subjects showed oral mucosal changes and 26 subjects showed no mucosal changes. Hans being the most commonly used smokeless tobacco product followed by Guthka and then Mawa. Hans is the common smokeless tobacco product which is more associated with the oral mucosal changes. The most commonly caused oral mucosal change according to the analysis is oral sub mucous fibrosis followed by tobacco pouch keratosis, leukoplakia, chewers mucosa.

Key words: Smokeless Tobacco, Mawa, Hans, Guthka, Burley tobacco leaf, Pan masala, Leukoplakia, Oral Sub-mucous Fibrosis

INTRODUCTION

Tobacco usage is a common habit among Indians since ancient times. There are two forms of tobacco products, smoke tobacco and smokeless tobacco. Smokeless tobacco is more carcinogenic than smoking tobacco (1). The smokeless tobacco products that are commonly found in south Indian population are mishri, bazaar, snuff, betel quid, mainpuri, khaini, mawa, guthka, zarda, hans, pan masala (2). The most commonly used smokeless tobacco among the subjects included in this study was hans, mawa, guthka, pan, burley tobacco leaf.

AIM

To find out the occurrence of oral mucosal changes among smokeless tobacco users in patients visiting Saveetha Dental College.

OBJECTIVE

1. To evaluate the most commonly used smokeless tobacco product among the patients visiting Saveetha Dental College.
2. To find out which of the smokeless tobacco product is more associated with oral mucosal lesions
3. To find out which type of mucosal lesion is more commonly associated with smokeless tobacco.

MATERIAL AND METHODOLOGY

Among the patients who came to Saveetha Dental Hospital, Chennai for dental treatments, 140

subjects who use smokeless tobacco products were taken for the study out of which 126 were males and 14 were females. A proforma was made to collect all the demographic data from the subjects. Intra oral examination was performed with sterilized diagnostic instruments. Complete information on the duration, pattern and frequency of usage, site of placement and intra-oral mucosal changes were recorded. The study was done for a period of three months starting from 1st march to may 31st 2015. Anti-tobacco counselling was given to all patients and patients who had mucosal changes were either prescribed medications or were subjected to biopsy to assess dysplasia depending on the severity of the oral mucosal change.

RESULTS

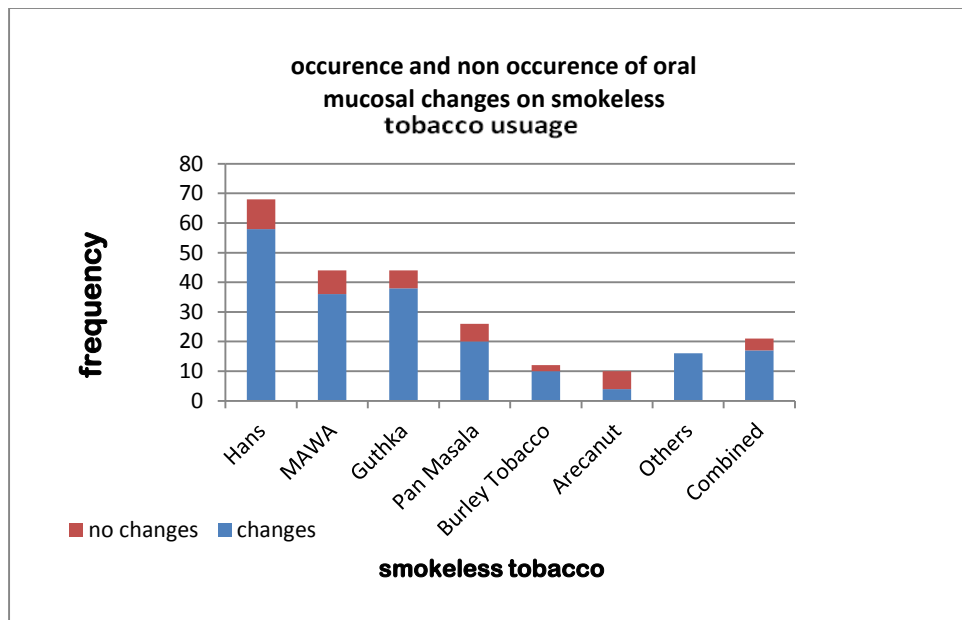
According to the analysed data, among the 126 males, 4 men under the age group of 10-20 years, 78 men under the age group of 21-39 years, 36 men under the age group of 40-59 years and 6 men above 60 years had oral mucosal changes. Among the 14 females, 2 women under the age group of 21-39, 8 women under the age group of 40-59 and 4 women above 60 years had oral mucosal changes. Among the 140 subjects, 114 subjects showed oral mucosal changes and 26 subjects showed no mucosal changes. Hans being the most commonly used smokeless tobacco product followed by Guthka, Mawa, Pan, combined tobacco products, Burley tobacco leaf and others (graph 1). The most commonly caused oral mucosal change according to the analysis as oral sub mucous fibrosis followed by Tobacco Pouch

Keratosis, Leukoplakia, Chewers mucosa, Lichenoid reaction and Carcinoma (graph 2). According to this analysis, (graph 3)

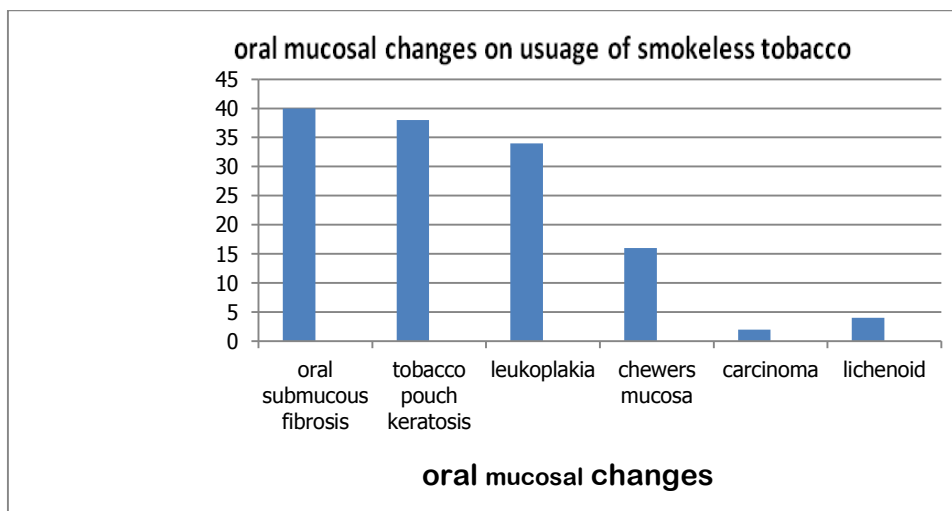
- 1) Chewers mucosa was most commonly caused by Hans (n=10) followed by Mawa (n=4), Pan Masala (n=4).
- 2) Lichenoid reaction was commonly caused by Hans (n=4) and second commonly by Mawa (n=2).
- 3) Leukoplakia was most commonly caused by Mawa (n=10) and Guthka (n=10) followed by Hans (n=8) and burley tobacco leaf (n=8), pan (n=4) and others (n=2)
- 4) Tobacco Pouch Keratosis was commonly caused by Hans (n=26) followed by Mawa (n=8), Guthka (n=6) and others (n=6).

- 5) Oral sub mucous fibrosis was commonly caused by Guthka (n=20), Mawa (n=12), Hans (n=10), Pan Masala (n=10).
- 6) In the current study, among the 140 subjects using smokeless tobacco, we had come across to male patients with oral carcinoma (carcinoma of tongue and carcinoma of buccal mucosa ho had been using Guthka).

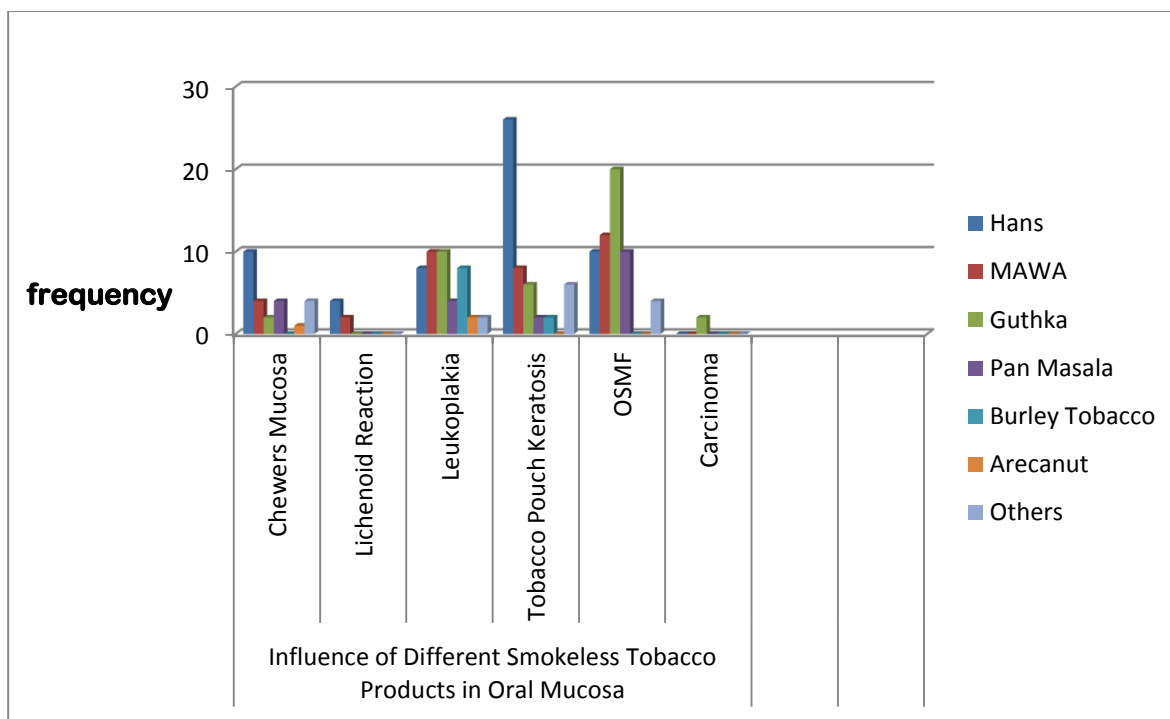
Among the 26 subjects who showed no mucosal changes, 2 subjects used Hans, 4 subjects used Mawa, 2 subjects used Guthka, 2 subjects used Pan masala, 2 subjects used Burley leaf, 2 subjects used Arecanut and 12 used a combination of few of the above products. These subjects were either occasional users of smokeless tobacco or gave a history of short duration on usage of smokeless tobacco.(Graph 1)



Graph 1



Graph 2



Graph 3

DISCUSSION

Based on our study, the prevalence of oral mucosal lesions was more in the group of 21 to 39 years old age group for males. In another study conducted by Prashanth, subjects aged 15-24 years had the most number of oral mucosal changes with the percentage of 27.1% (6). This finding also coincides with Wray and Guirt study (7) that reported the middle-aged are the biggest group of snuff users.

In India, traditional values do not favour smoking by the young or by women, but there is no such rule against the use of smokeless tobacco by women. Hence most women use tobacco in smokeless forms (2). Based on our study of among the 140 subjects who used smokeless tobacco products, 90% were males and 10% were females. In another study, it states that 60% of the males and 40% of the females used smokeless tobacco products (3). According to the data analysed in our study, the most common oral mucosal change associated with smokeless tobacco is oral sub mucous fibrosis. Tobacco pouch keratosis and leukoplakia were the second and third most common lesion. In another study among 55 subjects, OSMF was the most frequently encountered lesion (27.3%) and is coincides with the findings of Saraswathi et al., and Yang et al., [4,5], Pan-chewer's lesion (21.8%) and Tobacco pouch keratosis (16.4%) were the second and third most common lesions.

According to a study, tobacco chewing has been shown to demonstrate adverse effects on lipid profile and may increase cardiovascular risk (8). Certain studies from India that was conducted on pregnant women who use smokeless tobacco have

shown an increase in stillbirths (9) and a 100–400 g decrease in birthweight, in offsprings (9,10). Some studies state that betel quid chewers (with or without tobacco) who have asthma may find their condition aggravated due to the action of arecoline (contraction of bronchiolar smooth muscle) from areca nut (11). In current study, there were no significant association between systemic diseases and use of smokeless tobacco. In 140 subjects, 39 subjects has systemic diseases and the most common systemic diseases were diabetes mellitus, hypertension which is also seen commonly in people who are not using tobacco. However future studies should concentrate to find any impact on systemic health from tobacco associated oral lesions as few studies have proved the significant association between tobacco usage and systemic diseases.

REFERENCE:

1. Mohamed Anser S¹, Aswath N : Comparison of the Carcinogenic Potential of Smokeless Tobacco and Smoked Tobacco by Quantifying the Excretion of Nicotine Metabolite NNAL in Patients with Oral Leukoplakia. *Indian J Clin Biochem.* 2014 Apr; 29(2):246-9. doi: 10.1007/s12291-013-0363-7. Epub 2013 Jul 23.
2. PRAKASH C GUPTA, CECILY STEWART RAY: Smokeless tobacco and health in India and South Asia
3. Smokeless Tobacco Use in India: Effects on Oral Mucosa P.R. Murti, P.C. Gupta, R.B. Bhonsle, D.K. Daftary, F.S. Mehta, and J.J. Pindborg
4. TR Saraswathi, K Ranganathan, S Shanmugam, S Ramesh, PD Narasimhan, R Gunaseelan. Prevalence of oral lesions in relation to habits: Cross-sectional study in

- South India. *Ind J Dent Res.* 2006; 17(3):121–25. [PubMed]
5. YH Yang, YC Lien, PS Ho, CH Chen, JS Chang, TC Cheng. The effects of chewing areca/betel quid with and without cigarette smoking on oral submucous fibrosis and oral mucosal lesions. *Oral Dis.* 2005;11(2):88–94. [PubMed]
 6. Prashant B. Patil, Renuka Bathi, ¹ and Smitha Chaudhari. Prevalence of oral mucosal lesions in dental patients with tobacco smoking, chewing, and mixed habits: A cross-sectional study in South India. *Family Community Med.* 2013 May-Aug; 20(2): 130–135.
 7. Wray A, McGuirt WF. Smokeless tobacco usage associated with oral carcinoma. Incidence, treatment, outcome. *Arch Otolaryngol Head Neck Surg.* 1993; 119: 929–933. [PubMed]
 8. Khurana M, Sharma D, Khandelwal PD. Lipid profile in smokers and tobacco chewers—a comparative study. *J. Assoc Physicians India* 2000; **48**: 895–7.
 9. Krishna K. Tobacco chewing in pregnancy. *Br. J. Obstet. Gynaecol.* 1978; **85**: 726–8.
 10. Verma RC, Chansoriya M, Kaul KK. Effect of tobacco chewing by mothers on fetal outcome. *Indian Pediatr.* 1983; **20**: 105–11
 11. Nelson BS, Heischouer B. Betel nut. A common drug used by naturalized citizens from India, Far East Asia, and the South Pacific Islands. *Ann. Emerg. Med.* 1999; **34**: 238–43.