

# Infected Nasolabial cyst: A Rare Case Report and Review of Literature

Sharry Goyal<sup>1</sup>, Pradhuman Verma<sup>2</sup>, Mayank Mehta<sup>3</sup>, Amit Ladgotra<sup>4</sup>

<sup>1</sup>P.G Student, <sup>2</sup>Reader, <sup>3,4</sup>PG Student, Department of Oral Medicine & Radiology, Surendera Dental College & Research Institute, Sriganaganagar – 335001, Rajasthan

\*Corresponding Author:

Email: pradhuman\_verma@rediffmail.com

## ABSTRACT:

*The nasolabial cysts (NAC) are uncommon, developmental, non-odontogenic soft tissue cysts that are formed in the lower region of the nasal ala. According to most authors, they originate from trapped epithelium in line of fusion of the globular, lateral nasal and maxillary processes, due to atypical changes in entrapped epithelium along the fusion line during development process. These lesions are predominantly unilateral; grows slowly and size usually ranges between 1.5 and 3 cm. Clinically, they may be characterized as a floating tumefaction in the nasolabial sulcus, which leads to elevation of upper lip. They may result in esthetic problems so are diagnosed earlier. The preferred treatment modality is surgical excision. Here we present a rare case of Infected Nasolabial cyst reported in 10 years old male patient.*

**Keywords:** Developmental, Nasolabial cysts, Non Odontogenic

## INTRODUCTION

NAC are developmental, non-odontogenic, soft tissue lesions which account for 0.7% of all jaw cysts. In 1882, these were first reported by Zuckerkandl.<sup>1-3</sup> In 1989 these lesions were described in greater detail by Brown-Kelly while the first case itself was reported by McBride in 1892. These lesions were then termed after the name of Klestadt who investigated NAC in depth.<sup>4,5</sup> The origin of NAC is somewhat controversial. It is thought that it is formed between the 4th and 8th weeks of intra-uterine life; when the base of nose & nasal alae are developed from the maxillary process of the second brachial arch and the hard palate is formed by the midline fusion between each maxillary lateral palatine process and the base of the septum, at the same time initiating formation of the nasal fossa. Atypical variations at any of these fusion points may give origin to a fissure cyst.<sup>6</sup> But the most recent and widely accepted theory is that it originates from the inferior and anterior portion of the nasolacrimal duct.<sup>7-9</sup> NAC usually affect women in 75% of cases and predominantly affecting patients in the fourth and fifth decades of life.<sup>9,10</sup> These lesions are usually unilateral in 90% of cases and are bilateral in rest 10% of cases. The characteristic clinical features may include local pain, nasal block, and may lead to tumefaction with significant inflammation and infection; a floating mass in the nasolabial sulcus area that involves the nasal alae, extending to the ventral-inferior portion of the pyriform margin.<sup>11-13</sup> The pathologies that may be considered in differential diagnosis of NAC include odontogenic cysts, periapical abscesses & granulomas in maxillary anterior teeth region; dermoid & epidermoid cysts. The pulp vitality testing of the regional teeth is important for proper diagnosis, as the teeth will be

vital in cases of NAC & non-vital in case of odontogenic lesions. The dermoid and epidermoid cysts may be associated with yellow discoloration of the overlying mucosa, whereas in NAC, the mucosa retains its normal pink hue.<sup>14</sup> On periapical radiographs, they may present as a radiolucent area in the apical region of the maxillary incisors. The standard occlusal views show posterior displacement of the radiopaque line respective to the bony margins of the anterior nasal aperture. Computed tomography is the imaging modality of choice when a definite analysis of the lesion is required.<sup>15-17</sup> The histopathology of this lesion was described by Brown Kelly in 1898 according to whom the cyst is composed of respiratory epithelium (pseudostratified or stratified ciliated cylindrical epithelium), although in cases of infected cysts squamous metaplasia may occur. Fluid contained within cysts is produced by goblet cells.<sup>17,18,19</sup> The diagnosis of NAC is essentially clinical.

The present case report aims to describe in detail the clinical presentation, diagnosis and surgical treatment of NAC.

## CASE REPORT

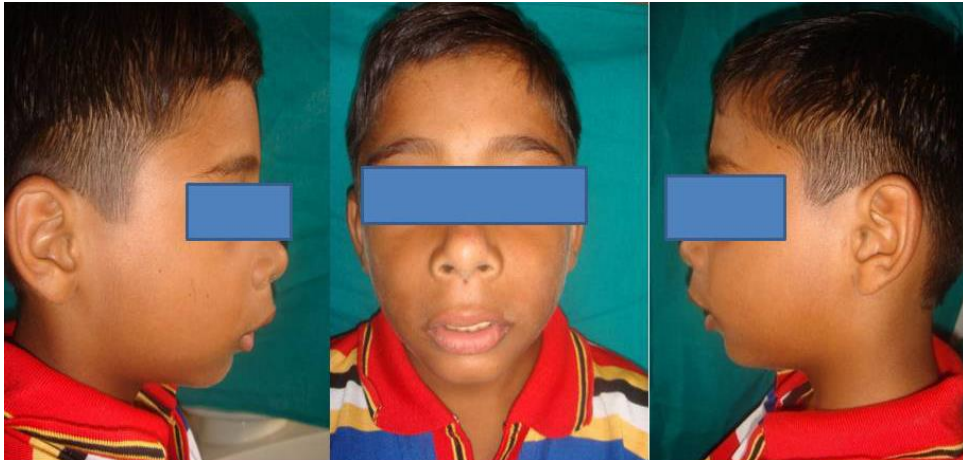A 10 year old male patient reported to the department of Oral Medicine & Maxillo-facial Radiology with the chief complaint of creamish discharge in upper front teeth region since 1 month & swelling on middle third of face since 10 days. History of presenting illness revealed swelling on inner aspect of lip since birth raising the upper lip after which patient consulted the local dentist and symptoms relieved on medication but didn't get complete treatment; again it aggravated 1 month back when patient noticed creamish discharge from an extra oral sinus in region of philtrum which was

somewhat healed now and swelling on labial mucosa aggravated 10 days back. There was no history of trauma, fever or similar swelling elsewhere in the body with positive history of nasal discharge. The extraoral examination revealed a diffuse swelling present on middle third of face causing obliteration of both nasolabial folds & philtrum with extraoral sinus in upper part of philtrum. (**Figures: 1&2**)

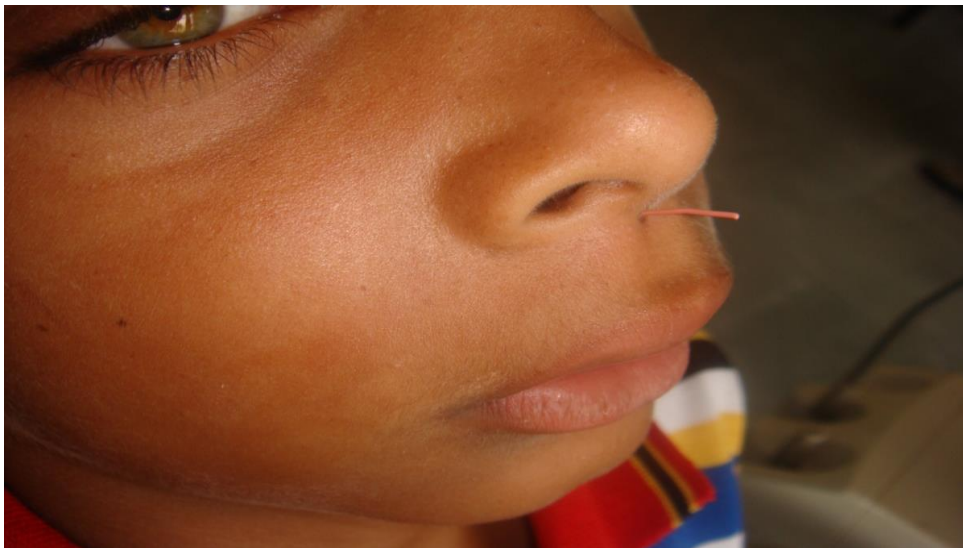Intraoral Examination revealed a solitary well defined, oval shaped yellowish colored swelling present on upper labial mucosa irt 11, 21 region with obliteration of vestibular region; On palpation, it was soft , fluctuant & tender(**Figure:3**). Hard tissue Examination did not reveal any significant findings. Based upon history & clinical findings, Provisional Diagnosis of Infected developmental cystic lesion was made and the differential diagnosis of benign

minor salivary gland pathology, nasal abscess, nasopalatine duct cyst, periapical inflammatory lesions & dermoid cyst were considered. The electric pulp vitality tests were done irt 11, 12, 21 & 22 which showed early response to all teeth. On aspiration, blood tinged creamish discharge was present. (**Figure: 4**). IOPA revealed widening of PDL space around the root of 21 (**Figures: 5 & 6**)

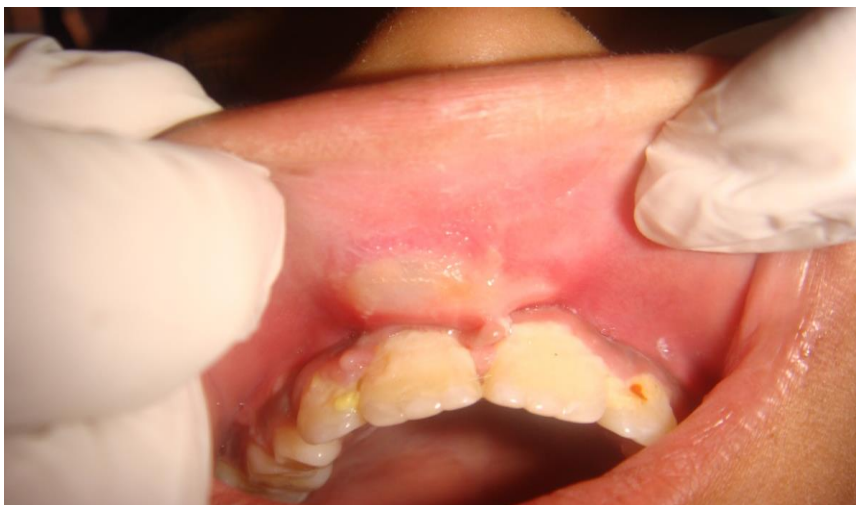The histopathology revealed a cystic lesion with signs of chronic inflammation having a fibrous capsule made up of ciliated pseudo stratified columnar epithelium and the presence of seromucous contents confirming the diagnosis of NAC. The patient was advised surgical resection of the lesion for which the patient was referred to the Department of Pedodontics & preventive dentistry.



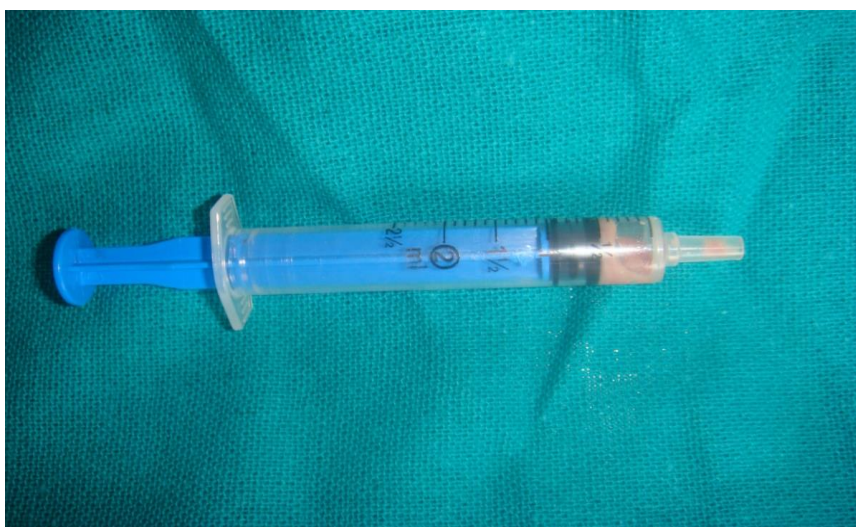**Figure 1: Extraoral photographs showing facial asymmetry**



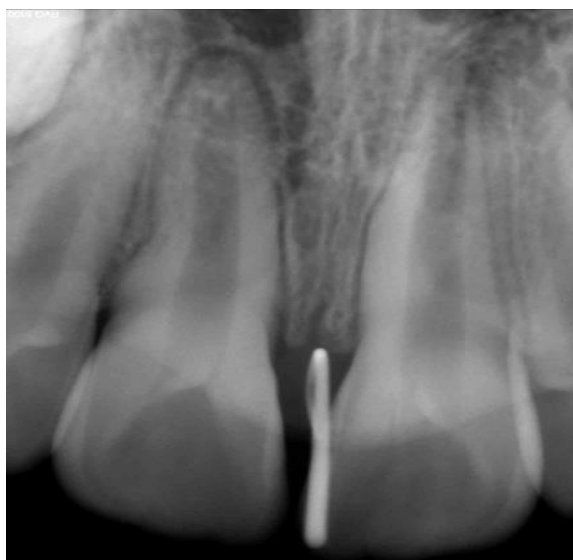**Figure 2: Extraoral photographs with sinus in region of philtrum & obliteration of nasolabial sulcus.**



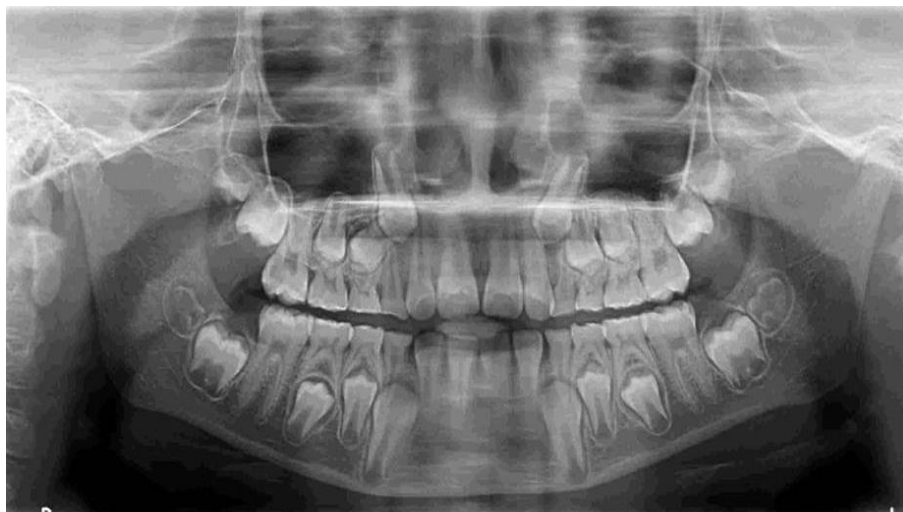
**Figure 3: Intraoral photograph showing cystic lesion.**



**Figure 4: Blood tinged creamish discharge on aspiration**



**Figure 5: Intra-oral periapical radiograph with Gutta percha point**



**Figure 6: Orthopantomograph showing no bony changes.**

## DISCUSSION

This case report demonstrates the features common to those found in patients with NAC. The history & clinical features described earlier were seen in this case, particularly the history of lesion since birth; specific site of lesion and the most marked signs, such as effacement of the nasolabial sulcus and elevation of the ala nasi. The different terms used for NAC are nasal vestibular cyst, mucoid cyst of nose, Klestadt's cyst.<sup>20</sup> These approximately account for 7% of maxillary cysts & are usually unilateral; if unilateral involvement, left side is more commonly involved. Our case is not typical in terms of age & gender as these are found frequently in women in fourth & fifth decades. These are not painful, unless these are secondarily infected; in our case, it is secondarily infected. They may rupture spontaneously and drain nasally. Rarely, they may drain via a cutaneous fistula as in our case. Pulp vitality tests were positive in respective teeth suggestive of non odontogenic causes.<sup>14</sup> They are usually not detected on conventional radiography, as these are soft tissue lesions except in cases where erosive changes of maxilla are seen. The different radiological features are described by various authors. According to Seward, there are two possible radiographic aspects: increased radiolucency adjacent to the apical region of the incisors and deformity of the radiopaque line respective to the inferior border of the piriform aperture. Nixdorf *et al.* confirmed the signs described by Seward with the help of occlusal radiography; whereas counteracting opinion was made by other authors who claim there are no radiographic signs of the NAC. No radiographic abnormalities were even found in our case.<sup>20</sup>

CT, MRI may reveal the cystic nature of these lesions in greater detail about the relationship of the nasal alae with the maxillary bone, as well as

bone involvement but patient was not willing for the same.<sup>20</sup>

Treatment of choice for these cysts is surgical resection. In the literature described upto now; recurrence has not been reported.

## CONCLUSION

Based on the literature and the present case report, it is concluded that, although NACs are rare, dental practitioners should be able to recognize the important and diagnostic features of these lesions so as to separate them from odontogenic lesions and thus enabling safe and proper treatment planning.

## REFERENCES

1. Chinellato LE, Damante JH. Contribution of radiographs to the diagnosis of nasoalveolar cyst. *Oral Surg Oral Med Oral Pathol* 1984; 58:729-735.
2. Wesley RK, Scannell T, Nathan LE. Nasolabial cyst: presentation of a case with a review of the literature. *J Oral Maxillofac Surg* 1984; 42:188-192.
3. El-Din K, El-Hamd AA. Nasolabial cyst: a report of eight cases and a review of the literature. *J Laryngol Otol* 1999; 113:747-749.
4. Brown-Kelly A. Cyst of floor of nose. *J Laryngol Rhinol Otol* 1898; 13:272-76.
5. Klestadt W. Nasal cysts and the facial cleft cyst theory. *Annals Otol Rhinol Laryngol* 1953; 62:84.
6. Robert CB. Cyst lesions of the maxilla. *Laryngoscope* 1970; 308-3.
7. Regezi JA, Sciubba JJ. *Oral pathology: clinical-pathologic correlations*. 2nd ed. Philadelphia: Saunders, WB; 1991.
8. Yuen HW, Julian CL, Samuel CY. Nasolabial cysts: clinical features, diagnosis, and treatment. *J Oral Maxillofac Surg*. 2007; 45:293-7.
9. Shinohara EH, Perin SV, Carvalho Júnior JP. Cisto nasolabial: relato de caso. *BCI*. 2001; 8:15-8.
10. Gomes CC, Dias Jr AB, Vidolin C, Silveira FCA. Cisto nasolabial bilateral. *Rev Bras Otorrinolaringol*. 1995; 61:30-3.
11. Shear GR. Cysts of the jaws. *J Oral Pathol* 1985; 14:43.

12. Gomes CC et al. Cistos Nasolabiais. *Folha Med* 1992; 104(3):69-73.
13. El-Hamd KEAA. Nasolabial Cyst: a report of eight cases and a review of the literature. *J Laryngol Otol* 1999; 113:747-9.
14. Nixdorf DR, Peters E, Lung KE. Clinical presentation and differential diagnosis of nasolabial cyst. *J Can Dent Assoc.* 2003; 69:146–9.
15. Oliveira SB, Castro JL, Silva JJ, Rosa MRD. Cisto nasolabial não odontogênico. *Rev Bras Ciênc Saúde.* 2003; 7:75–8.
16. Seward GR. Nasolabial cysts and their radiology. *Dent Pract.* 1962; 12:154–61.
17. Su CY, Huang HT, Liu HY, Huang CC, Chien CY. Scanning electron microscopic study of the nasolabial cyst: its clinical and embryological implications. *Laryngoscope.* 2006; 116:307–11.
18. Kuriloff DB. The nasolabial cyst-nasal hamartoma. *Otolaryngol Head Neck Surg* 1987; 96:268-72.
19. Burtschi TA, Stout RA. Bilateral nasoalveolar cysts. *Oral Surg* 1963; 16:271-5.
20. Giongo CC, Antonello GM, Couto RT, Torriani MA. Nasolabial cyst: A case report. *Rev Port Eestomatol Med Dent Cir Maxilofac.*2014; 5(1):55–59.