

## Dentigerous cyst of Jaws: Clinico- pathological-imaging correlations of two cases

Asish Rajasekharan<sup>1\*</sup>, Sherin Ann Thomas<sup>2</sup>, Twinkle S Prasad<sup>3</sup>, Anita Balan<sup>4</sup>, Sreedevi P U<sup>5</sup>

<sup>1</sup>Associate Professor and Head, <sup>2</sup>Assistant Professor, <sup>3</sup>Associate Professor, <sup>4</sup>Principal, <sup>5</sup>Senior Resident, <sup>1-3,5</sup>Dept. of Oral Medicine & Radiology, <sup>1,2,5</sup>Government Dental College, Alappuzha, Kerala, <sup>3</sup>Government Dental College, Kottayam, Kerala, Government Dental College Thiruvananthapuram, Kerala, India

**\*Corresponding Author: Asish Rajasekharan**

Email: asishrajasekharan12@gmail.com

### Abstract

Dentigerous cyst is an odontogenic cyst of developmental origin associated with the crown of an impacted, unerupted or partially erupted tooth. It is generally discovered only on routine radiographic examination. It is usually seen as a unilocular, well-defined pericoronal radiolucent area. The cyst cavity is lined by epithelial cells derived from the reduced enamel epithelium of the tooth. This cyst remain initially completely asymptomatic unless when infected secondarily. Here, two cases of dentigerous cyst are discussed.

**Keywords:** Dentigerous cyst, Impacted supernumerary teeth, Reduced enamel, Epithelium, Unilocular.

### Introduction

Dentigerous cyst is a developmental jaw cyst associated with a crown of unerupted/impacted tooth.<sup>1-5</sup> These cysts are most often associated mandibular third molars, maxillary canines, mandibular second premolars and maxillary third molars.<sup>3,4,5</sup> They may also occur around supernumerary teeth and rarely associated with primary teeth.<sup>2-6</sup>

Dentigerous cyst is the second most common type of odontogenic cysts.<sup>1-3</sup> It develops around the crown of unerupted tooth by expansion of its follicle, reduced enamel epithelium and the enamel of an impacted, embedded or unerupted permanent tooth. It is usually seen as a unilocular, well-defined radiolucent area attached to the tooth in the cemento-enamel junction.<sup>2-4</sup> The borders may be scalloped and positioned centrally or laterally on tooth crowns.

Dentigerous cysts are more common in males and frequently occur during second and third decades of life.<sup>2-7</sup> Patients with dentigerous cysts have no painful symptoms unless there is an acute inflammatory exacerbation. Generally are detected only by routine radiographic examination.<sup>5-8</sup> If the cyst reaches a greater size, swelling, mild sensitivity, tooth mobility and displacement may be observed.

The dentigerous cyst is lined by non-keratinized stratified squamous epithelium consisting of myxoid tissue, odontogenic remnants and rarely sebaceous cells.<sup>7-10</sup> The dentigerous cyst develops from follicular epithelium, it has more potential for growth for differentiation and degeneration than a radicular cyst. Occasionally, the wall of a dentigerous cyst may give rise to a mucoepidermoid carcinoma or squamous cell carcinoma.<sup>8-10</sup>

Radiographically dentigerous cysts show a well-defined radiolucency surrounding the crown of an unerupted tooth, which often has a sclerotic border. The usual radiographic appearance is that of a well-demarcated radiolucent lesion attached to the cervical area of an unerupted tooth.<sup>10-14</sup> The border of the lesion may be radiopaque. The radiographic differentiation between a dentigerous cyst and a normal dental follicle is based merely on size. Infected cysts show ill-defined margins. Due to the tendency for dentigerous cysts

to expand rapidly, they may cause pathological fractures of jaw bones.<sup>12-15</sup>

The treatment for a dentigerous cyst is dependent on the size of the lesion. Smaller lesions should be surgically enucleated, avoiding damage to the involved permanent teeth. In case of a large cyst marsupialization is treatment of choice.<sup>8,10,12,15-18</sup>

Possible complications include permanent bony deformity, or pathological fracture from its expansive destruction of bone, loss of essential permanent dentition or its innervations or development of ameloblastoma or mucoepidermoid carcinoma or squamous carcinoma from the epithelial lining of the cyst.

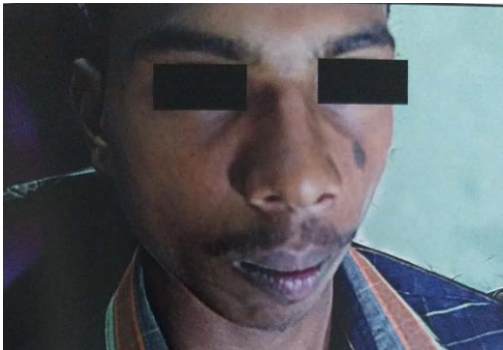### Case Reports

#### Case 1

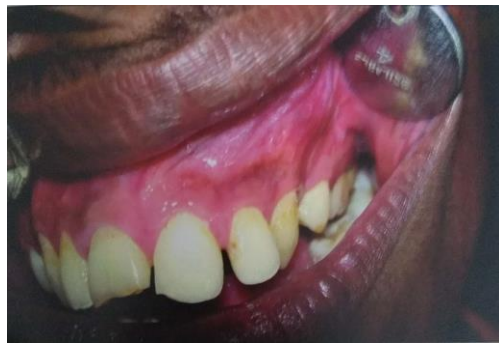A 24 year old male patient reported to the Department of Oral Medicine & Radiology with the chief complaint of swelling on the right side of the upper part of face since 7 months. The swelling was slow growing and was not associated with any paresthesia. The rest of the history was noncontributory. General examination revealed moderately built and nourished male. Extra oral examination revealed painful swelling of size 4x3 cm on the right side of the face extending from ala of nose to 3cm above the lower border of mandible, obliterating nasolabial fold. (Fig. 1) The swelling appeared firm and tender on palpation. The overlying skin appeared normal. Intraoral examination revealed a firm tender swelling of size approximately 3x2.5 cm extending along 11 to 24 region. (Fig. 2) Hard tissue examination revealed full complement of teeth except 38 and 48. No tenderness on percussion and no mobility of teeth were observed. A provisional diagnosis of cysts / tumor of odontogenic origin were considered.

Maxillary occlusal radiograph shows well defined radiolucency of 3x2cm extending from cemento-enamel junction of inverted supernumerary tooth in 11 to 24 regions. Root resorption of 21 is noticed. (Figure 3). This was confirmed with panoramic radiograph. (Fig. 4). Patient was send to the Department of Oral & Maxillofacial Surgery for

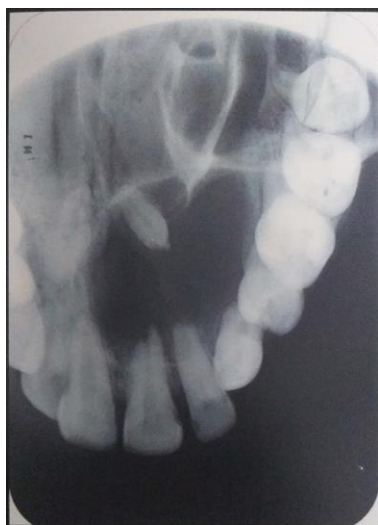biopsy of the above mentioned lesion. Incisional biopsy was performed and send to histopathologic examination. Histopathologic examination revealed (Fig. 5) cyst, with a thin epithelial lining may be present with the fibrous connective tissue wall loosely arranged with inflammatory cells. As the lining is derived from reduced enamel epithelium, cells are cuboidal or low columnar which was (Fig. 6) suggestive of odontogenic cyst -dentigerous cyst. We arrived at final diagnosis of dentigerous cyst in 21 region.



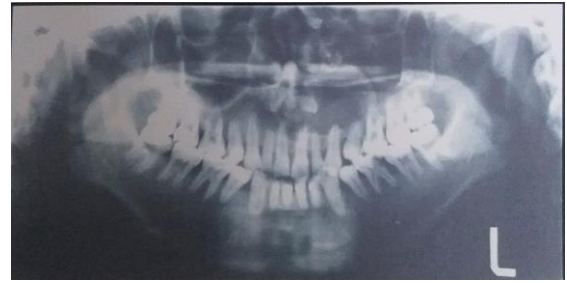**Fig. 1:** Facial photograph showing swelling of face with obliteration left nasolabial folds



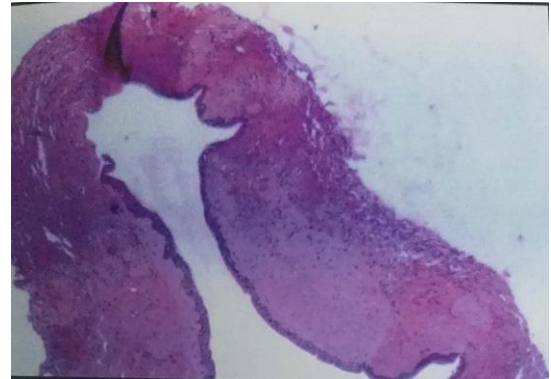
**Fig. 2:** Intraoral photograph showing swelling in 11 to 24 regions



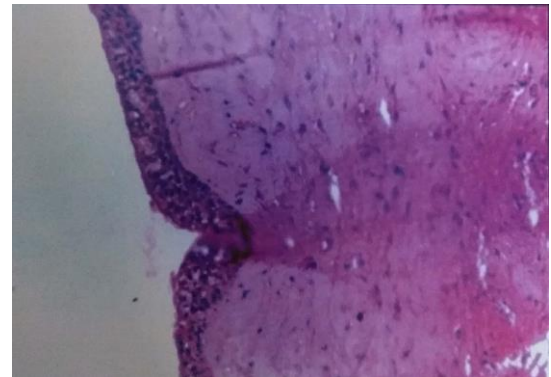
**Fig. 3:** Occlusal radiograph shows pericoronal radiolucency with inverted supernumerary tooth 11 region



**Fig. 4:** Panoramic view



**Fig. 5:** Photomicrograph reveals the cystic lining of cavity with a connective tissue stroma



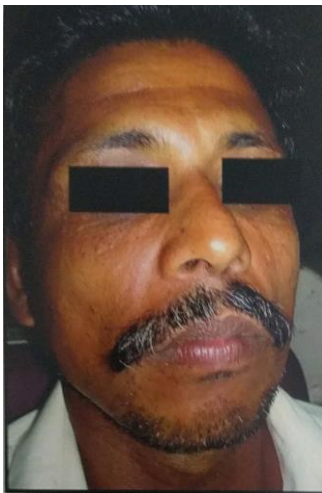**Fig. 6:** Photomicrograph of higher magnification showing the cystic lining of cavity

### Case 2

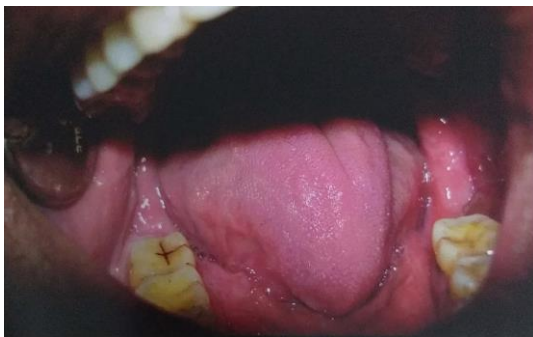A 56 year old male patient reported to the Department of Oral Medicine & Radiology with the chief complaint of swelling on the left side of the jaw since 9 months. The swelling was slow growing and was not associated with any paresthesia. The rest of the history was noncontributory. General examination revealed moderately built and nourished male. Extra oral examination revealed painful swelling of size 2x1.5 cm on the right side of the mandible extending from the body region to the angle. (Fig. 7) The swelling appeared firm and tender on palpation. The overlying skin appeared normal. Intraoral examination revealed a firm tender swelling of size approximately 1.5x1.5 cm extending along 36 to 38 region. (Fig. 8) Hard tissue examination revealed full complement of teeth except 37, 38 and 48. Root remnants of

25 noted. No tenderness on percussion and no mobility of teeth were observed.

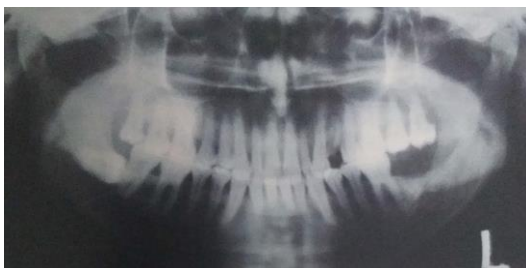Panoramic radiograph was taken and shows well defined radiolucency of 2x1cm extending from pericoronal region of impacted 48. (Fig. 9) Patient was sent to Oral & maxillofacial surgery of biopsy of above described lesion. Incisional biopsy was done and material send for histopathologic examination. Histopathologic examination revealed cyst, with a thin epithelial lining may be present with the fibrous connective tissue wall loosely arranged with inflammatory cells. The epithelial lining is derived from the reduced enamel epithelium. The cyst wall lined by are cuboidal or low columnar cells which was (Fig. 10) suggestive of odontogenic cyst - dentigerous cyst. We arrived at final diagnosis of dentigerous cyst in 48 region.



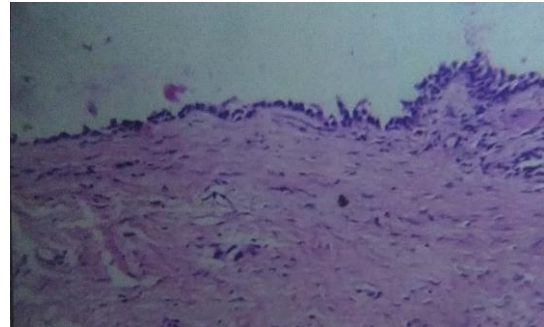
**Fig. 7:** Facial photograph showing swelling of right side of face



**Fig. 8:** Intraoral photograph showing swelling in 48 region



**Fig. 9:** Panoramic view shows pericoronal radiolucency with impacted 48



**Fig. 10:** Photomicrograph showing thin epithelial lining of cystic cavity with connective tissue stroma

### Discussion

Dentigerous cyst is one that surrounds the crown of an unerupted tooth by expansion of the follicle and is attached to its neck of the tooth.<sup>1-5</sup> They may be associated mandibular third molars, maxillary canines, mandibular second premolars and maxillary third molars.<sup>4-8</sup> They may also occur around supernumerary teeth. They are rarely associated with primary teeth.<sup>3-8</sup> In our case reports one case of dentigerous cyst occurred in maxillary anterior region associated with an inverted supernumerary tooth. In the other case the cyst was associated with impacted mandibular third molar. These cysts can grow to very large size and can cause displacement of teeth in few cases. Usually dentigerous cysts are small asymptomatic lesions that are discovered on routine radiographs. Some of these cysts may grow to considerable size causing bony expansion that is usually painless until secondary infection occurs.<sup>4-10</sup>

Radiographically the dentigerous cyst presents as well-defined unilocular pericoronal radiolucency, often with a sclerotic border. This radiolucency typically surrounds the crown of the tooth.<sup>8-13</sup> Both the cases mentioned in our report are unilocular pericoronal radiolucency surrounds crown of impacted tooth. The radiographic differentiation between a dentigerous cyst and a normal dental follicle is based on size. Radiographically, a dentigerous cyst should always be differentiated from a normal dental follicle. Sometimes it may be multilocular in appearance because of the persistence of bone trabeculae within the radiolucency.<sup>11-15</sup>

Infected cysts show ill-defined margins. Follicular space more than 3mm is to be considered a dentigerous cyst. Radiographically there are three types of dentigerous cyst, namely the central type, lateral type and the circumferential type.<sup>12-17</sup> It may also extends down along the root surface as if the entire tooth is located within the cyst.

Dentigerous cyst may resemble odontogenic keratocyst, unicystic ameloblastoma, and ameloblastic fibroma on plain radiography. Computed tomography and Cone beam computed tomography provides important information for the differential diagnosis.<sup>12,17</sup>

In the non-inflamed dentigerous cyst, a thin epithelial lining may be present with the fibrous connective tissue wall loosely arranged with inflammatory cells. As the lining is derived from reduced enamel epithelium, cells are cuboidal or low columnar. In the inflamed dentigerous cyst, the

epithelium usually demonstrates hyperplastic rete ridges and the fibrous cyst wall shows an inflammatory infiltrate.<sup>3-8</sup> As the connective tissue wall is derived from the dental follicle of developing enamel organ, it is a loose connective tissue stroma, which is rich in acid mucopolysaccharides.<sup>3,6-9,13,14</sup> The content of the cystic lumen is usually thin watery yellow fluid and is occasionally blood tinged.

Most dentigerous cysts are treated with nucleation of the cyst and removal of the associated tooth.<sup>16-18</sup> Large dentigerous cysts may be treated with marsupialization.<sup>16-18</sup> The enucleation and curettage might result in neuro sensory dysfunction or pre-dispose to an increased risk of pathological fracture. Occasionally dentigerous cyst may transform to ameloblastoma, mucoepidermoid carcinoma or squamous cell carcinoma from<sup>8,9,10-12,17</sup> The prognosis for most dentigerous cysts is usually good.

### Conclusion

Dentigerous cyst is an odontogenic cyst of developmental origin. It is usually associated with the crown of an impacted, unerupted or partially erupted tooth. Usually managed by various surgical approaches and has got good prognosis.

### Source of funding

None.

### Conflict of interest

None.

### References

- Browne RM. The pathogenesis of odontogenic cysts: A review. *J Oral Pathol* 1975;4:31-46.
- Browne RM, Smith AJ. Investigative Pathology of the Odontogenic Cyst. New Jersey: CRC Press Boca Raton; 1991. Pathogenesis of odontogenic cysts; pp. 88-109.
- Shear M, Speight P. 4th ed. Blackwell Publishing Ltd; Cysts of the oral and maxillofacial regions; 2007.
- Jones AV, Craig GT, Franklin CD. Range and demographics of odontogenic cysts diagnosed in a UK population over a 30-year period. *J Oral Pathol Med* 2006;35:500-75.
- Kusukawa J, Irie K, Morimatsu M, Koyanagi S, Kameyama T. Dentigerous cyst associated with a deciduous tooth. A case report. *Oral Surg Oral Med Oral Pathol* 1992;73:415-8.
- Main DM. The enlargement of epithelial jaw cysts. *Odontol Revy* 1970;21:29-4.
- Edamatsu M, Kumamoto H, Ooya K, Echigo S. Apoptosis-related factors in the epithelial components of dental follicles and dentigerous cysts associated with impacted third molars of the mandible. *Oral Surg Oral Med Oral Pathol Oral Radiol Endod* 2005;99:17-23.
- Eversole LR, Sabes WR, Rovin S. Aggressive growth and neoplastic potential of odontogenic cysts: With special reference to central epidermoid and mucoepidermoid carcinomas. *Cancer* 1975;35:270-82.
- Johnson LM, Sapp JP, McIntire DN. Squamous cell carcinoma arising in a dentigerous cyst. *J Oral Maxillofac Surg* 1994;52:987-90.
- Scholl RJ, Kellett HM, Neumann DP, Lurie AG. Cysts and cystic lesions of the mandible: Clinical and radiologic-histopathologic review. *Radiographics* 1999;19:1107-24.
- Leider AS, Eversole LR, Barkin ME. Cystic ameloblastoma. A clinicopathologic analysis. *Oral Surg Oral Med Oral Pathol* 1985;60:624-30.
- Langlais RP, Langland OE, Nortje CJ. Diagnostic imaging of the jaws. Malvern (PA): Williams & Wilkins; 1995;286-93:327-35.
- Avelar RL, Antunes AA, Carvalho RW, Bezerra PG, Oliveira Neto PJ, Andrade ES. Odontogenic cysts: A clinicopathological study of 507 cases. *J Oral Sci* 2009;51:581-6.
- Zhang LL, Yang R, Zhang L, Li W, MacDonald-Jankowski D, Poh CF. Dentigerous cyst: A retrospective clinicopathological analysis of 2082 dentigerous cysts in British Columbia, Canada. *Int J Oral Maxillofac Surg* 2010;39:878-82.
- Sanatkhani M, Zarch HH, Pakfetrat A, Falaki F. Odontogenic cysts: A clinical and radiographic study of 58 cases. *Aust J Basic Appl Sci* 2011;5:329-33.
- Main DM. Follicular cysts of mandibular third molar teeth: Radiological evaluation of enlargement. *Dentomaxillofac Radiol* 1989;18:156-9.
- Stuart C. White and Michael J. Pharoah, Oral Radiology: Principles and Interpretation: Second South Asian edition 2019;165-80.
- Motamedi MH, Talesh KT. Management of extensive dentigerous cysts. *Br Dent J* 2005;198:203-6.

**How to cite this article:** Rajasekharan A, Thomas SA Prasad TS, Balan A, Sreedevi PU. Dentigerous cyst of Jaws: Clinico-pathological-imaging correlations of two cases. *J Oral Med, Oral Surg, Oral Pathol, Oral Radiol* 2019;5(4):132-5.