

# Evaluation of Open Reduction and Internal Fixation of Mandibular Subcondylar Fractures through Transmasseteric-anteloparotid approach- an Original Study

Yuvraj Isser<sup>1</sup>, NK Sahoo<sup>2</sup>, Manish Mittal<sup>3</sup>, Ashish Kalra<sup>4\*</sup>

<sup>1</sup>Graded Specialist, Bhutan, <sup>2</sup>Commandant, CMDC, Chandigarh, <sup>3</sup>Graded Specialist, Jalandhar, <sup>4</sup>Graded Specialist, Bhopal

\*Corresponding Author:

Email: doc\_ashish47@rediffmail.com

## ABSTRACT

**Background:** Management of mandibular subcondylar fractures has always been a matter of debate and controversy in spite of being 1/3rd of all mandibular fractures. Literature increasingly suggests that surgical management of these fractures is superior to conservative management. Undiagnosed or indirectly treated condylar fractures can lead to severe functional impairment including poor occlusion, reduced opening associated deviation and limited mandibular lateral movements. However it is of outmost importance that the surgical procedure must guarantee maximum safety for the facial nerve and must provide a good cosmetic outcome.

**Objective:** In this paper we advocate a rapid and comfortable technique which fulfils these conditions and is unlikely to damage the facial nerve.

**Methodology:** A series of 30 patients with mandibular subcondylar fractures who were treated by ORIF via the retro mandibular transmasseteric-anteloparotid approach over a period of 4 years from 2011 through 2015. These patients were evaluated on various parameters such as

1. Postoperative occlusal stability
2. facial nerve integrity on the House Brackmann Facial Nerve Grading System
3. Range of mandibular movements and
4. Scar visibility on the visual analogue scale

The patients were divided into groups A (those with isolated subcondylar fractures) and B with concomitant facial fractures.

**Results:** In all cases good anatomical reduction and stable post-operative fixation was achieved with mandibular movements within normal range. **Conclusion:** In our opinion the anteloparotidtransmassetric approach is appropriate for surgical management of mandibularsubcondylar fractures as it provides adequate access, ensures safety of the facial nerve and is relatively easy to master.

**Keywords:** Subcondylar, Anteloparotid, Access

Access this article online	
Quick Response Code:	Website: www.innovativepublication.com
	DOI: 10.5958/2395-6194.2015.00002.8

## INTRODUCTION

Management of mandibular subcondylar fractures has always been a matter of debate and controversy inspite of being 1/3<sup>rd</sup> of all mandibular fractures(1-3). Literature increasingly suggests that surgical management of these fractures is superior to conservative management. Never the less indications for surgically treating condylar fractures are limited by the pitfalls related to access(4). Many techniques have been described which generally provide a reasonable access to the condylar process. However it is of outmost importance that the surgical procedure must guarantee maximum safety for the facial nerve and must provide a good cosmetic outcome. In this paper we present a rapid and comfortable technique which fulfils the

conditions and is unlikely to damage the facial nerve. A series of 30 patients were treated via ORIF for subcondylar fractures using this technique and evaluated on various parameters determining the success of the procedure.

## MATERIAL AND METHODS

A series of 30 patients (27 males) and (03 females)with mandibular subcondylar fractures who were treated by ORIF via the retromandibular transmasseteric-anteloparotid approach over a period of 4 years from June 2011 through May 2015. Their ages ranged from 06 to 52 yrs.The patients were divided into groups A (those with isolated subcondylar fractures) and B (with concomitant facial fractures). Group A comprised of 17 patients and group B of 13 patients [Table 1]. These patients were evaluated on various parameters such as

1. Postoperative occlusal stability
2. facial nerve integrity on the House Brackmann Facial Nerve Grading System (HBFNGS)
3. Range of mandibular movements and
4. Scar visibility on the visual analogue scale

Facial nerve function of all patients was evaluated by the same surgeon preoperatively, in the immediate post op period and 24 hours after surgery. Facial nerve injury was deemed to have occurred if the patient was unable to raise the eyebrows, wrinkle the forehead, completely close the eyelids or smile symmetrically. Patients who presented postoperative facial nerve injury

were similarly examined using the HBFNGS at 24 hours, 1 week, 1 month. Nosurgical or drug therapy was adopted to treat the facial nerve injury.

Patients who suffered facial nerve injury concomitant to trauma, immunocompromised and those with debilitating diseases and edentulous cases were excluded from the study.

**Table 1: Distribution of cases in relation Sex as well as presence or absence of concomitant facial fractures**

Distribution	Number of Patients	Percentage of Patients
Males	27	88.99
Females	3	11.11
Group A	17	56.66
Group B	13	43.44

### SURGICAL TECHNIQUE

The described technique is appropriate for the treatment of patients with displaced or undisplaced fractures of the condyle. A 4 to 5 cm skin incision is made 0.5 cm below the ear lobule approximately 0.5 cm behind the posterior border of ramus of the mandible. The incision is marked before infiltration with a solution of lignocaine with epinephrine [Fig. 1]. The skin and subcutaneous tissue is cut in the initial incision followed by incision of the platysma muscle which retracts spontaneously to reveal the parotidomassetric fascia. Dissection is carried over the fascia upto the fractured site [Fig. 2]. The parotid gland is then retracted posteriorly and the massetric tendon is incised approximately 1 cm above the angle of mandible at its posterior border. Dissection is then carried in the subperiosteal plane to expose the fractured segments. Titanium miniplates using Meyers osteosyn thesis principles(5) were primarily utilized however modified as per merit of cases. The temporary maxillomandibular fixation was removed at the end of the procedure. All patients were reviewed for reorientation of condylar function and physiotherapy.

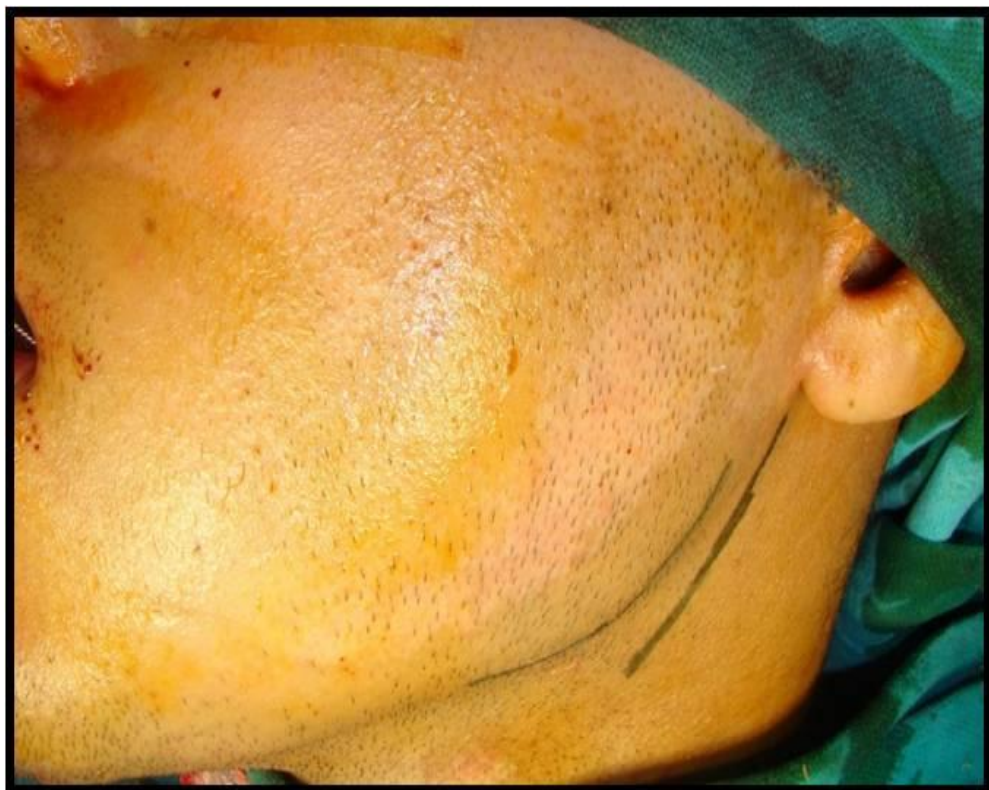

Fig. 1

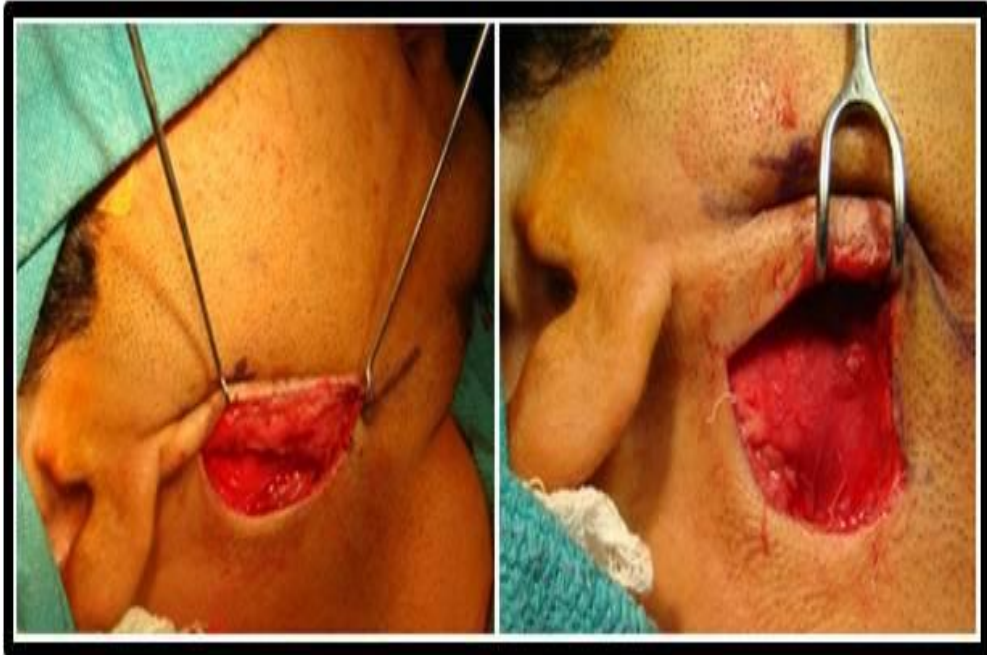

Fig. 2

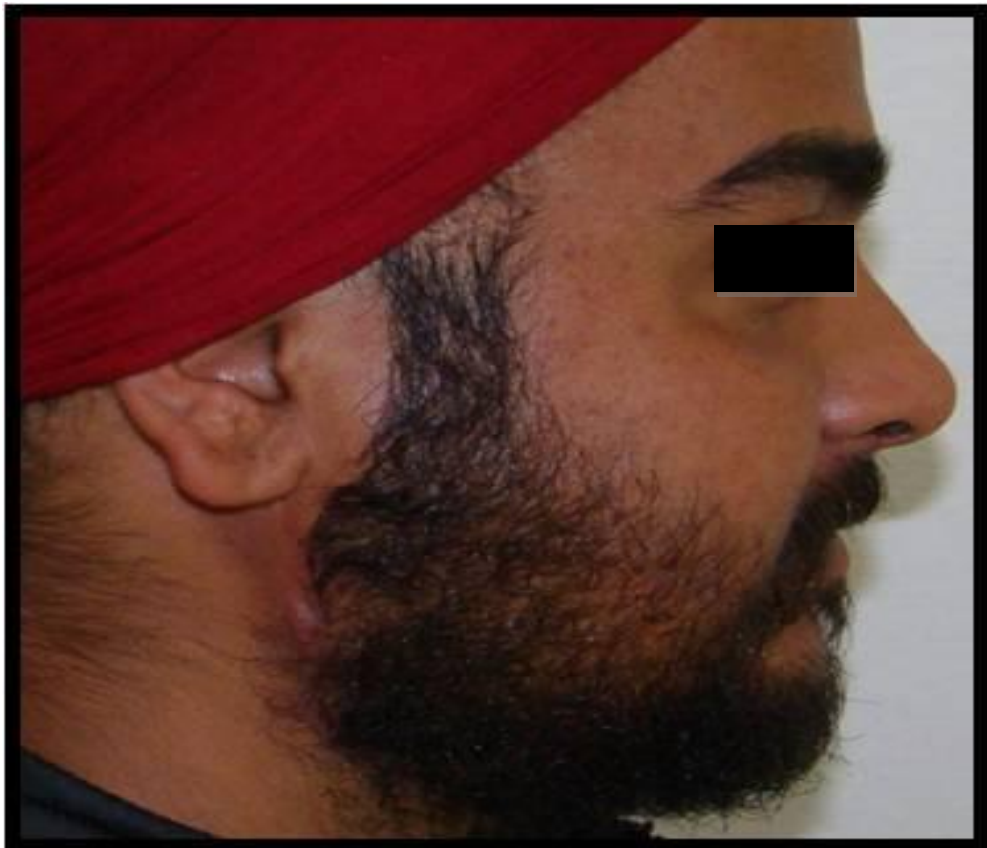

Fig. 3



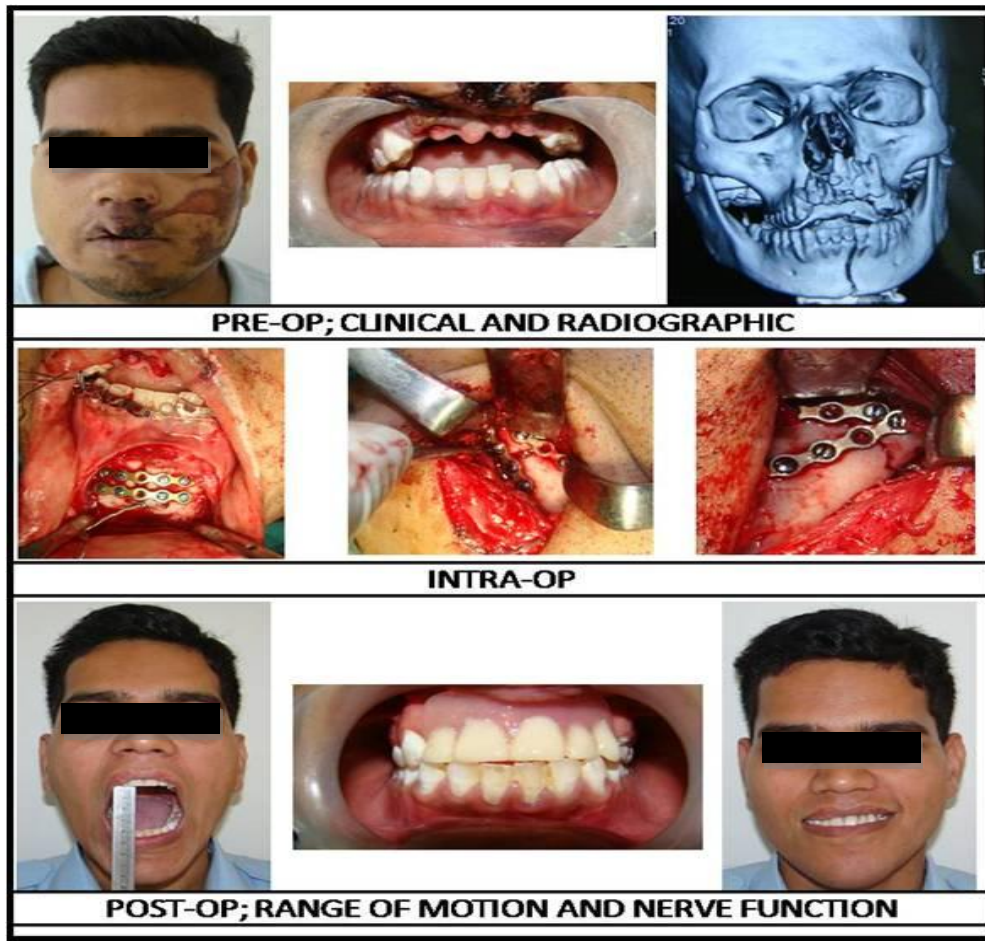


Fig. 4

**RESULT**

In all cases the dental occlusion was restored and good anatomical reduction was achieved. Articular function was preserved in all patients since all accesses were extra-articular. No permanent facial nerve injury was observed, a House Brackmann grade of I was obtained for 28 patients and that of III for 2 patients, one month postoperatively Table 2. However transient marginal mandibular nerve weakness was observed in 02 patients which resolved over a period of six months postoperatively. One postoperative infection occurred in a patient with an isolated right subcondylar fracture with resultant purulent discharge from the surgical scar. However, infection was resolved with wound irrigation and systemic antimicrobial therapy[Fig. 3]. All the skin scars were barely visible, except in the patient who suffered from postoperative infection. In this patient, a revision improved the final result. Postoperatively the range of mandibular movements was within normal limits for all the patients with a mean maximum interincisal opening of 36.83 mm[Table 2, Fig. 4].

**Table 2: Master Chart: Patients submitted to surgical procedures for the treatment of mandibular subcondylar fractures from 2011 to 2015**

			HBFNCS 1 month post op			
SubcondylarRt	A	Stable	I	No	40	Nil
SubcondylarRt	A	Stable	I	No	38	Nil
SubcondylarRt	A	Stable	I	No	28	post op infection
Subcondylar Lt	A	Stable	I	No	35	Nil
Subcondylar Lt	A	Stable	I	No	42	Nil
SubcondylarRt	A	Stable	I	No	37	Nil
SubcondylarRt	A	Stable	I	No	36	Nil
SubcondylarRt	A	Stable	I	No	38	Nil
Subcondylar Lt	A	Stable	I	No	41	Nil
SubcondylarRt	A	Stable	I	No	38	Nil
SubcondylarRt	A	Stable	I	No	39	Nil
SubcondylarRt	A	Stable	I	No	43	Nil

SubcondylarRt	A	Stable	I	No	36	Nil
SubcondylarRt	A	Stable	I	No	37	Nil
Subcondylar Lt	A	Stable	I	No	42	Nil
SubcondylarRt	A	Stable	I	No	33	Nil
SubcondylarRt	A	Stable	I	No	40	Nil
SubcondylarRtparasymphysis Lt	B	Stable	I	No	36	Nil
Subcondylar Lt parasymphysisRt	B	Stable	III	Yes	35	Facial nerve injury
Bilateral Subcondylar	B	Stable	I	No	39	Nil
Bilateral Subcondylar, parasymphysisRt	B	Stable	I	No	38	Nil
Subcondylar Lt, Mand body Lt, ZMC Lt	B	Stable	I	No	33	Nil
Bilateral Subcondylar	B	Stable	I	No	34	Nil
Bilateral Subcondylar	B	Stable	I	No	36	Nil
SubcondylarRt, ramus Rt, Coronoid Rt	B	Stable	I	No	29	Nil
Bilateral Subcondylar	B	Stable	I	No	34	Nil
SubcondylarRtparasymphysis Lt	B	Stable	I	No	35	Facial nerve injury
Bilateral Subcondylar	B	Stable	III	Yes	39	Nil
SubcondylarRtparasymphysis Lt	B	Stable	I	No	34	Nil
Subcondylar Lt parasymphysis Lt	B	Stable	I	No	40	Nil

## DISCUSSION

The standard Risdon or retromandibular approach may not provide satisfactory and adequate access to the fractured site(6), especially in high subcondylar fractures as the incision site is relatively further away as well as the resultant bulky soft tissue flap for retraction. Fixation performed using the above mentioned approaches may not be very stable due to the excessive angulation of screws. In the approach used by us the relative proximity as well as more direct access to the fractured site provides room for a more stable fixation, hence more favourable post op results.

The most frequent complication of this surgery is facial paralysis ref(7) Impairment of facial nerve function interferes with emotional expression, causes functional deficits, and can create a grotesque cosmetic deformity. The Marginal mandibular branch has greater vulnerability to damage than Buccal and Zygomatic branches due to interconnections ref(8) hence the dissection at a higher level, approximately 1 cm above the angle of mandible in the approach used by us reduces the incidence of facial nerve injury. The technique used by us has been inspired by Wilk(9) which advocates subcutaneous dissection which decreases nerve injury.

Two plate fixation as per Meyers(5) was done in the majority of cases, using 04 hole and 03 hole Titanium miniplates. Single or L plate fixation was done only for those patients where two plate fixation could technically not be possible. However all cases irrespective of the method of fixation were included in the study. The mean duration of the procedure utilizing the High cervical transmasseteric-anteparotid approach by Tros O et al(10) was 40 minutes. In the approach used by us the mean duration of operating

time was 52 minutes however it was greater in case operated initially and steadily decreased in the cases operated in the latter part of the study. The House facial paralysis grading system(11) was introduced in 1983 for clinical use and was modified by Brackmann(12) in 1985. In our study the cases were evaluated on this scale in the immediate post op period 24 hours postoperatively, 1 week and 1 month postoperatively. We observed that the duration of operation had no bearing to the incidence of facial nerve injury or success of the procedure.

## CONCLUSION

According to recent publications, open reduction and internal fixation of condylar fractures provide better results. The preferred surgical approach should be one that allows straightforward fracture management whilst minimizing the risk of potential pitfalls, such as facial nerve lesions or unsightly scars. In our opinion the anteparotidtransmasseteric approach is appropriate for surgical management of mandibular subcondylar fractures as it provides adequate access, ensures safety of the facial nerve with a minimal scar which is well hidden behind the posterior border of the mandible and is relatively easy to master.

## REFERENCES

1. Ellis III E, Throckmorton GS. Facial symmetry after closed and open treatment of fractures of the mandibular condylar process. *J Oral Maxillofac Surg*2000; 58: 719.
2. Haug R, Prather J, Indresano A. An epidemiologic survey of facial fractures and concomitant injuries. *J Oral Maxillofac Surg*1990; 48: 926.
3. Schneider M, Lauer G, Eckelt U. Surgical treatment of the mandibular condyle: a comparison of long-term results following different approaches e functional, axiographical,

- and radiological findings. *J Craniomaxillofac Surg* 2007; 35: 151.
4. Biglioli F and Colletti G. Mini-retromandibular approach to condylar fractures. *Journal of Cranio-Maxillofacial Surgery* 2008; 36: 378-383.
  5. Meyer C, Kahn JL, Boutemi P, Wilk A. Photoelastic analysis of bone deformation in the region of the mandibular condyle during mastication. *J Craniomaxillofac Surg* 2002; 30:160.
  6. Kempers KG, Quinn PD, Silverstein K. Surgical approaches to mandibular condylar fractures: A review. *J Craniomaxillofac Trauma* 1999; 5:25.
  7. Ellis E, Mc Fadden D, Simon P, et al. Surgical complications with open treatment of mandibular condylar process fractures. *J Oral Maxillofac Surg* 2000; 58: 950.
  8. Gosain AK. Surgical anatomy of the facial nerve. *Clin Plast Surg* 1995; 22: 241.
  9. Wilk A. L'ostéosynthèse des fractures du condyle. Vers une rationalisation? in *Rapport du Theme Principal La Chirurgie du Condyle Mandibulaire*. Strasbourg, French Society of Maxillofacial Surgery 2002.
  10. Trost O, El-Naaj IA, Trouilloud P, Danino A and Malka G. High Cervical Transmasseteric Anteroparotid Approach for Open Reduction and Internal Fixation of Condylar Fracture. *J Oral Maxillofac Surg* 2008; 66: 201-204.
  11. House JW: Facial nerve grading systems. *Laryngoscope* 1983; 93:1056.
  12. House JW, Brackmann DE: Facial nerve grading system. *Oto-laryngol Head Neck Surg* 1985; 93:146.