



Review Article

Utilising CBCT in oral surgery

Aveek Mukherji^{1,*}, Mohit Pal Singh¹, Prashant Nahar¹, S Bhuvaneshwari²,
Deeptanshu Daga¹

¹Dept. of Oral Medicine, Diagnosis & Radiology, Pacific Dental College and Hospital, Debari, Rajasthan, India

²Dept. of Oral Medicine, Diagnosis & Radiology, Kalinga Institute of Dental Sciences, Bhubaneswar, Odisha, India



ARTICLE INFO

Article history:

Received 14-03-2021

Accepted 09-04-2021

Available online 08-06-2021

Keywords:

CBCT

Oral surgery

ABSTRACT

CBCT's popularity amongst the dentists was earned by its ability to provide comprehensive radiographic evaluation. It discloses veracious anatomic structures without any superimpositions or distortions and gives unmatched accuracy in measurement. Presently, CBCT renders profound benefits in different aspects of dentistry and is evolving further to expand its usefulness. In this article, the utility and advantages of CBCT are briefly highlighted with pictorial demonstrations.

© This is an open access article distributed under the terms of the Creative Commons Attribution License (<https://creativecommons.org/licenses/by/4.0/>) which permits unrestricted use, distribution, and reproduction in any medium, provided the original author and source are credited.

1. Introduction

Cone beam computed tomography (CBCT), introduced to dentistry in 1997,¹ employs a single 360° rotation of a conical beam of radiation to generate a three dimensional (3-D) image.² As per requirement, either a large area of the facial skeleton or a small area of focused clinical interest is captured by altering the field of view. This primarily acquired image is then reformatted to display radiographic images in multiple possible orientations.³ Thus, periapical, panoramic, occlusal, as well as cephalogram radiographic views can be obtained from a single exposure.² Moreover, ease in exporting and importing data and intraoperative handling allows a more meticulous assessment of surgical risk.⁴ Though the image quality is influenced by the scanning unit and different acquisition parameters,⁵ CBCT provides high spatial resolution and is lower in cost and radiation when compared with medical computed tomography scans.⁴ Unlike plain film radiography, CBCT images are free from geometric distortion and superimposition of surrounding anatomical structures.⁶ The measurements are acceptably accurate

with less than 1% error,³ making it an unambiguous method to evaluate bone architecture.⁷ Major uses of CBCT examination in oral surgery include pre-surgical evaluation of impacted teeth, detection of inflammatory conditions of the jaws and the sinuses, evaluation of cysts and tumours, assessment of the temporomandibular joints, dentofacial fracture detection, implant planning and as an aid in diagnosing unexplained symptoms of pain.³

For this article, CBCT's usefulness in oral surgery was searched in the EbscoHost databases from 1997 to 2019. "CBCT" (keyword) was searched and about 200 peer-reviewed articles were found in the first search. Title and abstract of the articles were thoroughly reviewed. Considering the objective of our study the irrelevant articles were excluded and about 100 articles were selected by two reviewers independently. Diagnostic, comparative studies and reviews on the application of CBCT, its safety, accuracy and predictive capability were included. The articles were assessed by one researcher in terms of adherence to the above criteria and reviewed by another researcher. In case of disagreement, a third person's opinion was taken. All of them were Oral and Maxillofacial Radiologists.

The information from the selected articles were grouped under the following headings for the ease in understanding.

* Corresponding author.

E-mail address: dentist_aveek@rediffmail.com (A. Mukherji).

2. Impacted Teeth

About 25–50% of the population bears impacted teeth; the most common one being the third molar, followed by canine.⁸

Though the prevalence of third molar impactions is variable in different populations, the incidence appears to be increasing.⁹ Their extraction is recommended in conditions like pericoronitis, caries on the distal surface of the adjacent second molar, pain, external root resorption and associated odontogenic cysts or tumours.¹⁰ The most noteworthy complication after such procedures is neural damage (0.4–13.4% cases).¹¹ Radiography aims to reduce these post-operative complications by assessing the state of impaction, root development, angulations of the tooth, number of roots and their morphology, related pathology and most importantly, the relation between the tooth and the nerve.¹² The buccolingual position, tortuosity and presence of bifurcation or trifurcation of canals, which cannot be reliably interpreted by conventional radiographic images, can be accurately traced with CBCT. It also rules out ankylosis and guides the surgeon in developing the safest surgical plan.³

Figure 1 displays an impacted left mandibular third molar (38), touching the distal surface of the adjacent second molar (37), inferior to its cemento-enamel junction, causing a pressure caries (encircled in blue) at that point. CBCT software allowed the tracing of mandibular canal (in orange) to exhibit its relative position with the teeth. A three-dimensional reconstructed image (encircled in red) shown in the right lower corner of Figure 1 B, further elucidates the interrelationship between the two molars. CBCT allows thinner sectioning of images, as demonstrated in Figure 1 B to enhance the visibility of the lesion. The incompletely formed mesial root of 38 is touching the mandibular canal. Such detailed awareness of the anatomical structures facilitate the formation of the most favourable treatment plan.

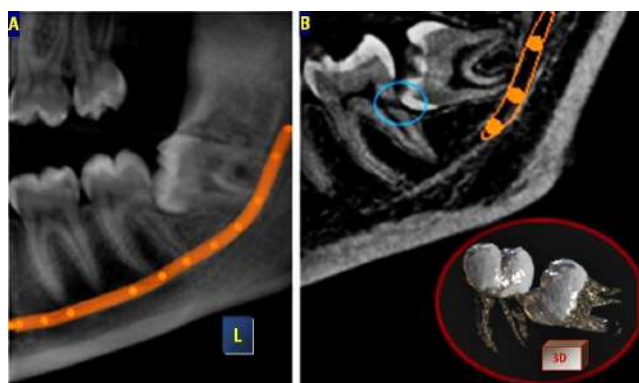


Fig. 1:

Vertically impacted 38, with its occlusal surface at the level of the apex of 37 is displayed in Figure 2. The

apical region of 38 almost penetrates the lower border of the mandible. There is pericoronal radiolucency with well demarcated border, suggestive of pathology. The mandibular canal (traced in yellow) almost touches the buccal surface of 38, just below its cemento-enamel junction, as pointed out by the blue arrow in the cross-sectional image at the lower left corner of Figure 2 B. CBCT software allowed the highlighting of 38 in pink, to distinguish it from the surrounding structures. The panoramic image in Figure 2A displays the mesio-distal orientation of the pericoronal pathology associated with 38, while the axial and cross-sectional images in Figure 2B reveals the bucco-medial dimension, giving an unambiguous perception of its magnitude. There is breach in continuity of the crestal and lingual alveolar bone due to the lesion. Such detailed inspection enables identification of probable post surgical complications, allowing the dentist to take proper precautions and appropriate consent from the patient.

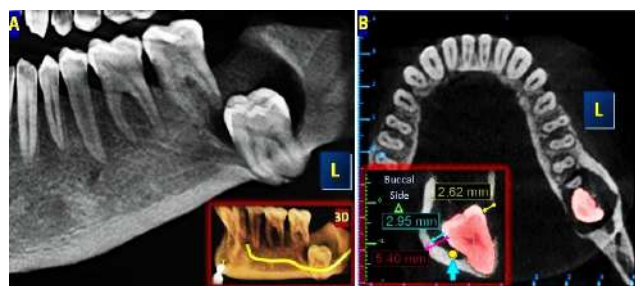


Fig. 2:

Probably the longest period of development as well as the longest path of eruption, catalyzes the high incidence (1–3%⁸) of impaction in maxillary canines.¹³ CBCT improves the perceptibility of their location and helps with the identification of associated pathologies (ankylosis, cystic lesions and resorption of adjacent tooth.^{13,14}) Ectopic eruption of the canines cause resorption of the adjacent incisors in up to 50% cases,¹⁵ which is underestimated by the two-dimensional (2D) images.¹³ CBCT has a high ability and reliability in detecting such root resorption.¹⁴

Bilaterally impacted maxillary canines are revealed in the panoramic image (with red border) present in the middle of Figure 3. Axial sections reveal the relationship between impacted teeth and its surrounding structures. The impacted teeth have been highlighted with pink for ease of recognition. The incisal tips of both the canines point anteriorly, while the apex is directed posteriorly. No relevant pathology is detected in association with these canines.

An impacted right maxillary canine with curved shape is displayed in Figure 4. The 3D reformatted image (encircled in red), in the left upper corner of Figure 4A shows its 'C' shaped anatomy. Such an image can be rotated in all directions for better apprehension of the morphology. Oblique cross-sectional image in Figure 4B reveals the

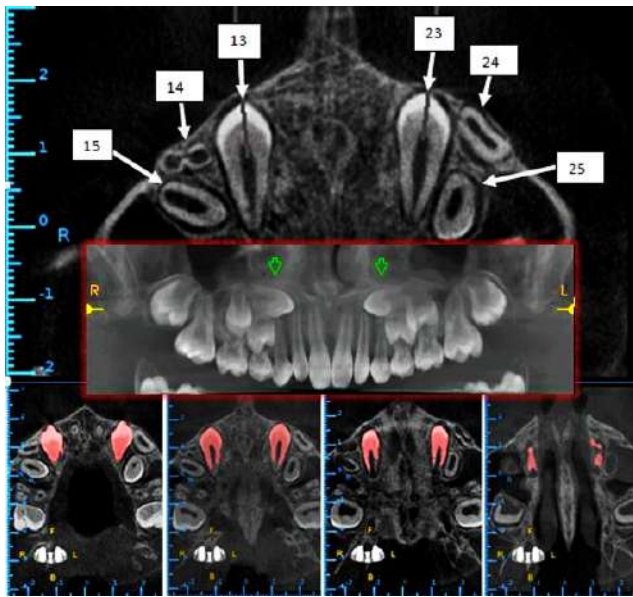


Fig. 3:

associated radiolucency, suggestive of pathology. The apical third of the root is in contact with the floor of the maxillary sinus, which shows breach in its continuity. The apex of the mesiobuccal root of 16, lying in close proximity with the impacted tooth displays external resorption, as revealed in Figure 4B. Any surgical approach without such anatomisation may lead to grave consequences.

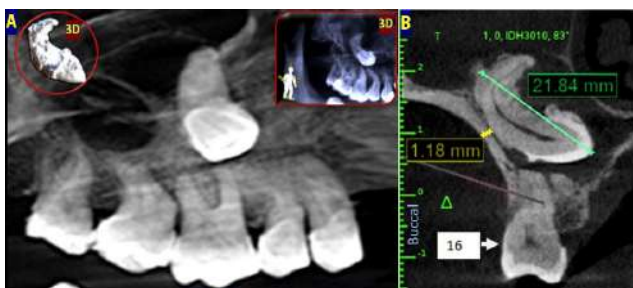

Fig. 4:

Depending upon the studied population, the prevalence of supernumerary teeth can be as high as 3-6% in the permanent dentition.⁸ About 42-51% of them remain unerupted by adolescence.¹⁶ CBCT can precisely identify and detect the location of such supernumerary teeth for impeccable treatment planning.¹⁷

A unique case is presented in Figure 5, where an impacted permanent tooth, an impacted supernumerary tooth, an odontome and a retained deciduous tooth lie in the same region. As revealed in the Figure 5A, right maxillary central incisor (11) is vertically impacted. A horizontally impacted supernumerary tooth lies buccal to it, with the incisal edge lying at the middle of the crown of

11, and the apex positioned distally. A retained deciduous incisor (61) is in the occlusal position. In between these two incisors, lie an irregularly shaped heterogeneously radiopaque odontome (suspected) with well demarcated border. No associated pathology or resorption is disclosed in this region. Figure 5B shows the relative positions of the two incisors and the odontome in a cross-sectional image. Conventional radiographs fail to disclose such intricate interrelationship effectively.

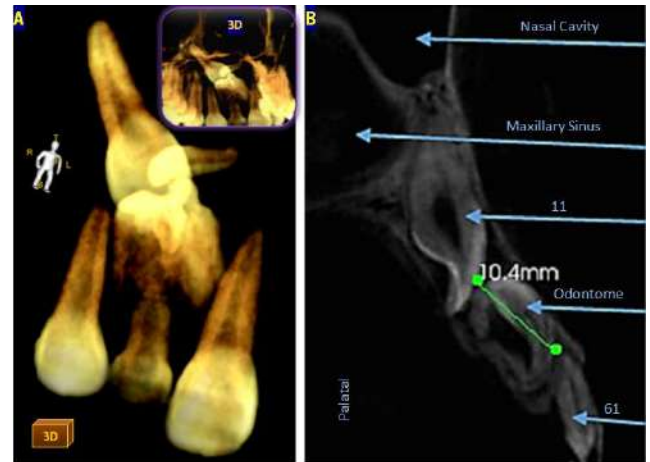


Fig. 5:

3. Dento-Maxillofacial Pathologies

Proficiency of CBCT to reveal periapical pathologies is superior to periapical radiographs.¹⁸ It enables precise analysis of the pathology's dimensions and involvement of neighbouring anatomical structures (Figure 2).¹⁹ Moreover, accurate post-surgical follow-up of the margins of lesions with high recurrence rate is also possible.³

Periapical pathology associated with the mesiobuccal root of right upper maxillary first molar (16) is revealed in Figure 6. The lesion had a well defined radiopaque border and intruded the right maxillary sinus (highlighted in blue). Figure 6 A shows a coronal section, displaying the measurement of the periapical lesion, from the apex of the root to the palatal cortex of the alveolar bone. Similar measurement is attainable in every direction and in any desired radiographic plane. Figure 6B exhibits an oblique image, disclosing the lack of lateral condensation of the obturating material in the root canal. Figure 6 C shows an oblique axial image, unveiling the extent of involvement of the left maxillary sinus.

CBCT also exhibits ease in the early detection of the irregular margins of malignant tumours. Osteomyelitis and bisphosphonate related osteonecrosis of the jaws, which show similar margins, can be better distinguished with this modality by identifying their differentiating features (development of new layers of periosteal bone and presence

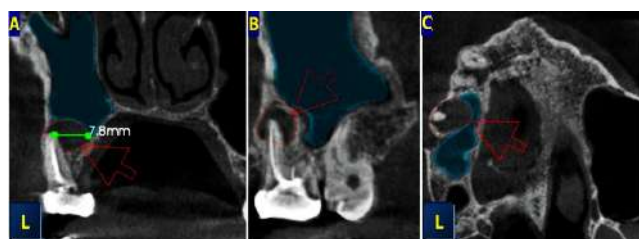


Fig. 6:

of bony sequestra).³

Sinus pathologies (prevalence 24.6-56.3%), commonly detected on CBCT scans of asymptomatic patients consists of mucositis, sinus polyps, antro-oral communication and cysts. Location, and orientation of sinus septa, exostoses, tumors (eg, osteomas), antroliths, and foreign bodies can also be accurately evaluated.²⁰

4. Orofacial Osseous Defects

CBCT images are invaluable for patient education and treatment planning in craniofacial disorders.³ In orofacial clefts (incidence 1 in 600 live births⁵), apart from assessing its dimension in different planes, CBCT also discloses the location of adjacent teeth, deviation of the nasal septum along with its degree of fusion to the palate.³

Radiographic evaluation of complete cleft palate is shown in Figure 7, where the measurement of the bony defects is displayed in axial views. Freedom to obtain such measurements in any desired plane enables quintessential assessment of bony defects. Follow up of each such region is also possible with an adjacent reference point to detect the growth pattern or to evaluate the prognosis of treatment. CBCT allows accurate analysis of the volume of the bone defect, so that the requirement of bone grafts can be predetermined.

Dehiscence and fenestration, which are not perceived in the conventional radiographs, can also be assessed.²¹ Harmless bone defects like Stafne's cyst (Incidence-0.10% to 0.48%), that can mimic a pathology, is easily verified with CBCT, avoiding needless procedures like exploratory surgery or endodontic treatment of vital, asymptomatic teeth.²²

The oblique sagittal view of left side of mandible in Figure 10 A discloses a round radiolucency near the periapical region of 37 that might have been misinterpreted as a periapical pathology in a conventional radiograph. However, cross-sectional (Figure 8 B) and axial (Figure 8 C) views reveal that the defect is limited within the lingual cortical plate, with a well demarcated border and away from the tooth, suggestive of Stafne's cyst.

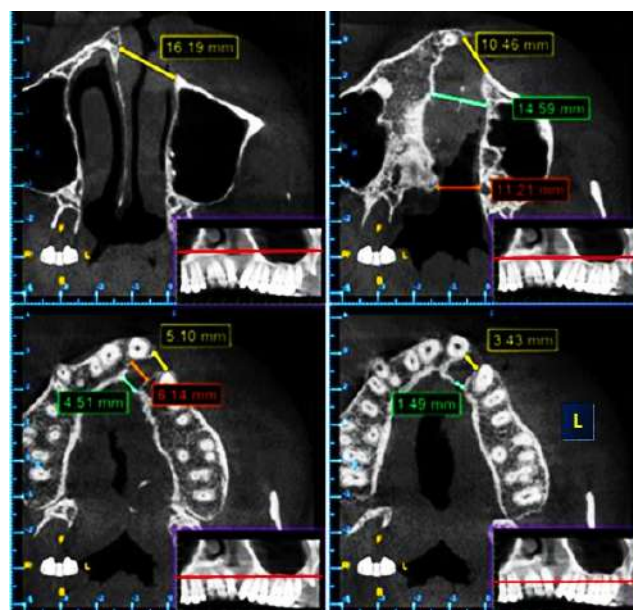


Fig. 7:

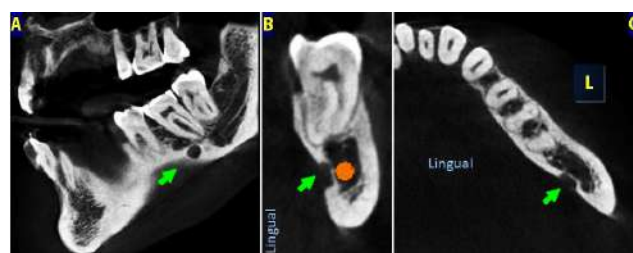


Fig. 8:

5. Temporomandibular Joint

Overlapping of adjacent structures and complex anatomy causes difficulty in assessing TMJ by conventional imaging.²³ CBCT allows reconstruction of images in planes parallel and perpendicular to the long axis of the condyle, enabling thorough assessment of its position within the glenoid fossa. This also allows effective evaluation of the integrity of the bony structures.²⁴

Figure 9 exhibits a fractured condyle with displacement of the broken segment medially and inferiorly (red arrow). The oblique coronal view in the upper left corner of Figure 9 is oriented along the long axis of the condyle, lying within the glenoid fossa. On the upper right side, a similar view is oriented along the long axis of the displaced condylar fragment. The upper middle image attempts to demonstrate the relative position of the two parts of the condyle. Such flexibility to select the plane of view allows meticulous assessment of the integrity and surface of the TMJ. In between the three above mentioned views, lie two reconstructed 3D images. The right one is viewed from the buccal side, while the left one is viewed from the lingual

side. The lower 3 images of Figure 9 displays the relative positions of the condylar fragments in axial views with their corresponding positions marked by a blue line in the associated sagittal views.

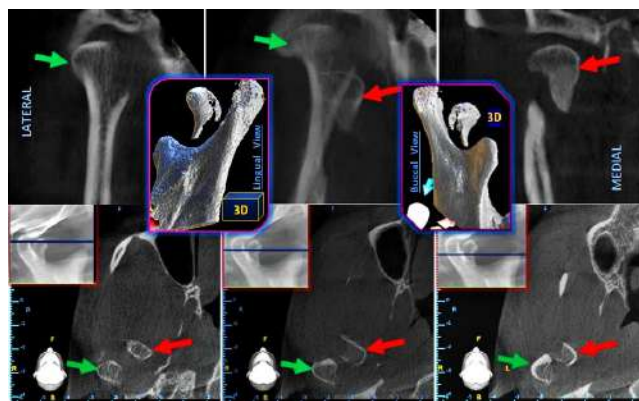


Fig. 9:

6. Fracture of Dentomaxillofacial Structures

Vertical root fracture or multiple jaw fractures (with or without displacement) is better evaluated by CBCT images.³

A fracture in the mesial root of left mandibular second molar (37) is revealed with a thin panoramic view in Figure 10A, with displacement of the fractured segment. The periradicular radiolucency is suggestive of pathology.

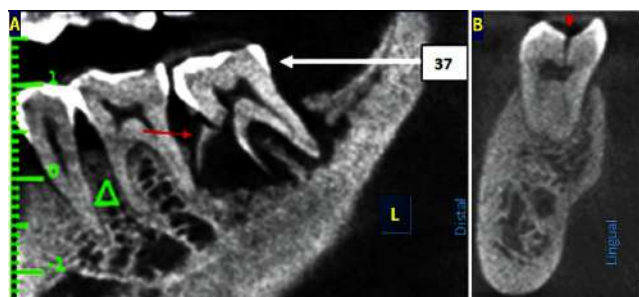


Fig. 10:

A vertical fracture of a molar tooth is displayed in Figure 11 B in a cross-sectional image. The fracture line extends from the middle of the occlusal surface of the molar, extending obliquely downwards towards the lingual side, up to the apical region of the root.

A case of fractured body of the mandible without displacement is illustrated in Figure 11. Figure 11 A reveals an oblique fracture line in the left side of mandible (in an axial section), beginning anteriorly from the buccal surface of the distal part of the first premolar (34), extending obliquely posterior, up to the lingual surface of the mesial part of 36. It runs through the medial surface of the second

premolar (35). The fracture lines starts superiorly from the alveolar crestal region, running obliquely downward almost till the lower border of the mandible, as revealed in the thin sections of panoramic images disclosed in Figure 11 B,C. Fracture of teeth in the involved region is not detected. Figure 11B demonstrates the anterior most fracture line with a corresponding 3D image viewed from the buccal side; while Figure 11 C shows the posterior most fracture line with a 3D image, viewed from the lingual side. Such complicated fracture requires multiple radiological views from different angles, accompanied by 3D reconstructed images, for quintessential understanding.

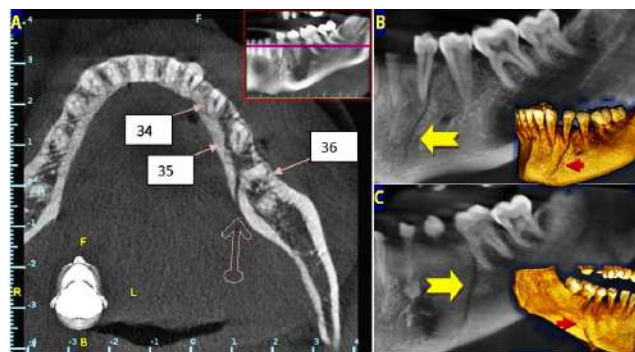

Fig. 11:

7. Incidental Findings

Careful and thorough evaluation of a large CBCT volume covering the entire maxillofacial area often leads to incidental findings (24.6% cases) with potential clinical significance.²⁵

The patient whose regiograph is shown in Figure 12, was primarily referred for evaluation of impacted left upper third molar (28). But a wider field of view uncovered some clinically relevant incidental findings. As revealed in Figure 12C, the apical third of left maxillary second premolar (25) bends mesially to join the apex of the adjacent premolar (14). Figure 12D,E in coronal and cross-sectional views respectively, revealed internal resorption of left maxillary canine (23). Such findings can go unnoticed in conventional radiographs. Moreover, careful scrutiny of an area may sometimes correctly identify the actual cause of pain or discomfort, that might have remained unnoticed by clinical or plain film radiographic evaluation.

Calcifications, such as tonsilloliths, sialoliths and carotid atherosclerosis are adequately viewed on CBCT images. It can also localise metal objects (broken needle, surgical wires etc) in the orofacial region.³

8. Implants

CBCT is the best imaging modality for pre-surgical (Figure 13A) and post surgical (Figure 13B) evaluation of

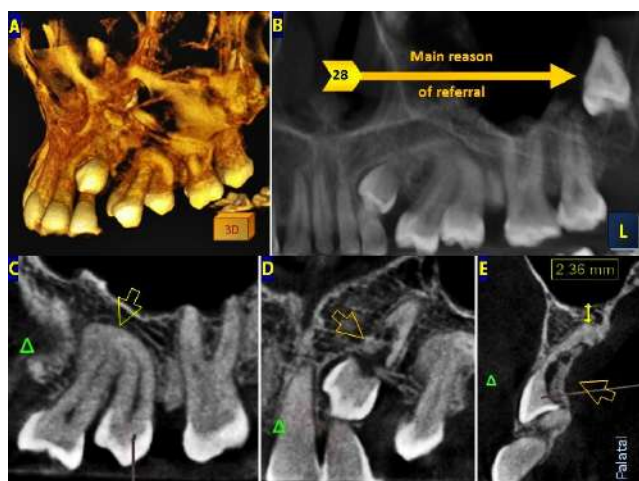


Fig. 12:

dental implant placement. The software enables simulation of implant placement to choose the ideal dimension, position and orientation.²⁶ Implant placement is the commonest cause of referral for CBCT evaluation in India. The vastness of this topic mandates its discussion as a separate article for a satisfactory coverage of the vital points.

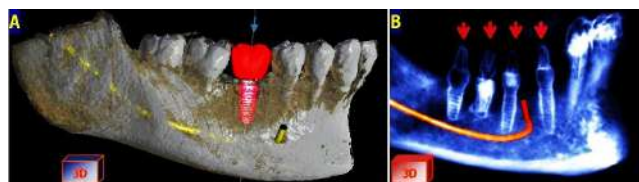


Fig. 13:

9. Conclusion

The current available literature indicates that CBCT diagnostic radiography provides true and precise anatomical information with high intraobserver and interobserver reproducibility. This enables accurate and reliable diagnoses thereby reducing the possibility of missing clinically relevant findings. This radiographic modality has a vast array of utility in oral surgery and allows pragmatic surgical planning and subsequent post-operative evaluation with submillimetric accuracy. Presently, CBCT renders profound benefits in different aspects of dentistry and is evolving further to expand its usefulness.

10. Source of Funding

None.

11. Conflict of Interest

The authors declare that there is no conflict of interest.

References

- Kuijpers MAR, Pazera A, Admiraal RJ, Bergé SJ, Vissink A, Pazera P. Arjan Vissink, Pawel Pazera. Incidental findings on cone beam computed tomography scans in cleft lip and palate patients. *Clin Oral Invest*. 2014;18:1237–44.
- Katheria BC, Kau CH, Täte R, Chen JW, English J, Bouquot J. Efficiency of impacted and supernumerary tooth diagnosis. *Pediatric dentistry*. *Pediatr Dent*. 2010;32(4):304–9.
- Ahmad M, Jenny J, Downie M. Application of cone beam computed tomography in oral and maxillofacial surgery. *Aust Dent J*. 2012;57(1):82–94. doi:10.1111/j.1834-7819.2011.01661.x.
- Bohay RN, Cox J, Lopointe HJ. Clinical Decision-Making: Cone Beam Computed Tomography for the Extraction of Impacted Mandibular Teeth. *Ont Dent*. 2011;p. 27–33.
- Barbosa GLR, Wood JS, Pimenta LA, Almeida SM, Tyndall DA. Comparison of different methods to assess alveolar cleft defects in cone beam CT images. *Dentomaxillofac Radiol*. 2016;45(2):1–6. doi:10.1259/dmfr.20150332.
- Price JB, Thaw KL, Tyndall DA, Ludlow JB, Padilla RJ. Incidental findings from cone beam computed tomography of the maxillofacial region: a descriptive retrospective study. *Clin Oral Implants Res*. 2012;23(11):1261–8. doi:10.1111/j.1600-0501.2011.02299.x.
- Tadinada A, Mahdian M, Vishwanath M, Allareddy V, Upadhyay M, Yadav S. Evaluation of alveolar bone dimensions in unilateral palatally impacted canine: a cone-beam computed tomographic analyses. *Eur J Orthod*. 2015;37(6):596–602. doi:10.1093/ejoc/cju098.
- Guerrero ME, Shahbazian M, Bekkering GE, Nackaerts O, Jacobs R, Horner K. The diagnostic efficacy of cone beam CT for impacted teeth and associated features: a systematic review. *J Oral Rehabil*. 2011;38(3):208–16. doi:10.1111/j.1365-2842.2010.02141.x.
- Mukherji A, Singh MP, Nahar P, Balaji BS, Mathur H, Goel S. Predicting pathology in impacted mandibular third molars. *J Indian Acad Oral Med Radiol*. 2017;29(1):20–4. doi:10.4103/jiaomr.jiaomr_83_16.
- Neves FS, Souza TC, Almeida SM, Haiter-Neto F, Freitas DQ, Bóscolo FN. Correlation of panoramic radiography and cone beam CT findings in the assessment of the relationship between impacted mandibular third molars and the mandibular canal. *Dentomaxillofac Radiol*. 2012;41(7):553–7. doi:10.1259/dmfr/22263461.
- Guerrero ME, Botetano R, Beltran J, Horner K, Jacobs R. Can preoperative imaging help to predict postoperative outcome after wisdom tooth removal? A randomized controlled trial using panoramic radiography versus cone-beam CT. *Clin Oral Investig*. 2014;18(1):335–42. doi:10.1007/s00784-013-0971-x.
- Matzen LH, Wenzel A. Efficacy of CBCT for assessment of impacted mandibular third molars: a review – based on a hierarchical model of evidence. *Dentomaxillofac Radiol*. 2015;44(1):1–11. doi:10.1259/dmfr.20140189.
- Lai CS, Suter VGA, Katsaros C, Bornstein MM. Localization of impacted maxillary canines and root resorption of neighbouring teeth: a study assessing the diagnostic value of panoramic radiographs in two groups of observers. *Eur J Orthod*. 2014;36(4):450–6. doi:10.1093/ejoc/cjt074.
- Ngo CTT, Fishman LS, Rossouw PE, Wang H, Said O. Omar Said. Correlation between panoramic radiography and cone-beam computed tomography in assessing maxillary impacted canines. *Angle Orthod*. 2018;88(4):384–9.
- Hadler-Olsen S, Pirttiniemi P, Kerosuo H, Limchaichana NB, Pesonen P, Pulkkinen SK, et al. Root resorptions related to ectopic and normal eruption of maxillary canine teeth – A 3D study. *Acta Odontol Scand*. 2015;73(8):609–15. doi:10.3109/00016357.2015.1020339.
- Primosch RE. Anterior supernumerary teeth-assessment and surgical intervention in children. *Pediatr Dent*. 1981;3(2):204–15.
- Al-Sheibany F, Marzouk HM, Salama FS, Salama. Cone Beam Computed Tomography Evaluation of Inverted Mesiodentes. *J Dent Children*. 2016;83(2):88–93.
- Chanani A, Adhikari HD. Reliability of cone beam computed tomography as a biopsy-independent tool in differential diagnosis of

- periapical cysts and granulomas: An In vivo Study. *J Conserv Dent.* 2017;20(5):326–31. doi:10.4103/jcd.jcd_124_17.
19. Suter VGA, Warnakulasuriya S, Reichart PA, Bornstein MM. Radiographic volume analysis as a novel tool to determine nasopalatine duct cyst dimensions and its association with presenting symptoms and postoperative complications. *Clin Oral Investig.* 2015;19(7):1611–8. doi:10.1007/s00784-014-1391-2.
 20. Friedland B, Metson R. A Guide to Recognizing Maxillary Sinus Pathology and for Deciding on Further Preoperative Assessment Prior to Maxillary Sinus Augmentation. *Int J Periodontics Restorative Dent.* 2014;34(6):807–15. doi:10.11607/prd.2043.
 21. Buyuk SK, Ercan E, Celikoglu M, Sekerci AE, Hatipoglu M. Evaluation of dehiscence and fenestration in adolescent patients affected by unilateral cleft lip and palate: A retrospective cone beam computed tomography study. *Angle Orthod.* 2016;86(3):431–6. doi:10.2319/042715-289.1.
 22. Florin WL, Mandel. Stafne bone cavity in the anterior mandible. *NY State Dent J.* 2010;76(3):36–8.
 23. Mattos JM, Palomo JM, Ruellas ACO, Cheib PL, Eliliwi M, Souki BQ. Three-dimensional positional assessment of glenoid fossae and mandibular condyles in patients with Class II subdivision malocclusion. *Angle Orthod.* 2017;87(6):847–54. doi:10.2319/121216-890.1.
 24. Barghan S, Tetradis S, Mallya SM. Application of cone beam computed tomography for assessment of the temporomandibular joints. *Aust Dent J.* 2012;57(1):109–18. doi:10.1111/j.1834-7819.2011.01663.x.
 25. Popat H, Drage N, Durning P. Mid-line clefts of the cervical vertebrae – an incidental finding arising from cone beam computed tomography of the dental patient. *Br Dent J.* 2008;204(6):303–6. doi:10.1038/bdj.2008.199.
 26. Mukherji A, Singh MP, Nahar P, Goel S, Mathur H, Khan Z. Why CBCT is imperative for implant placement. *J Indian Acad Oral Med Radiol.* 2019;31:363–9.

Author biography

Aveek Mukherji, Reader

Mohit Pal Singh, Professor and HOD

Prashant Nahar, Professor

S Bhuvaneshwari, Professor and HOD

Deeptanshu Daga, Senior Lecturer

Cite this article: Mukherji A, Singh MP, Nahar P, Bhuvaneshwari S, Daga D. Utilising CBCT in oral surgery. *J Oral Med, Oral Surg, Oral Pathol, Oral Radiol* 2021;7(2):91-97.