



Content available at: <https://www.ipinnovative.com/open-access-journals>

Journal of Oral Medicine, Oral Surgery, Oral Pathology and Oral Radiology

Journal homepage: www.joooo.org



Original Research Article

Coconut oil as a rehydrant in air dried oral buccal smears: An alternative to routine wet fixation

J Vini Mary Antony^{1,*}, Pratibha Ramani¹, Brundha²

¹Dept. of Oral and Maxillofacial Pathology, Saveetha Institute of Medical and Technical Sciences, Chennai, Tamil Nadu, India

²Dept. of General Pathology, Saveetha Institute of Medical Sciences, Chennai, Tamil Nadu, India



ARTICLE INFO

Article history:

Received 02-12-2021

Accepted 15-12-2021

Available online 14-01-2022

Keywords:

Pap smears

rehydration

Airdried

Coconut oil

ABSTRACT

The routine procedure to prepare a Pap smear is done by fixing the slides with 95% ethanol immediately after the sample is taken. This study was performed to determine the alternative method of air-drying and rehydration prior to alcohol fixation instead of conventional method. Paired buccal smears were collected from 50 patients who participated in the study. One set was labeled as (Wet fixed in 95% ethanol) WF and the other one Air-dried fixed (ARF) rehydrated and fixed with coconut oil. The staining quality of the slides was assessed with respect to nuclear details and cytoplasmic details, cytoplasmic staining and background staining. Single blinded study was done. The results were analyzed by Chi square test to compare the defined parameters between the two groups. Air-dried fixed (ARF) slides with coconut oil was significantly better with regard to clearance of background. There was statistically significant difference between the air dried smear rehydrated with coconut oil and normal wet fixed smear. So air dried smear rehydrated with coconut oil can be used as an alternative to wet fixed smear.

This is an Open Access (OA) journal, and articles are distributed under the terms of the [Creative Commons Attribution-NonCommercial-ShareAlike 4.0 License](https://creativecommons.org/licenses/by-nc-sa/4.0/), which allows others to remix, tweak, and build upon the work non-commercially, as long as appropriate credit is given and the new creations are licensed under the identical terms.

For reprints contact: reprint@ipinnovative.com

1. Introduction

Pap smear is a useful method for early detection of cancerous lesions and inflammatory conditions is routinely carried out worldwide and was first done in cervical smears to detect the cancerous lesions.¹ This new approach was then carried out in oral buccal smears to detect the cancerous lesions from the exfoliating cells. Smears were collected by the oral pathologist in hospitals or health centers. The routine practice is to fix the slides immediately in 95% ethanol and send them to laboratory to be stained and evaluated by cytopathologist. Tragically, inappropriate obsession and drying artifacts are common due to insufficient training and delayed fixation^{1,2} which lead to repeating smears, and expanding the workload or lose the patients. One elective strategy for overcoming

the issue of destitute obsession, presented over half a century back, is air-drying.³ This method has been offered for fine needle aspiration (FNA), effusion cytology and exfoliated cells, but few reports regarding it as a substitute technique for buccal smears are available.⁴ The current study was undertaken to evaluate the possibility of the routine use of rehydration of air-dried buccal smears with coconut oil.

2. Materials and Methods

Study was carried out at the department of Oral Pathology, Saveetha dental college for a period of 2 months. Random sampling was done. Samples were taken from the patients aged from 18 to 70 years. Oral buccal smears were taken from 50 patients. Two smears were taken from each patient, so a total of 100 smears were taken by the pathologist under direct vision using wooden spatulas. Among them 50

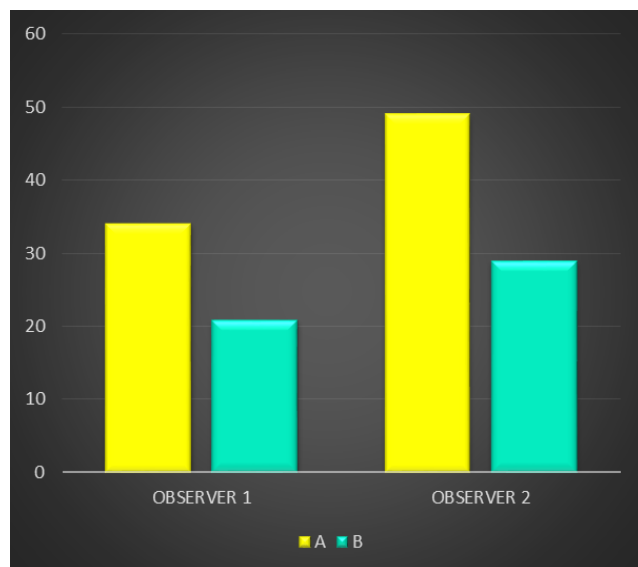
* Corresponding author.

E-mail address: jemeninoantony26@gmail.com (J. V. M. Antony).

was air dried and 50 was wet fixed smears. Two smears were taken from each patient. One smear was air-dried, rehydrated with coconut oil and was labeled as A. The other smear was immediately wet fixed in 95% ethanol and was labeled B. The air-dry smear (A) was dried by placing the slides on a rack exposed to room air for 24 hours and further rehydrated by using coconut oil for 5 minutes. Then the slides were coded, pooled and stained by standard Papanicolaou stain. The slides were examined blindly by a Cytopathologist by certain parameters. The parameters assessed are processing, presentation, staining which includes nuclear details, cytoplasmic details and background staining. The above criteria were assessed and a score was assigned to each slide to judge the cellular preservation and staining quality. The smears were decoded and separated into A and B and statistical analysis was then carried out. Using SPSS software, version 13, a comparison of two groups was carried out and p value less than 0.05 was considered significant.

3. Results

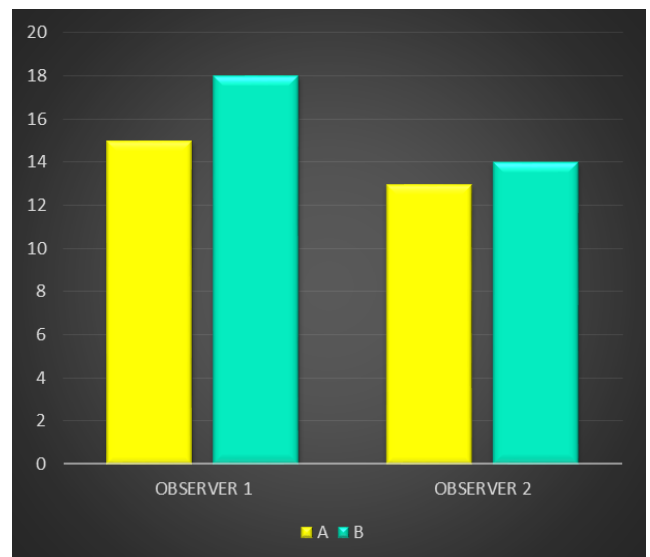
The results were calculated based on the scoring given for nuclear details, cytoplasmic details and background staining.(Graphs 1, 2, 3 and 4)



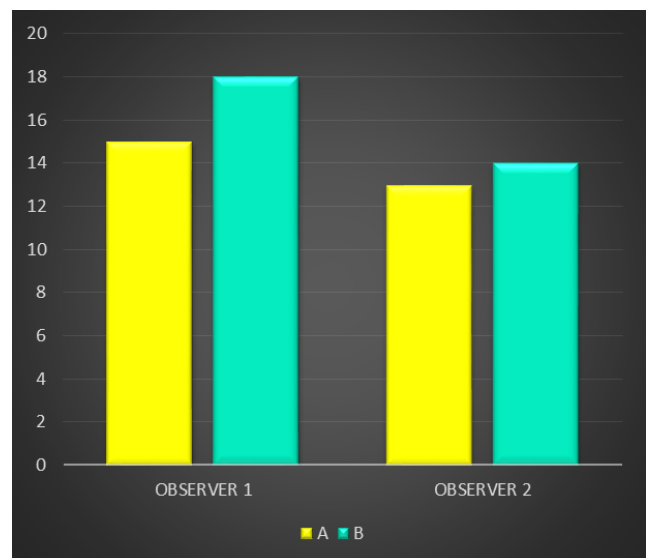
Graph 1: Nuclear staining

Graph 1 shows significant difference between the two groups. Group A -Air-dried fixed (ARF) showed good nuclear staining properties when compared to group B-Wet fixed in 95% ethanol (WF).

Graph 2 shows significant difference between the two groups. Group A-Air-dried fixed (ARF) showed good cytoplasmic staining properties when compared to group B-Wet fixed in 95% ethanol (WF).



Graph 2: Cytoplasmic staining



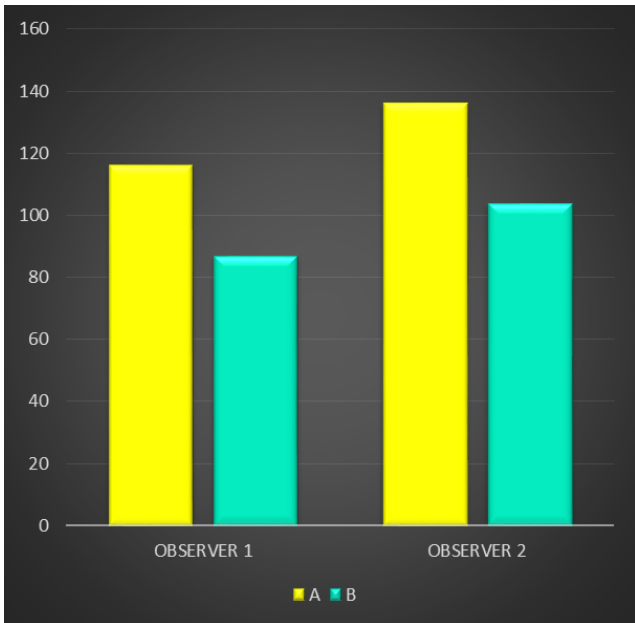
Graph 3: Background staining

Graph 3 shows significant difference between the two groups. Group B- Wet fixed in 95% ethanol (WF) showed good background staining properties when compared to group A -Air-dried fixed (ARF).

Graph 4 shows significant difference between the two groups. Group A -Air-dried fixed (ARF) showed good overall staining properties when compared to group B-Wet fixed in 95% ethanol (WF).

4. Discussion

Pap Stain is one of the universal stain to assess the oral buccal smears and provides maximum resemblance to corresponding cells in histologic sections. The staining



Graph 4: Overall comparison of the stain

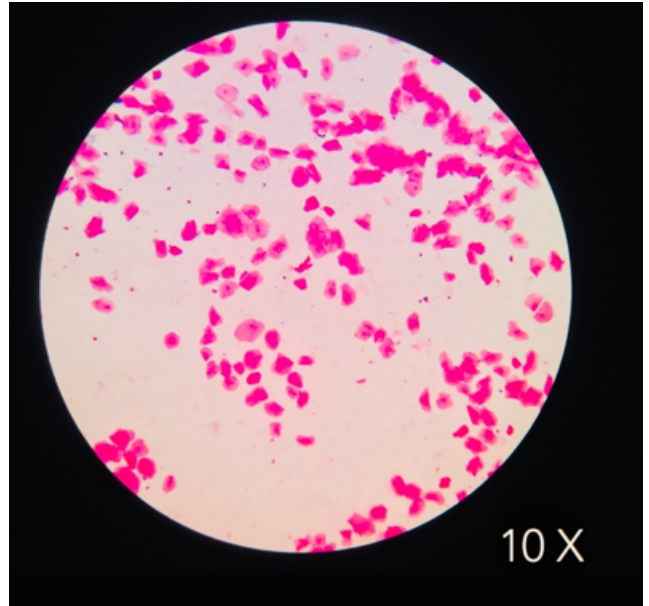


Fig. 2: Air dried smear rehydrated with coconut oil at 10 X magnification

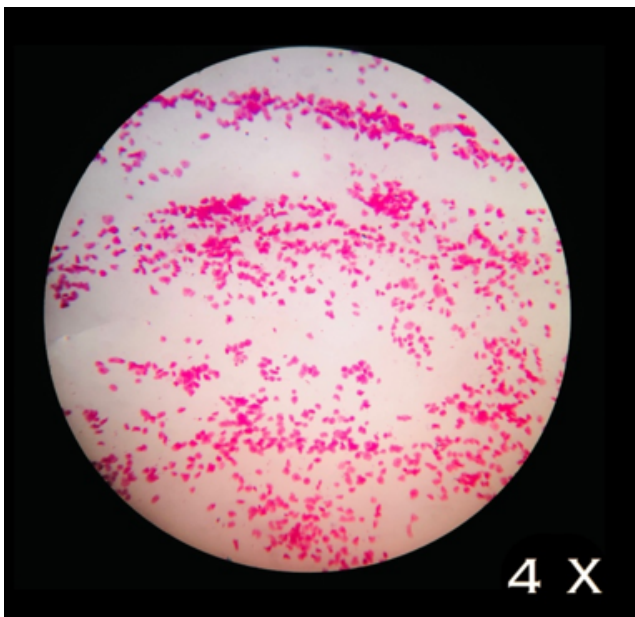


Fig. 1: Air dried smear rehydrated with coconut oil at 4 X magnification

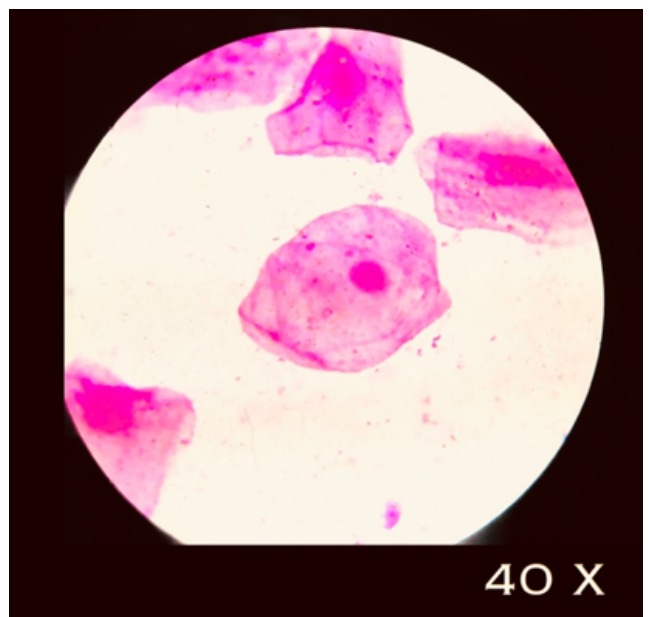


Fig. 3: Air dried smear rehydrated with coconut oil at 40 X magnification

is carried out usually after immediate fixation in 95% ethanol.⁴ Improper nuclear and cytoplasmic staining will be noted if the aspirate from the patient sample is minimal. The cells most commonly accumulate at the sides of the smear on glass slides. So, it's highly desirable to use methods to rehydrate these dried up cells. This study revealed that immersion of air-dried pap smears in coconut oil for 10 minutes can be used as a rehydrant technique. In fact, the clearer background was seen in ç smears rehydrated with coconut oil. The obtained results about nuclear staining showed significant difference between the air dried and wet fixed smear (Graph 1). The cytologic staining quality is excellent when compared to wet fixed smear (Graph 2). Rehydration of air-dried buccal smears showed good background staining properties (Graph 3) when compared to wet fix smear. The overall comparison of the staining properties gave a clear idea that Air dried smear showed excellent cytological and nuclear details (Table-4). The images of the Air dried smear (ARF) are depicted above under the low to high magnification. The procedure of air-drying and rehydration is straight forward, fast and inexpensive. This renders hunt for demonstrative cells less monotonous and maintain strategic distance from the issue of overlapping cellular details. The optimal time for clearing up the background is 10 minutes during rehydration procedure.⁵ Longer immersion in coconut oil is detrimental because of nuclear wrinkling. The maximum time of air-drying with well preservation of cellular details was up to four days.⁶ Rehydration is suggested for several other advantages as well: the smears are often spread more thinly and leisurely, the matter of lump larger particles or thicker portions of the smear in wet fixation are often avoided, the cells have better adhesion to slides, the cells are flatter and therefore the depth of specialisation in nuclei is far shallower, which is a great advantage in taking photomicrographs.⁶ This procedure can also be tried for FNAC, effusion cytology and exfoliated cells,⁷ and for other staining methods such as H&E,⁸ Giemsa⁹ and immunohistochemical staining^{10,11} Concurring to the current think about, we prescribe air-drying for 24 hours. Nonetheless, the routine use of the method might result in better smears and good cellular details.

5. Source of Funding

None.

6. Conflict of Interest

The authors declare no conflict of interest.

References

1. Sivaraman G, Iyengar KR. Rehydrated air-dried Pap smears as an alternative to wet-fixed smears. *Acta Cytol.* 2002;46(4):713–7.
2. Gupta S, Sodhani P, Chachra KL. Rehydration of airdried cervical smears: a feasible alternative to conventional wet fixation. *Obstet Gynecol.* 2003;102(4):761–4.
3. Lencioni LJ, Staffieri JJ, Cardonnet LJ. Vaginal and urinary sediment smear staining technique without previous fixation; adapted to Papanicolaou's and Shorr's staining methods. *J Lab Clin Med.* 1954;44(4):595–9.
4. Chan JK, Kung IT. Rehydration of air-dried smears with normal saline. Application in fine-needle aspiration cytologic examination. *Am J Clin Pathol.* 1988;89(1):30–4.
5. Ng WF, Choi FB, Cheung LL, Wu C, Leung CF, Ng CS. Rehydration of air-dried smears with normal saline. Application in fluid cytology. *Acta Cytol.* 1994;38(1):56–64.
6. Dahlstrom JE, Holdsworth J, Bassett ML, Jain S. Rehydration of air-dried smears. An alternative method for cytologic analysis of exfoliative cells. *Acta Cytol.* 1999;43(2):214–7.
7. Shidham VB, Kampalath B, England J. Routine air drying of all smears prepared during fine needle aspiration and intraoperative cytology studies. An opportunity to practice a unified protocol offering the flexibility of choosing a variety of staining methods. *Acta Cytol.* 2001;45(1):60–8.
8. Jones CA. Papanicolaou staining of air-dried smears: value in rapid diagnosis. *Cytopathology.* 1996;7(5):333–9.
9. Lencioni LJ, Staffieri JJ, Cardonnet LJ. Vaginal and urinary sediment smear staining technique without previous fixation; adapted to Papanicolaou's and Shorr's staining methods. *J Lab Clin Med.* 1954;44(4):595–9.
10. Kung IT. Application in fine-needle aspiration cytologic examination. *Am J Clin Pathol.* 1988;89(1):30–4.
11. Choi FB, Cheung LL, Wu C, Leung CF, Ng CS. Rehydration of air-dried smears. *Acta Cytol.* 1994;38(1):56–64.

Author biography

J Vini Mary Antony, -

Pratibha Ramani, HOD

Brundha, -

Cite this article: Antony JVM, Ramani P, Brundha. Coconut oil as a rehydrant in air dried oral buccal smears: An alternative to routine wet fixation. *J Oral Med, Oral Surg, Oral Pathol, Oral Radiol* 2021;7(4):222-225.