



Content available at: <https://www.ipinnovative.com/open-access-journals>

Journal of Oral Medicine, Oral Surgery, Oral Pathology and Oral Radiology

Journal homepage: [www.joooo.org](http://www.joooo.org)



## Original Research Article

# Nasolabial morphologic transformations after lefort-1 osteotomy — A prospective study

Aswin Mullath<sup>1,\*</sup>, Manoj Kumar K P<sup>1</sup>, Benny Joseph<sup>1</sup>, Aswathi Vinod<sup>1</sup>, Mohammed Faisal<sup>1</sup>, Tina Abraham<sup>1</sup>

<sup>1</sup>Dept. of Oral and Maxillofacial Surgery, KMCT Dental College, Mukkam, Kerala, India



### ARTICLE INFO

#### Article history:

Received 08-12-2021

Accepted 07-01-2022

Available online 25-03-2022

#### Keywords:

Orthognathic

Lefort 1 osteotomy

Nasolabial changes

Anthropometry

Alar cinch

### ABSTRACT

**Aim:** The present study was aimed to evaluate the morphologic changes of nose and lip after Lefort 1 osteotomy using clinical and cephalometric parameters

**Materials and Methods:** A prospective study to evaluate soft tissue changes after Lefort 1 osteotomy which includes 30 individuals of 18-35 years of age presented with dentofacial deformities. Our Study employs the measurement of nasolabial variables using Vernier caliper and lateral cephalograms. These values were recorded and tabulated under T<sub>1</sub> (pre-operative) and T<sub>2</sub> (6 months Post-operative). The final soft tissue changes were analyzed with paired t- test.

**Results:** Our study revealed statistically highly significant (p<0.001) increase in Alar base width, Nasolabial angle, Nasal tip angle and statistically significant (p<0.05) decrease in nasal tip protrusion.

**Conclusion:** Alar base widening is a definitive sequela after Lefort 1 osteotomy even after adopting techniques like alar base cinch suturing and V-Y closure. This warrants that further modifications or innovations are required for preventing these undesirable morphological changes.

This is an Open Access (OA) journal, and articles are distributed under the terms of the [Creative Commons Attribution-NonCommercial-ShareAlike 4.0 License](https://creativecommons.org/licenses/by-nc-sa/4.0/), which allows others to remix, tweak, and build upon the work non-commercially, as long as appropriate credit is given and the new creations are licensed under the identical terms.

For reprints contact: [reprint@ipinnovative.com](mailto:reprint@ipinnovative.com)

## 1. Introduction

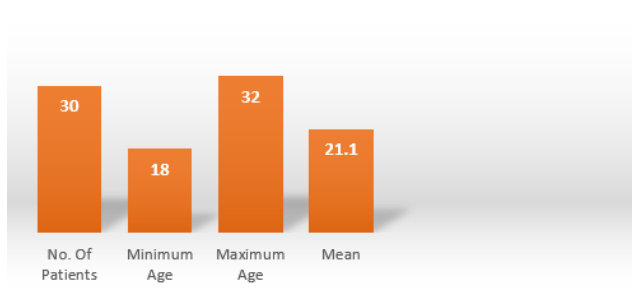
Facial aesthetics has direct impact on self-morale, confidence and even social acceptance of an individual. The harmony and proportion between facial skeleton and the soft tissue drape over it provides the visual impact of the face.<sup>1-3</sup> Orthognathic surgery, otherwise known as corrective jaw surgery, is aimed at correcting conditions of the jaw and face related to structure, growth, TMJ disorders, sleep apnea, malocclusion problems on account of skeletal disharmonies. Cephalometric radiographs became a tool in surgeons armamentarium for analyzing both hard and soft-tissues simultaneously on which various tracings were constructed, measured, and evaluated.<sup>3</sup>

Various studies have attempted to quantify the changes in facial soft tissue after orthognathic surgery. While some studies reported on the changes in soft tissue with maxillary intrusion, others evaluated outcomes of superior positioning of maxilla.<sup>4-7</sup> So the understanding of esthetic factors and prognostication of final facial soft tissue profile play a crucial role in planning orthognathic treatments. Nose is one of the key foundations of facial esthetics which is of central importance in planning and execution of orthognathic surgery. Patients with same type of occlusion and the same cephalometric skeletal values may have very different profiles solely on the basis of nasal structure and soft tissue. Hence minor alterations in nasal profile can cause facial disfigurements. So meticulous planning is the key to avoid undesirable changes. Standard or classical lateral cephalometric skeletal analysis need to be augmented in treatment planning in addition of soft tissue evaluations.<sup>8</sup>

\* Corresponding author.

E-mail address: [aswinmullath@gmail.com](mailto:aswinmullath@gmail.com) (A. Mullath).

Lefort 1 osteotomy is the most common versatile technique for correction of dentofacial deformities like Bimaxillary protrusion, vertical maxillary skeletal excess, nasomaxillary deficiency etc.<sup>9</sup> Secondary changes of the nasolabial region after the Lefort 1 osteotomy procedure are well known and include widening of the alar base of nose, upturning of nasal tip, flattening and thinning of upper lip and down turning of oral commissures. Of these post-surgical changes, alar base widening is the most common. Surgical techniques can modify these undesirable secondary changes to some extent.<sup>10,11</sup> To reorient the displaced peri nasal musculature and to control alar base width after maxillary osteotomies, many have advocated an alar base cinch suture along with adjunctive such as ANS reduction, nasal floor reduction and V-Y suturing before incision closure.<sup>12–14</sup> This study analyzes the nasolabial changes after Lefort 1 osteotomy.



Graph 1: Mean age of participants

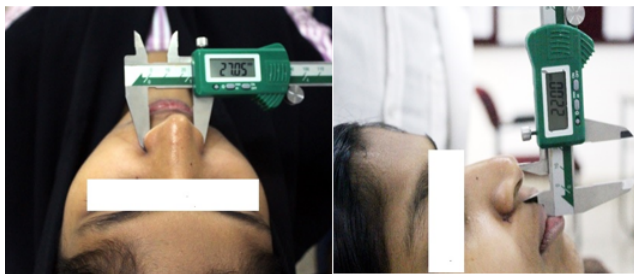

Fig. 1: Evaluation using vernier caliper (direct measurement)

## 2. Materials and Methods

This study was conducted as a clinical prospective observational study in 30 individuals of age group 18-35 years as per the inclusion criteria. All the patients underwent standard Lefort I osteotomy combined with or without superior positioning, Anterior Maxillary Osteotomy (AMO) setback or maxillary advancement

Our Study employs the measurement of nasolabial variables such as alar base width, nasal tip protrusion, nasolabial angle, and nasal tip angle to evaluate the soft

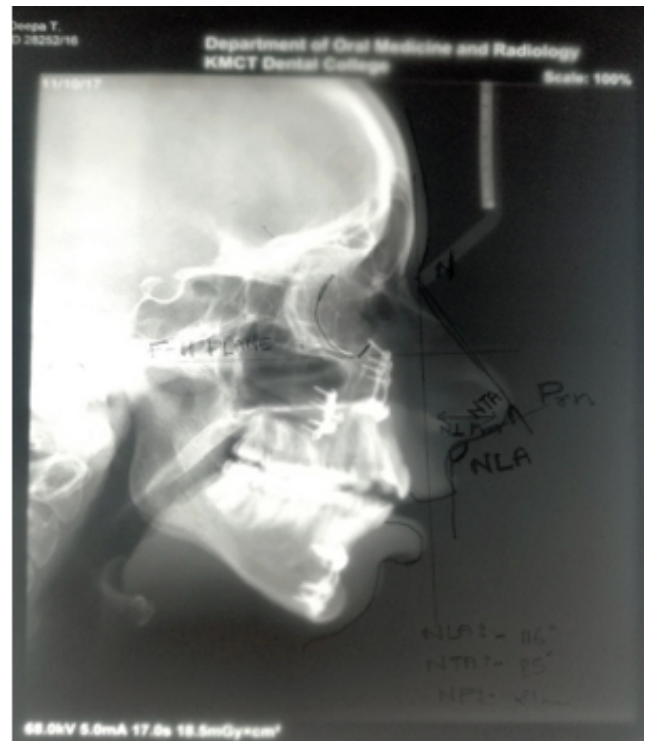

Fig. 2: Cephalometric Evaluation (Indirect measurement)

tissue changes. These values were recorded and tabulated under T<sub>1</sub> (pre-operative) and T<sub>2</sub> (6 months Post-operative). The final soft tissue changes were analyzed with paired t-test.

### 2.1. Inclusion criteria

1. Patients with maxillary prognathism, Bimaxillary protrusion, maxillary deficiency and vertical maxillary excess with or without mandibular skeletal discrepancies.
2. Age 18-35 years female/male.
3. Patient with or without pre-surgical orthodontics

### 2.2. Exclusion criteria

1. Temporomandibular joint disorders
2. Myofascial pain dysfunction syndrome
3. Patients associated with syndromes or systemic diseases
4. Congenital anomalies
5. Cleft lip and patients

### 2.3. Operative procedure

All the cases were operated under general anesthesia with Naso-endotracheal intubation following aseptic technique. All the 30 patients underwent standard Lefort I osteotomy procedure by same operator. Modified Alar cinch (23)

**Table 1:** Pre-operative and post-operative measurement of parameters

Parameters		Minimum	Maximum	Mean	Standard Deviation
Alar width (mm)	Pre	23.00	28.00	26.0423	1.3742
	Post	23.80	29.50	27.3277	1.3855
Nasal tip protrusion (mm)	Pre	20.00	26.00	23.0027	1.5563
	Post	19.60	26.00	22.7133	1.5678
Nasolabial angle (°)	Pre	72	120	87.23	10.510
	Post	80	116	92.37	9.023
Nasal tip angle (°)	Pre	67	88	76.83	5.831
	Post	69	90	79.07	5.959

**Table 2:** Comparison of parameters before and after surgery

Parameters		Paired Differences		P value
		Mean	Std. deviation	
Alar width (mm)	Pre	1.28533	0.61	0.000
	Post			
Nasal tip protrusion (mm)	Pre	0.28933	0.43	0.001
	Post			
Nasolabial angle (°)	Pre	5.133	2.98	0.000
	Post			
Nasal tip angle (°)	Pre	2.233	0.81	0.000
	Post			

P<0.05 — Significant\* p<0.001 — Highly significant\*\*

suturing and V-Y closure were employed in all the cases. Out of 30 patients, 11 patients underwent Lefort I superior positioning alone, 8 patients underwent Lefort 1 advancement + BSSO setback, 6 patients underwent Lefort 1 + AMO and 5 patients underwent Lefort 1 superior positioning + genioplasty

#### 2.4. Evaluation criteria

Clinical Evaluation Using Vernier Caliper (Direct Measurement)

The instrument used to record the manual anthropometry measurements was digital sliding Vernier caliper measuring in millimeters to the one hundredth decimal place. Measurements were taken with care, so that excessive manual pressure was not applied and tissues were not distorted.

Following parameters

1. Alar width inferior (alar base width)
2. Nasal tip protrusion (nasal tip to subnasale (Sn-Prn)).

Were measured in millimeters with Vernier caliper preoperatively (T1) and 6 months postoperatively (T2) on anthropometrical reference points<sup>15–38</sup> such as Point A (Left alar point), point B (Right alar point), Point S (columella/subnasale) & Point P (Nasal tip) located and marked on skin using a marker pen. During land-marking, the subjects sat in a relaxed position, with the Frankfort Horizontal plane parallel to the floor with their lips in repose. A single investigator recorded all the measurements.

(Figure 1)

Cephalometric Evaluation (Indirect Measurement)

1. A pre-operative lateral cephalogram (T 1) and 6 months postoperative (T2) were taken.
2. All the analysis was performed by the same operator to reduce intraoperative a. variability.
3. The following landmarks were hand-traced in cephalogram (Figure 2)(A)nasal tip angle (n-prn-sn), (B)nasolabial angle (prn –sn-ls)  
Where; n=nasion, prn=pronasale,sn=subnasale,ls=labrale superioris

#### 2.5. Statistical analysis

For evaluating soft tissue trends at different intervals Paired T- Test was performed. Mean change in each post-operative value (T2) from pre-operative value (T1) was tested against pre-operative value (T1) of each variable.

#### 2.6. Value was kept as 0 05

P< 0.05 was considered Significant, p < 0.001 was considered as highly significant.

Sample size was calculated using;  $n=(Z\alpha+Z\beta)^2 \times SD^2/d^2$

Where  $Z\alpha=1.96$ ,

$Z\beta=0.84$

SD=4

And  $d=2$  Sample size = 30

### 3. Results

A sample of 30 patients of age within 18-35 years with the mean age 21.13 were included in the study. The youngest patient was of 18 years and the oldest 32 years of age. (Graph 1). There were 19 female patients and 11 male patients who participated in the study.

Linear and angular measurements recorded for nasolabial analysis were-

1. Alar width inferior pre & Alar width inferior post
2. Nasal tip protrusion pre & Nasal tip protrusion post
3. Nasolabial angle pre & Nasolabial angle post
4. Nasal tip angle pre & Nasal tip angle post.

The mean of each soft tissue values was calculated at Pre-operative and post-operative 6 months. Mean of alar base width inferior, Nasolabial angle, and nasal tip angle showed an increasing trend during the 6-month post-operative period whereas mean of nasal tip protrusion showed decrease. (Tables 1 and 2)

Nasolabial soft tissue changes were compared using paired “t” test in all the patients. At the end of 6 months after the surgery, alar base width inferior, Nasolabial angle, and nasal tip angle showed statistically highly significant changes whereas change in nasal tip protrusion was statistically significant. (Table 2).

### 4. Discussion

The face, being the most distinguished body part, influences the confidence and self-esteem of an individual thereby modulates his/her social interaction.<sup>24</sup> Patients seeking correction of dentofacial deformity often present with a dislike of one or more aspect of their facial appearance. Therefore, recognition of aesthetic factors and prediction of the final facial profile after hard and soft tissue changes play an increasingly significant role in Orthognathic treatment planning.<sup>24,25</sup> Cephalometrics is a conventional, reliable and consistent diagnostic modality for treatment planning in orthognathic surgery. The cephalometric norms will varies from one ethnic group to another owing to the variations of the craniofacial morphology. Most importantly, in a country like India where there are intra-country variations in population is found to a great extent morphogenetically as well as linguistically and developing a specific norm as standard will be fallacious in nature. Hence, we have formulated further modifications in order to cater each diverse population and treatment planning according to these norms can benefit us with proportionate dentofacial harmony.<sup>26-43</sup>

Bimaxillary protrusion is one of the most prevalent dentofacial deformities in the Asian population that produces a convex facial profile. Orthodontic treatment combined with orthognathic surgery are treatments of choice. When required, orthognathic surgery may include

some combination of LeFort I osteotomy, Anterior Segmental osteotomy (ASO /AMO), bilateral sagittal split ramus osteotomy (BSSO). Vertical maxillary excess can be corrected by superiorly repositioning the maxilla through a Le Fort I osteotomy with or without segmental osteotomies.<sup>9</sup> After a Le Fort I osteotomy, nasal and labial changes are sometimes undesirable. The treatment planning needs to acknowledge the facial soft tissue response following the underlying skeletal reposition. Lefort I osteotomy and movement of the maxilla affect the position and shape of the overlying nose in particular ways. Widening of the alar base was consistently reported in the literature.<sup>21</sup> However, mixed nasal changes were reported for nasal tip projection and nasolabial angle. In order to avoid these mishaps, many have advocated soft tissue reorientation techniques like alar cinch suturing for the displaced perinasal musculature along with other adjunctive procedures (eg. ANS reduction, V-Y suturing and nasal floor reduction) before closure.<sup>13</sup>

In this study, we quantified the nasolabial soft tissue changes using clinical and cephalometric parameters with the help of Vernier caliper and lateral cephalogram respectively before and 6 months after orthognathic surgery, and evaluated if the nasal widening could be prevented by conventional methods like modified alar cinch technique<sup>22</sup> and V-Y closure.

A total of 30 patients who underwent Le Fort I osteotomy were studied for the changes in nasolabial soft tissue. Clinical measurements like alar base width and nasal tip protrusion were measured with Vernier caliper<sup>40</sup> on marked anthropometric reference points<sup>15</sup> (point A, point B, point S and point P). Simultaneously Lateral cephalograms at these visits were traced for analyzing nasolabial angle<sup>41</sup> and nasal tip angle. These values were compared using paired t- test to find out soft tissue changes.

In our study, a statistically highly significant increase was observed (ie.  $p < 0.001$ ) in alar base width of patients 6 months after surgery. Mean alar base inferior widening was  $1.28533 \pm 0.60980$ . So our study participants exhibited a significant widening of the alar base post-operatively even after the implementation of various surgical techniques such as alar cinch suturing and V-Y closure which are used to prevent these deformities.<sup>13</sup> Previous literatures suggests that widening of the nasal alae was caused by the release of the muscle insertion and their retraction during subperiosteal dissection and this change was not influenced by the direction of maxillary movements.<sup>15</sup>

An increase of 2-4mm in the width of nasal ala is consistent finding after surgical maxillary intrusion at the Lefort 1 level using standard soft tissue incisions and V-Y closure,<sup>16-19</sup> Previous studies disclosed a range of postoperative widening of 2.9 to 10.8% for standard/classical alar cinch suture,<sup>10,11,29,30</sup> And those studies which incorporated modifications in cinch suturing

reported 0.5 to 4.0% increases in alar width<sup>22,31,32</sup> These findings were comparable to present study.

In the present study, a statistically significant reduction in the Nasal tip protrusion (sn-prn)<sup>33</sup> was observed (ie.  $p < 0.05$ ) 6 months post-operatively. We also observed a trend in which pronasale moved inferiorly in the Lefort I impaction group after the surgery.<sup>14</sup> This further indicates that maxillary surgical retraction/setback associated with septal reduction and ANS recontouring resulted in the reduction of nasal tip protrusion which was aesthetically acceptable for our study population even though it was an undesirable change. So, In our study the possible reasons for significant reduction in Nasal tip protrusion or depression in nasal tip may be due to hard tissue movements, new positioning of ANS or distortion of soft tissues with dissection.<sup>20,29</sup>

In our study, statistically highly significant (ie.  $p < 0.001$ ) increase in nasolabial angle was noticed. Mean increase in nasolabial angle was  $5.133 \pm 2.980$  six months after surgery which indicates a better cosmetic outcome which became closer proximity to normal standard values of  $102^\circ$ .<sup>4</sup> Radney et al.<sup>44</sup> Westermarck et al.<sup>19</sup> and Nadkarni P G<sup>42</sup> found an increase in nasolabial angles to  $9^\circ$  in their study reports. It is said that an increase in nasolabial angle was mainly attributed to the retraction of Labrale Superius (Ls) rather than movements of nasal landmar so it should be calculated to determine whether this change improves the patient's esthetic requirements.

Our present study also showed statistically highly significant increase (i.e.  $p < 0.001$ ) in nasal tip angle (N-Prn-Cm)<sup>15,36,37</sup> 6 months post-operatively. The average 6 months post-operative value is  $79.07 \pm 5.831$  which was  $76.83 \pm 5.959$  before surgery. We noticed a mean increase of  $2.233 \pm 0.817$  after surgery among our study participants According to Lines et al. (1978), nasal tip angle is most acceptable between 60 and 80 degrees.<sup>36</sup> The values of nasal tip angle in our study are within that range. From our study we found that the alar base widening cannot be completely prevented but can be reduced to some extent after the implementation of modified alar cinch suturing and other adjunctives. Other nasolabial Soft tissue changes like increase in nasolabial angle and nasal tip angle showed desirable esthetic outcomes whereas significant decrease in nasal tip protrusion was not cosmetically acceptable.

## 5. Conclusion

The present study reveals that alar base widening is a definitive undesirable sequela after Lefort I osteotomy which can only be foreshortened by performing conventional techniques like alar base cinch suturing, V-Y closure etc. Previous studies in the past also revealed similar results and present study supports these findings. Therefore, this clearly indicates that further modifications or innovations are required for betterment of this matter. Meticulous treatment planning with conventional tools

like incorporation of cephalometric norms and newer modifications of adjunctive procedures like modified cinch suturing can furnish a better outcome. The scope for further studies with strict protocol, larger sample size, long follow-up period and higher level of statistics is open.

## 6. Source of Funding

None.

## 7. Conflict of Interest

None.

## References

1. Taki AA, Oguz F, Abuhijleh E. Facial soft tissue values in Persian adults with normal occlusion and well-balanced faces. *Angle Orthod.* 2009;79(3):491–5. doi:10.2319/020408-62.1.
2. Riedel RA. An analysis of dentofacial relationships. *Am J Orthod.* 1957;43(2):103–22. doi:10.1016/0002-9416(57)90220-8.
3. Bloom LA. Perioral profile changes in orthodontic treatment. *Am J Orthod Dentofac Orthop.* 1961;47(5):371–80. doi:10.1016/0002-9416(61)90177-4.
4. Legan HL, Burstone CJ. Soft tissue cephalometric analysis for orthognathic surgery. *J Oral Surg.* 1980;38(10):744–51.
5. Varlık SK, Demirbaş E, Orhan M. Influence of lower facial height changes on frontal facial attractiveness and perception of treatment need by lay people. *Angle Orthod.* 2010;80(6):1159–64. doi:10.2319/032509-176.1.
6. Papadopoulos MA, Terzoudi TL, land J, Athanasiou AE, Melsen B. Comparison of soft and hard tissue profiles of orthognathic surgery patients treated recently and 20 years earlier. *Oral Surg Oral Med Oral Pathol Oral Radiol Endod.* 2009;108(1):8–13. doi:10.1016/j.tripleo.2009.03.025.
7. Mccance AM, Moss JP, Wright WR, Linney AD, James DR. A three-dimensional soft tissue analysis of 16 skeletal class III patients following bimaxillary surgery. *Br J Oral Maxillofac Surg.* 1992;30(4):221–53. doi:10.1016/0266-4356(92)90264-J.
8. Peck GC, Michelson LN. Anatomy of Aesthetic Surgery of the Nose. *Clin Plast Surg.* 1987;14:737–85.
9. Chu YM, Bergeron L, Chen YR. Bimaxillary protrusion: an overview of the surgical-orthodontic treatment. *Semin Plast Surg.* 2009;23(1):32–3. doi:10.1055/s-0028-1110099.
10. Schendel SA, Williamson LW. Muscle reorientation following superior repositioning of the maxilla. *J Oral Maxillofac Surg.* 1983;41(4):235–75. doi:10.1016/0278-2391(83)90265-3.
11. Betts NJ, Vig KW, Vig P, Spalding P, Fonseca RJ. Changes in the nasal and labial soft tissues after surgical repositioning of the maxilla. *Int J Adult Orthod Orthognathic Surg.* 1993;8(1):7–23.
12. Millard JR. The alar cinch in the flat, flaring nose. *Plast Reconstr Surg.* 1980;65(5):669–72. doi:10.1097/00006534-198005000-00020.
13. Collins PC, Epker BN. The alar base cinch: a technique for prevention of alar base flaring secondary to maxillary surgery. *Oral Surg Oral Med Oral Pathol.* 1982;53(6):549–53. doi:10.1016/0030-4220(82)90338-3.
14. Guymon M, Crosby DR, Wolford LM. The alar base cinch suture to control nasal width in maxillary osteotomies. *Int J Adult Orthodontics Orthognathic Surg.* 1988;3(2):89–95.
15. Yamada T, Mishima K, Moritani N, Janune D, Matsumura T, Ikeya Y. Nasolabial morphologic changes after a Le Fort I osteotomy: a three-dimensional anthropometric study. *J Craniofac Surg.* 2010;21(4):1089–95. doi:10.1097/SCS.0b013e3181e1e6ff.
16. Rosen HM. Lip-nasal aesthetics following Le Fort I osteotomy. *Plast Reconstr Surg.* 1988;81(2):171–82. doi:10.1097/00006534-198802000-00005.

17. Gassmann CJ, Nishioka GJ, Van Sickels JE, Thrash WJ. A lateral cephalometric analysis of nasal morphology following Le Fort I osteotomy applying photometric analysis techniques. *J Oral Maxillofac Surg.* 1989;47(9):926–56. doi:10.1016/0278-2391(89)90375-3.
18. Schendel SA, Carlotti JR. Nasal Considerations in Orthognathic Surgery. *Am J Orthod Dentofac Orthop.* 1991;100(3):197–208. doi:10.1016/0889-5406(91)70056-3.
19. Westermarck AH, Bystedt H, Konow LV, Sällström KO. Nasolabial morphology after Le Fort I osteotomies. Effect of alar base suture. *Int J Oral Maxillofac Surg.* 1991;20(1):25–30. doi:10.1016/s0901-5027(05)80690-3.
20. Mcfarlane RB, Frydman WL, McCabe SB, Mamandras AM. Identification of nasal morphologic features that indicate susceptibility to nasal tip defection with the LeFort I osteotomy. *Am J Orthod Dentofac Orthop.* 1995;107(3):259–67. doi:10.1016/s0901-5027(05)80690-3.
21. Altman JI, Oeltjen JC. Nasal deformities associated with orthognathic surgery: analysis, prevention, and correction. *J Craniofac Surg.* 2007;18(4):734–9. doi:10.1097/SCS.0b013e3180684328.
22. Nirvikalpa N, Narayanan V, Wahab A, Ramadorai A. Comparison between the classical and a modified trans-septal technique of alar cinching for Le Fort I osteotomies: a prospective randomized controlled trial. *Int J Oral Maxillofac Surg.* 2013;42(1):49–54. doi:10.1016/j.ijom.2012.05.027.
23. Worasakwutiphong S, Chuang YF, Chang HW, Lin HH, Lin PJ, Lo LJ. Nasal changes after orthognathic surgery for patients with prognathism and Class III malocclusion: analysis using three-dimensional photogrammetry. *J Formosan Med Assoc.* 2015;114(2):112–35. doi:10.1016/j.jfma.2014.10.003.
24. Erbe C, Mulié RM, Ruf S. Advancement genioplasty in Class I patients: predictability and stability of facial profile changes. *Int J Oral Maxillofac Surg.* 2011;40(11):1258–62. doi:10.1016/j.ijom.2011.04.014.
25. Chew MT, Sandham A, Soh J, Wong HB. Outcome of orthognathic surgery in Chinese patients: a subjective and objective evaluation. *Angle Orthod.* 2007;77(5):845–50. doi:10.2319/091906-378.
26. Yadav AO, Walia CS, Borle RM, Chaoji KH, Rajan R, Datarkar AN. Cephalometric norms for Central Indian population using Burstone and Legan analysis. *Indian J Dent Res.* 2011;22(1):28–33. doi:10.4103/0970-9290.79970.
27. Milošević SA, Varga MM, Šljaj M. Analysis of the soft tissue facial profile by means of angular measurements. *Eur J Orthod.* 2008;30(2):135–75. doi:10.1093/ejo/cjm116.
28. Phillips C, Devereux JP, Camilla TJ, Tucker MR. Full-face soft tissue response to surgical maxillary intrusion. *Int J Adult Orthod Orthognathic Surg.* 1986;1(4):299–304.
29. Mommaerts MY, Abeloos JV, De CC, Neyt LF. The effect of the subspinal Le Fort I-type osteotomy on interalar rim width. *Int J Adult Orthod Orthog Surg.* 1997;12(2):95–100.
30. Kaminishi RM, Davis WH, Hochwald DA, Nelson N. Improved maxillary stability with modified LeFort I technique. *J Oral Maxillofac Surg.* 1983;41(3):203–8.
31. Rauso R, Gherardini G, Santillo V, Biondi P, Santagata M, Tartaro G. Comparison of two techniques of cinch suturing to avoid widening of the base of the nose after Le Fort I osteotomy. *Br J Oral Maxillofac Surg.* 2010;48(5):356–65. doi:10.1016/j.bjoms.2009.08.007.
32. Ritto FG, Medeiros PJ, De Moraes M, Ribeiro DP. Comparative analysis of two different alar base sutures after Le Fort I osteotomy: randomized double-blind controlled trial. *Comparative analysis of two different alar base sutures after Le Fort I osteotomy: randomized double-blind controlled trial Oral Surgery, Oral Medicine, Oral Pathology, Oral Radiology, and Endodontology.* 2011;111(2):181–190. doi:10.1016/j.tripleo.2010.04.019.
33. El-Hakim H, Crysedale WS, Abdollel M, Farkas LG. A study of anthropometric measures before and after external septoplasty in children: a preliminary study. *Arch Otolaryngol Head Neck Surg.* 2001;127(11):1362–8. doi:10.1001/archotol.127.11.1362.
34. Jayaratne YS, Zwahlen RA, Lo J, Cheung LK. Facial soft tissue response to anterior segmental osteotomies: a systematic review. *Int J Oral Maxillofac Surg.* 2010;39(11):1050–8. doi:10.1016/j.ijom.2010.07.002.
35. Lee JY, Kim YI, Hwang DS, Park SB. Effect of setback Le Fort I osteotomy on midfacial soft-tissue changes as evaluated by cone-beam computed tomography superimposition for cases of skeletal Class III malocclusion. *Int J Oral Maxillofac Surg.* 2013;42(6):790–5. doi:10.1016/j.ijom.2012.11.012.
36. Lines PA, Lines RR, Lines CA. Profilemetrics and facial esthetics. *American Journal of Orthodontics and Dentofacial Orthopedics.* 1978;73(6):648–57.
37. Prasad M, Chaitanya N, Reddy KP, Talapaneni AK, Myla VB, Shetty SK. Evaluation of nasal morphology in predicting vertical and sagittal maxillary skeletal discrepancies. *Eur J Dent.* 2014;8(2):197–204. doi:10.4103/1305-7456.130600.
38. Farkas LG, Phillips JH, Katic M. Anthropometric anatomical and morphological nose widths in Canadian Caucasian adults. *Can J Plastic Surg.* 1998;6(3):149–51. doi:10.1177/229255039800600302.
39. Burstone CJ, James RB, Legan H, Murphy GA, Norton LA. Cephalometrics for orthognathic surgery. *J Oral Surg.* 1965;36(4):269–77.
40. Shivhare P, Shankarnarayan L, Basavaraju SM, Gupta A, Vasani V, Jambunath U. Inter-canine width as a tool in two dimensional reconstruction of face: an aid in forensic dentistry. *J forensic Dent Sci.* 2015;7(1):1–1. doi:10.4103/0975-1475.150290.
41. Dua V, Gupta S, Singh C. Evaluation of the nasolabial angle in the Indian population. *Contemp Clin Dent.* 2010;1(2):79–82. doi:10.4103/0976-237X.68595.
42. Nadkarni PG. Soft tissue profile changes associated with orthognathic surgery for bimaxillary protrusion. *J Oral Maxillofac Surg.* 1986;44(11):851–5. doi:10.1016/0278-2391(86)90220-x.
43. Purushothaman B, Raveendran R, Sundareswaran S, Harindranathan M. Soft tissue cephalometric norms of Malabar population in Northern Kerala: an epidemiologic study. *J Indian Orthod Soc.* 2012;46(2):65–74. doi:10.5005/jp-journals-10021-1062.
44. Radney LJ, Jacobs JD. Soft-tissue changes associated with surgical total maxillary intrusion. *Am J Orthod.* 1981;80(2):191–212. doi:10.1016/0002-9416(81)90218-9.

## Author biography

**Aswin Mullath**, Assistant Professor

**Manoj Kumar K P**, Professor

**Benny Joseph**, Professor

**Aswathi Vinod**, Assistant Professor

**Mohammed Faisal**, Consultant

**Tina Abraham**, Consultant

**Cite this article:** Mullath A, Manoj Kumar K P, Joseph B, Vinod A, Faisal M, Abraham T. Nasolabial morphologic transformations after lefort-1 osteotomy — A prospective study. *J Oral Med, Oral Surg, Oral Pathol, Oral Radiol* 2022;8(1):35-40.