



Content available at: <https://www.ipinnovative.com/open-access-journals>

Journal of Oral Medicine, Oral Surgery, Oral Pathology and Oral Radiology

Journal homepage: www.joooo.org



Case Report

Non-surgical management of a large periapical lesion using triple antibiotic paste: A case report

Ashok Kumar Mohanty¹, Dhirendra Kumar^{1,*}

¹Dept. of Dental Surgery, Tata Steel Hospital, Noamundi, Jharkhand, India



ARTICLE INFO

Article history:

Received 29-11-2021

Accepted 13-12-2021

Available online 25-03-2022

Keywords:

Nonsurgical root canal treatment

Periapical lesion

Triple antibiotic paste (TAP)

ABSTRACT

Root canal infection is considered to be a polymicrobial infection, consisting of both aerobic and anaerobic bacteria. Because of the complexity of the root canal infection, it is unlikely that any single antibiotic could result in effective sterilization of the canal. A combination of antibiotic drugs (metronidazole, ciprofloxacin, and minocycline/doxycycline in this case) is used to eliminate bacteria, which are possible sources of endodontic lesions. Case report describes the nonsurgical endodontic treatment of maxillary right central and lateral incisor with large periapical lesion. A triple antibiotic paste was used for 4 months at monthly interval. After 4 months, teeth was asymptomatic and was obturated. Complete periapical healing was observed at the 24-month recall. This report confirms that for treatment of a large periapical lesion it is not always necessary to do surgical treatment and even cyst-like periapical lesions heal following conservative endodontic therapy. The results of the case show that when most commonly used medicaments fail in eliminating the symptoms, then a triple antibiotic paste can be used clinically in the treatment of teeth with large periapical lesion.

This is an Open Access (OA) journal, and articles are distributed under the terms of the [Creative Commons Attribution-NonCommercial-ShareAlike 4.0 License](https://creativecommons.org/licenses/by-nc-sa/4.0/), which allows others to remix, tweak, and build upon the work non-commercially, as long as appropriate credit is given and the new creations are licensed under the identical terms.

For reprints contact: reprint@ipinnovative.com

1. Introduction

Traumatic injury to tooth generally disrupts the pulpal blood supply causing pulp necrosis and leading to anaerobic conditions favoring the growth of microorganisms, which resulting in the development of periapical lesions. Periapical lesions generally represent an inflammatory response to invasion of the root canal system by microorganisms and their by-products.¹ Such lesions grow due to osmotic fluid accumulation in the lumen, epithelial proliferation, and molecular mechanisms. If the lesion is effectively evacuated of the inflammatory exudates reducing the hydrostatic pressure and if the microbiological etiology is removed by nonsurgical root canal treatment, these lesions may regress by the mechanisms of apoptosis.¹ The polymicrobial infection makes sterilization of the root canal difficult.

Chemomechanical debridement, thorough disinfection of root canal anatomy and proper obturation is main necessity of endodontic therapy.² Calcium hydroxide has been commonly used as an intracanal medicament, however, it has been reported that it is not effective in disinfecting the root canal system associated with persistent endodontic infections. The Cariology Research Unit of the Niigata University School of Dentistry has developed the concept of 'Lesion Sterilization and Tissue Repair (LSTR) therapy that uses a triple antibiotic paste of ciprofloxacin, metronidazole, and minocycline for disinfection, shown to be very effective in eliminating endodontic pathogens. Cefaclor and fosfomycin are proposed as possible alternatives for minocycline, in terms of their antibiotic effectiveness, but further clinical studies are needed to demonstrate their efficacy in the root canal.³

* Corresponding author.

E-mail address: dhirendra.kumar925@gmail.com (D. Kumar).

2. Case History

A 20-year-old boy reported to Dental Dept. Tata steel Hospital, Noamundi because of swelling and pain in his upper anterior region. His medical history was noncontributory. He gave a history of trauma to his upper anterior teeth 10 years back which was left untreated.⁴ An extraoral examination revealed a diffuse swelling on the right side of upper lip. An intraoral examination showed discolored and tender maxillary right central and lateral incisors. Patient was prescribed antibiotic, analgesic with anti inflammatory and warm saline mouth rinse. After 5 days symptoms subsided and radiograph taken, which showed a well-circumscribed large radiolucent lesion with well-defined margins involving the apices of teeth 11 and 12. The lesion was approximately 15x10 mm in diameter.⁵

2.1. Preoperative radiograph

Thermal testing was negative for tooth 11,12. Taking into account the medical and dental history of the patient, a presumptive diagnosis of periapical cyst was established. Nonsurgical endodontic root canal treatment of teeth 12 and 11 was planned. Following access opening was done both teeth was gauged using hand K-files size 45 for tooth 11 and size 30 for tooth 12, a thick purulent discharge exuded from the orifices of the canals. The root canals was prepared with protaper NEXT rotary files X1, X2, X3 using EDTA and carbamide peroxide gel. During the instrumentation, the canal was irrigated copiously with a 3.4%w/v sodium hypochlorite solution, normal saline and metronidazole solution. The final irrigation was performed with 2% Chlorhexidine Digluconate solution.^{6,7} The canals were dried and the calcium hydroxide dressing was given. And the access cavity was temporarily sealed with Orafil G. The patient was advised warm saline mouth rinses.

The calcium hydroxide dressing was changed every 1 week for four times. As the discharge did not cease completely and the symptoms still persisted, the treatment procedure was changed. The canals were irrigated and dried, a triple antibiotic paste consisting of ciprofloxacin, metronidazole, and doxycycline was placed in the canal with the help of a lentulo spiral and teeth were temporized. The paste was changed every month for a period of 4 months until the teeth displayed no symptoms. On examination, the teeth showed no pain on percussion, soft tissues were found healthy, and the canals were dry. The canals were irrigated with 3.4% w/v sodium hypochlorite solution followed by normal saline and metronidazole solution, 2% chlorhexidine solution and obturated with 6% gutta-percha and AH 26 sealer after 4 months. After 24 months the radiograph showed complete bony healing with well-defined trabeculae.

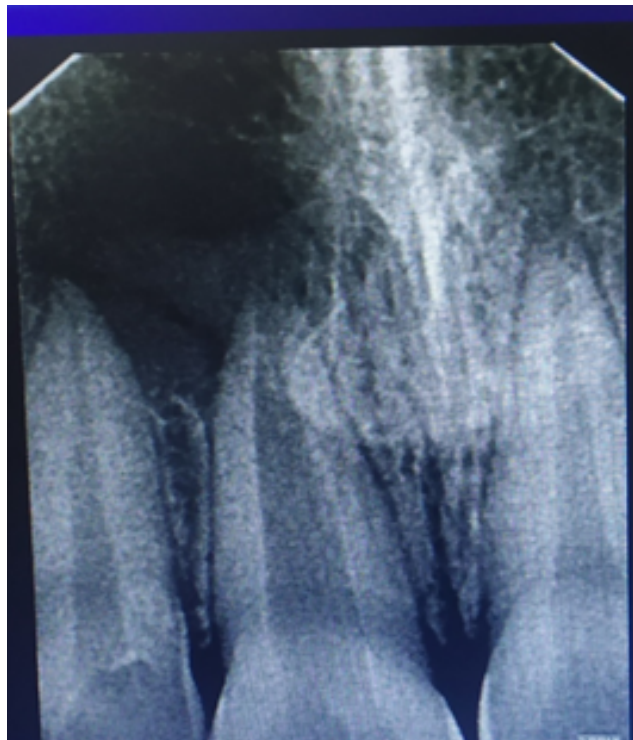

Fig. 1: Preoperative radiograph

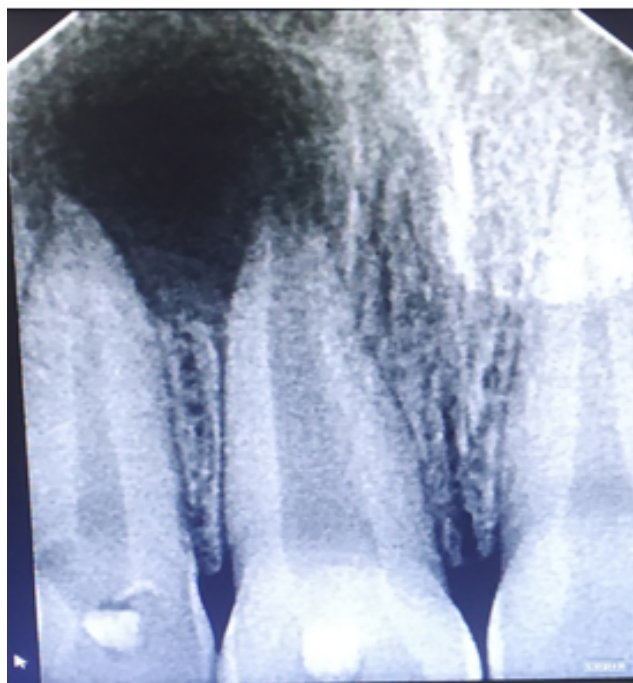

Fig. 2: Radiograph after 1 month

3. Discussion

The development and progression of endodontically induced periapical lesions is clearly associated with the presence of microorganisms in the root canal system. There are surgical and nonsurgical methods to treat such cases. The success of the nonsurgical endodontic treatment method is based on appropriate cleaning, shaping, asepsis, and filling of the root canal. Calcium hydroxide is the most commonly used medicament for the asepsis of the root canal because of its high alkalinity and antibacterial activity.⁸ Action of calcium hydroxide beyond the apex may be four-fold: (a) anti-inflammatory activity, (b) neutralization of acid products, (c) activation of the alkaline phosphatase, and (d) antibacterial action due to high pH and also to the absorption of carbon dioxide upon which the metabolic activities of many root canal pathogens depend. In this study, calcium hydroxide was used, but the symptoms were not relieved. The treatment protocol was changed, and a triple antibiotic paste was used instead. After its application, the symptoms resolved. Since the overwhelming majority of bacteria in the deep layers of the infected dentine of the root canal wall consist of obligate anaerobes, metronidazole was selected as the first choice among antibacterial drugs. It is reported that metronidazole can penetrate the deep layers of carious lesions and disinfect the lesions and diffuse throughout the dentine. As the bacterial flora of the root canal with a periradicular lesion is complex in nature, metronidazole alone cannot kill all bacteria, indicating that other drugs may be necessary to sterilize the infected root dentine. Thus, ciprofloxacin and minocycline, in addition to metronidazole were required to sterilize the infected root dentine. TAP contains both bactericidal (ciprofloxacin and metronidazole) and bacteriostatic (minocycline) agents to allow for successful revascularization. TAP is able to remove diverse groups of gram +ve, gram -ve and anaerobic bacteria providing healing environment. In regeneration protocol cases, this allows the development, disinfection and sterilization of root canal, so that new tissue can infiltrate and grow into radicular area. Although the volumes of the drugs applied in this therapy were small and there were no reports of side effects, care should be taken if patients are sensitive to chemicals or antibiotics.

4. Conclusion

When the most commonly used medicament fail to eliminate the symptoms, then a triple antibiotic paste can be used as an alternative material. The periradicular lesion in this case was large but showed progressive healing after using a triple antibiotic paste in the canal. Every effort should be made to treat such lesions irrespective of size by a nonsurgical endodontic treatment method.

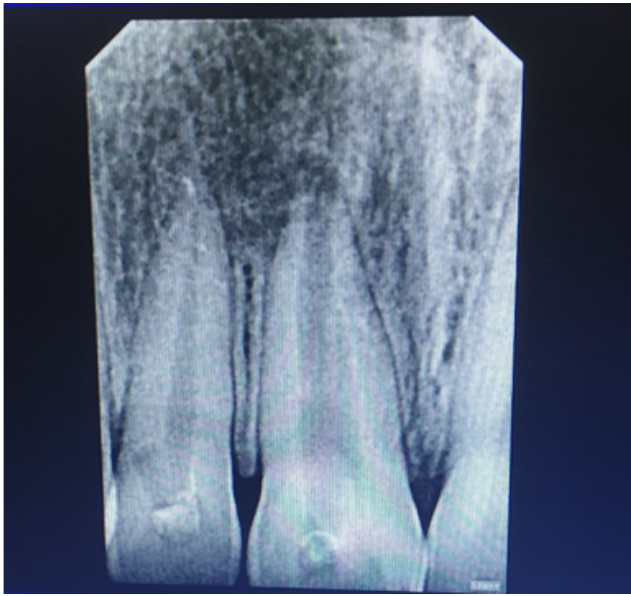


Fig. 3: Radiograph after 4 months

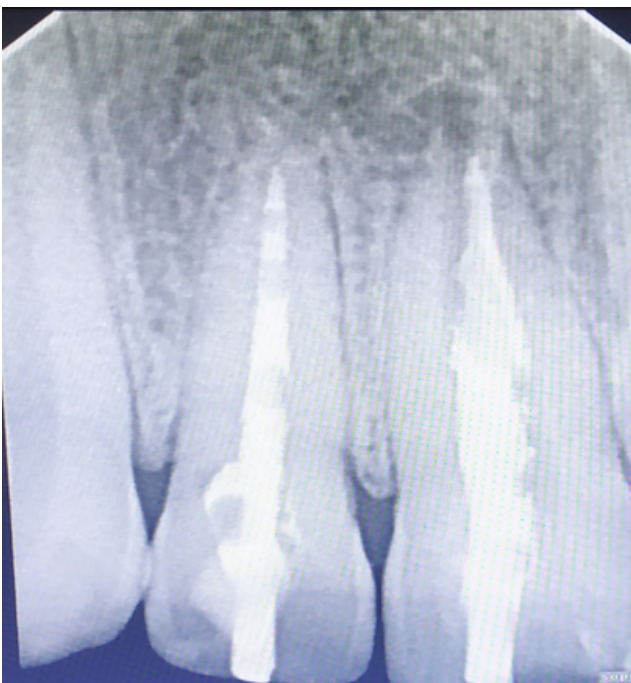

Fig. 4: Post-operative radio graph 2 yrs.

5. Source of Funding

None.

6. Conflict of Interest

None.

References

1. Bansal R, Jain A. overview on the current antibiotic containing agents used in endodontics. *Am j Med Sci.* 2014;6(8):351–8. doi:10.4103/1947-2714.139277.
2. Soares J, Santos S, Silveira F, Nunes E. Nonsurgical treatment of extensive cyst-like periapical lesion of endodontic origin. *Int Endod J.* 2006;39(7):566–75. doi:10.1111/j.1365-2591.2006.01109.x.
3. Nair PN. New perspectives on radicular cysts: do they heal? *Int Endod J.* 1998;31(3):155–60. doi:10.1046/j.1365-2591.1998.00146.x.
4. Lin LM, Ricucci D, Lin J, Rosenberg PA. Nonsurgical root canal therapy of large cyst-like inflammatory periapical lesions and inflammatory apical cysts. *J Endod.* 2009;35(5):607–15.

doi:10.1016/j.joen.2009.02.012.

5. Mitchell DA, Mitchell L, McCaul L. Oxford handbook of clinical Dentistry Third edition Laure Mitchell; 2014. p. 794.
6. Mohammadi Z. Antibiotics as intracanal medicaments: a review. *J Calif Dent Assoc.* 2009;37(2):98–108.
7. Mouton Y. The antibiotics. Role of antibiotics in prevention of infectious diseases. *Lille Med.* 1975;20:914–5.
8. Antibiotics and treatment of endodontic infections; 2006. p. 197–205.

Author biography

Ashok Kumar Mohanty, Senior Dental Surgeon

Dhirendra Kumar, Surgeon and CMO

Cite this article: Mohanty AK, Kumar D. Non-surgical management of a large periapical lesion using triple antibiotic paste: A case report. *J Oral Med, Oral Surg, Oral Pathol, Oral Radiol* 2022;8(1):49-52.