

Ameloblastic Fibroma of Anterior Mandible: An Unusual Presentation

Moni Thakur¹, Kundoor. Vinay Kumar Reddy^{2,*}, R. Mounica³,
Kotya Naik Maloth⁴, Kesidi.Sunitha⁵

¹Senior lecturer, Dept. of Oral Pathology and Microbiology,

²Professor & Head, ³Post Graduate Student, ^{4,5}Senior Lecturer, Dept. of Oral Medicine and Radiology,
Mamata Dental College and Hospital, 5-7-200, Mamata General Hospital, Khammam, Telangana – 507002

***Corresponding Author**

E-mail: reddymoni@yahoo.com

Abstract

Ameloblastic Fibroma is a rare mixed odontogenic tumor of the jaw usually occurring in first two decades of life. It predominantly occurs in children and young adults either in mandible or maxilla, but frequently found in posterior region of the mandible. We report a case of Ameloblastic Fibroma in anterior mandible of a 56 year old female patient.

Keywords: Ectomesenchyme, Hamartoma, Mixed tumor, Odontogenic tumor.

Access this article online	
Quick Response Code:	Website: www.innovativepublication.com
	DOI: 10.5958/2395-6194.2016.00004.7

Introduction

Ameloblastic fibroma (AF) is a rare odontogenic tumor, which accounts for about 0.9 to 2.4% of all odontogenic tumors, characterized by simultaneous neoplastic proliferation of mesenchymal and epithelial components, with no formation of dental hard tissues.¹ Ameloblastic fibromas (AFs) are composed of proliferating odontogenic epithelium embedded in a cellular ectomesenchymal tissue resembling dental papilla.² The tumor predominantly affects the posterior region of the mandible during the first and second decades of life, with slight male predominance.^{1,3,4} It can occur either in the mandible or maxilla but over 80% of tumours occur in the posterior mandible.^{5,6} Only four cases are reported in the maxillary anterior region.⁴ It was first described by Kruse in 1891 and later classified as a separate entity by Thoma and Goldman in 1946.^{2,7}

Case Report

A 56 year old female patient reported to the department with a chief complaint of swelling on her lower front teeth region since 5 years and pain in the same region since 20 days. The swelling was gradual in onset, initially smaller in size and increased to reach the present size, associated with pain since 20 days. Pain was sudden in onset, continuous, severe, pricking type, no aggravating and relieving factors. Patient had been

on medication for pain since 10 days. The swelling was not associated with any other symptoms.

Extraoral examination revealed a solitary diffuse swelling on the lower third of face, measuring about 5.5x 4.5 cm roughly, oval to dome shaped [Fig. 1]. On Intraoral examination a solitary swelling was present on the lower front teeth region with normal overlying mucosa measuring about 4.5 x 3.5cm, roughly oval to dome shaped, with obliteration of the vestibule from 34 to 45. On palpation the swelling was firm in consistency and tender [Fig. 2]. Aspiration was negative which indicates non cystic lesion.

Routine base line investigations were performed, which were non-contributory. Radiographic examinations were performed, intraoral periapical radiographs revealed mixed radiographic appearance [Fig. 3]. Mandibular occlusal radiograph revealed a well-defined multilocular radiographic appearance extending from mesial aspect of 36 to mesial aspect of 46, with expansion of labial and buccal cortical plates [Fig. 4]. Orthopantomograph revealed well- defined multilocular appearance with sclerotic border from 34 to 45 region [Fig. 5]. Based on history, clinical and radiographic examination a provisional diagnosis of ameloblastoma of anterior mandible was constituted with a differential diagnosis of ossifying fibroma, odontogenic myxoma, adenomatoid odontogenic tumor, and calcifying epithelial odontogenic tumor.

Complete surgical excision of the lesion was done under general anaesthesia and excised specimen was sent to histopathological examination which revealed ameloblastic like islands with connective tissue stroma. The connective tissue stroma was immature in nature with evenly spaced fibroblasts. Cystic lining with epithelial plaque was also noted [Fig. 6], suggestive of ameloblastic fibroma.

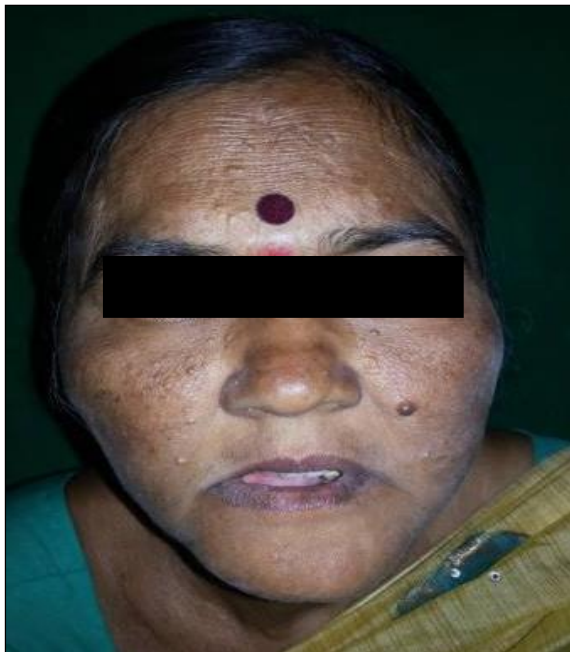

Fig. 1: profile photograph

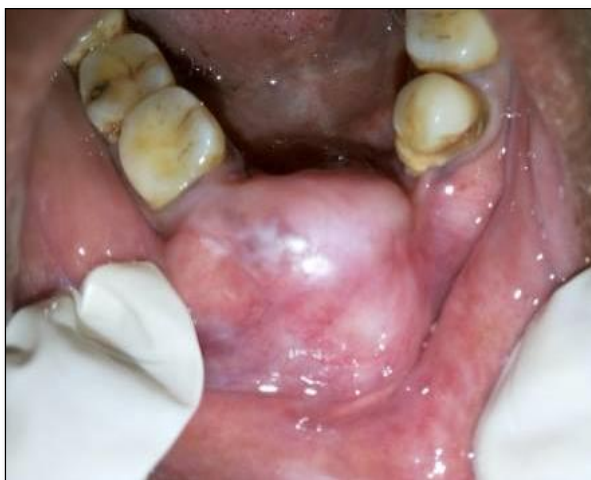

Fig. 2: Intraoral photograph reveals swelling

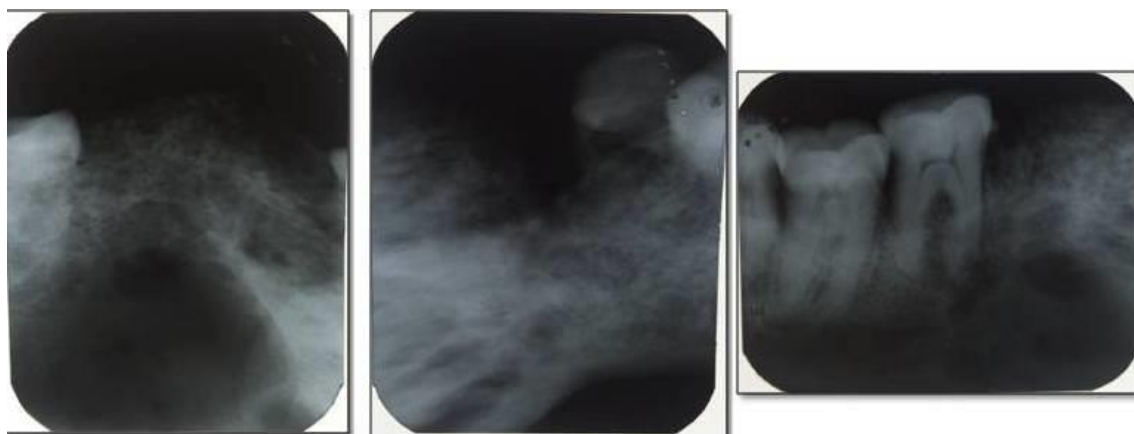


Fig. 3: Intraoral Periapical Radiograph irt 31,32,33,34,41,42,43,45,46,47 reveals mixed radiodensity

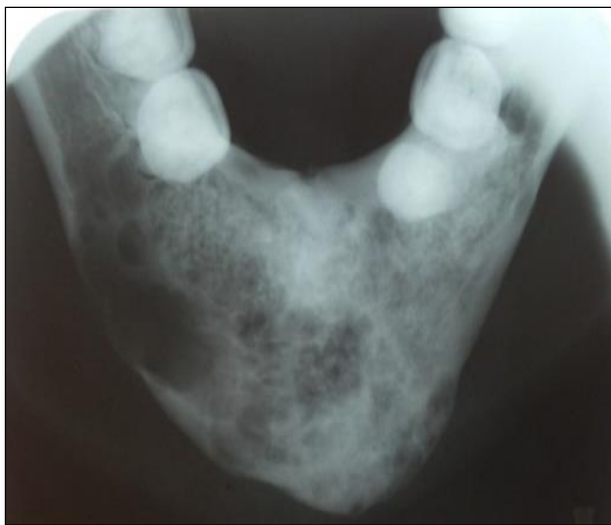


Fig. 4: Mandibular Crosssectional Occlusal Radiograph reveals expansion of cortical plates.

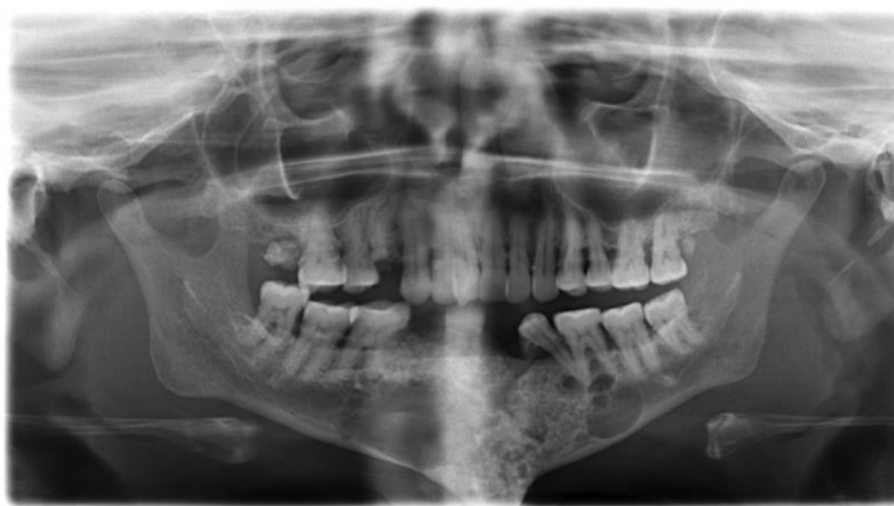

Fig. 5: Orthopantomograph revealed well- defined multilocular appearance with sclerotic border

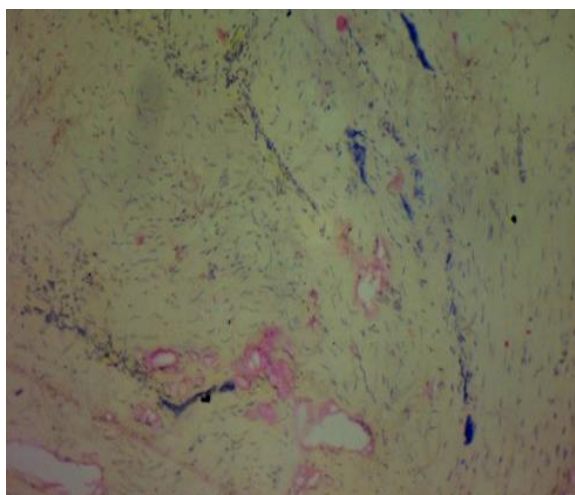


Fig. 6: Histopathology picture

Discussion

Ameloblastic fibroma is a rare benign mixed odontogenic tumor in which both epithelial and mesenchymal tissues are neoplastic.⁶ WHO defined AF as “consisting of odontogenic ectomesenchyme resembling the dental papilla and epithelial strands and nests resembling dental lamina and enamel organ. No dental hard tissues are present.” If the lesion has dentinoid tissue without or with enamel formation, it could be termed as ameloblastic-fibro-dentinoma (AFD) or ameloblastic-fibroodontoma (AFO), respectively. This group of lesions is also sometimes referred to as mixed odontogenic tumors that histologically resemble various stages of tooth formation.⁷ 75% of the cases are associated with an impacted tooth.^{1,2}

The tumors most commonly occur in the first and second decades of life with male predominance, which is in contrast to the present case that shows occurrence in an adult female patient in fifth decade of life.^{10,11} The most common location for the tumor is the posterior mandible, followed by the posterior maxilla and is associated with enclosed teeth¹⁰ but in the present case tumor was located in anterior mandible and was not associated with a impacted tooth which is an unusual presentation.

The biological behaviour of AF shares the nature between hamartoma and true neoplasm.^{3,7} Clinically, this tumour is well-encapsulated and slow-growing. The patients usually present with a hard swelling, but intraoral ulceration, pain, tenderness, or drainage may also be observed. In the present case patient presented with a swelling and pain. Bone expansion and tooth dislocation are common findings.^{5,10,11} In the present case there was expansion of labial and buccal cortical plates.

Most of the AF's (about 20%) are diagnosed just on routine dental radiography, as in this case.¹ The radiographic appearance of AF may vary from a small unilocular to an extensive multilocular lesion.⁵ and most of the lesions exhibit radiopaque borders.³ The case reported here showed multilocular appearance with a sclerotic border.

Ameloblastoma, odontogenic myxoma, and central giant cell lesion should be considered in the differential diagnosis. Particularly in this case, mixed radiographic lesions, such as ossifying fibroma, extra-follicular variant of adenomatoid odontogenic tumor, calcifying cystic odontogenic tumor and calcifying epithelial odontogenic tumor were also considered as hypotheses of diagnosis. According to Cahn and Blum, AF is a hamartomatous lesion which, over time, will mature into an ameloblastic fibroodontoma, and finally into mineralized complex odontoma.^{3,6}

Histologically, AF is a true mixed tumor, as it has both mesenchymal and epithelial neoplastic components such as strands, cords and islands of odontogenic epithelium embedded in a cell rich primitive ectomesenchyme resembling the dental

lamina with no associated calcified tissue.^{5,10} All the above features were evident in the present case.

The preferred mode of treatment for AF is conservative surgery for smaller lesions and more radical procedures being reserved for larger lesions or recurrent lesions with normal surrounding bone.⁶ The incomplete removal of the tumour results in a high recurrence rate which was reported by Trodahlet al (43.5%), Zallenet al (18.3%) after reviewing 85 cases.^{7,12} Recently, an extensive review by Buchner and Vered reported a recurrence rate of 16.3%, with malignant transformation to ameloblastic fibrosarcoma occurring in 6.4% of the reviewed cases.^{1,13} Due to these findings the complete surgical excision of the tumor as well as long-term clinical and radiographic follow up is necessary and more attention given towards recurrent cases, which has a greater risk of malignant transformation.¹ The patient reported here presented an uncommon feature of AF: a voluminous lesion occupying anterior mandible and surgical excision was done but unfortunately we couldn't follow up the case due to noncooperation of the patient.

Conclusion

AF is a rare tumor with uncommon clinical and radiographical presentation, associated with high recurrence rate and malignant transformation. However early diagnosis and prompt treatment results in good prognosis.

Conflict of Interest: None

Source of Support: Nil

References

1. de Castro JFL, Correia AVL, Santos LAM, Guerra LAP, Ramos-Perez FMM, Perez DEC. Ameloblastic fibroma: A rare case appearing as a mixed radiographic image J Clin Exp Dent. 2014; 6(5):e583-7.
2. Ealla KKR, Basavanapalli VR, Velilandla SR, Manikya S, Ragulakollu R, Danappanavar PM et al. Ameloblastic Fibroma of the Maxilla with Bilateral Presentation: Report of a Rare Case with Review of the Literature. Case Reports in Pediatrics, 2015; vol. 2015, Article ID 250713: 1-4. doi:10.1155/2015/250713
3. Pitak-Arnnop P, Chaine A, Dhanuthai K, Bertrand JC, Bertolus C. Extensive ameloblastic fibroma in an adolescent patient: A case report with a follow-up of 4 years. Eur J Dent. 2009;3:224-8.
4. de Araujo Melo L, Barros AC, de Cassia Santana SS, Cerqueira A, dos Santos JN. Ameloblastic Fibroma: A Rare Case Report with 7-Year Follow-Up. Srp Arh Celok Lek 2015; 143(3-4):190-4.
5. Gupta A, Sood R, Bansal P. Bilateral Ameloblastic Fibroma in a 6 Year Old Child: A Unique Case. J Oral Health Comm Dent 2010; 4(3):88-91.
6. Basheer S, Shameena PM, Varghese VI, Sudha S, Nair RG, Sherin N. Ameloblastic Fibroma Of Anterior Maxilla – A Case Report. J Oral Maxillofac Pathol 2010;1(1):1-5.
7. Gupta S, Tandon A, Mehrotra D, Gupta OP. Ameloblastic Fibroma: Report of 3 Cases and Literature Review. Int J Oral Maxillofac Pathol. 2011; 2(3):59-63

8. Kobayashi K, Murakami R, Fujii T, Hirano A. Malignant transformation of ameloblastic fibroma to ameloblastic fibrosarcoma: case report and review of the literature. *J Cranio maxillofac Surg.* 2005; 33:352-5.
9. De Lair D, Bejarano PA, Peleg M, El-Mofty SK. Ameloblastic carcinosarcoma of the mandible arising in ameloblastic fibroma: a case report and review of the literature. *Oral Surg Oral Med Oral Pathol Oral Radiol Endod.* 2007; 103:516-20.
10. Kannan M, Philips M, Chitturi RT. Ameloblastic Fibroma of the Mandible Mimicking A Malignant Tumor Of The Jaws. *American J Oral Med Radiol.* 2015; 2(1):21-3.
11. Vasconcelos BCE, Andrade ESS, Rocha NS, Morais HHA, Carvalho RWF. Treatment of large ameloblastic fibroma: a case report. *J Oral Sci* 2009; 51(2):293-6.
12. Bozic M, Hren NI. Ameloblastic fibroma. *Radiol Oncol* 2006; 40(1): 35-8.
13. Buchner A, Vered M. ameloblastic fibroma: a stage in the development of a hamartomatous odontoma or a true neoplasm? Critical analysis of 162 previously reported cases plus 10 new cases. *Oral Surg Oral Med Oral Pathol Oral Radiol* 2013; 116:598-606.