



Content available at: <https://www.ipinnovative.com/open-access-journals>

Journal of Oral Medicine, Oral Surgery, Oral Pathology and Oral Radiology

Journal homepage: www.joooo.org



Case Report

Use of 3D printed model as an aid in surgical removal of dentigerous cyst in the left medio-lateral aspect of mandible associated with an impacted canine – A case report

Mahendra Patait^{1,*}, Mrunmayee Durugkar¹, Ashwin Thakare², Satish Abraham³, Omkar Darade³

¹Dept. of Oral Medicine and Radiology, SMBT Dental College and Hospital, Sangamner, Maharashtra, India

²Dept. of Oral Surgery, SMBT Dental College and Hospital, Sangamner, Maharashtra, India

³Dept. of Conservative Dentistry and Endodontics, SMBT Dental College and Hospital, Sangamner, Maharashtra, India



ARTICLE INFO

Article history:

Received 31-05-2022

Accepted 08-06-2022

Available online 17-09-2022

Keywords:

Dentigerous cyst

Three-dimensional (3D) printing

Odontogenic cyst

ABSTRACT

Dentigerous cyst is the second most common developmental odontogenic cyst affecting 0.91-7.3% of population and always associated with an impacted tooth. They are commonly found associated with the lower third molars followed by the upper canines, lower premolars, and upper third molars.¹The current treatment protocol for treatment is surgical enucleation or marsupialization followed by surgical enucleation with extraction of an associated tooth.

Three-dimensional (3D) printing is an industrial revolution, in which 3D models of any object are constructed using images obtained via MRI and CT.² The procedure uses materials like plastic or metal, which are deposited layer by layer to prepare model. In the medicine, 3D printing has been growing from assistance in diagnosis to surgical applications and used widely for replacement of malfunctioning tissues and organs, customization of prosthesis, manufacturing of surgical implants and anatomical models for surgical diagnosis and planning.³

This case report highlights the effective usage of 3D printing as an aid in the surgical removal of dentigerous cyst and impacted canine in mandibular anterior region.

This is an Open Access (OA) journal, and articles are distributed under the terms of the [Creative Commons Attribution-NonCommercial-ShareAlike 4.0 License](https://creativecommons.org/licenses/by-nc-sa/4.0/), which allows others to remix, tweak, and build upon the work non-commercially, as long as appropriate credit is given and the new creations are licensed under the identical terms.

For reprints contact: reprint@ipinnovative.com

1. Case Report

A 26 years old male patient reported to the Department of Oral Medicine and Radiology with chief complaint of mobile tooth in lower front tooth region of the jaw since 15 days. On intraoral examination over-retained primary canine (73) seen (Figure 1), a provisional diagnosis of over-retained deciduous tooth was made and IOPA was taken to evaluate the presence and position of permanent canine. The IOPA revealed presence of a radiopacity apical to 31, 32 surrounded by radiolucent lesion mimicking a

dentigerous cyst (Figure 2). The same picture is seen on the mandibular occlusal radiograph (Figure 3). The panoramic radiograph was taken to locate exact position and extent of lesion and it showed a well defined radiolucency with corticated borders surrounding an impacted canine from CEJ circumferentially, extending from distal aspect of 41 to mesial aspect of 35 mediolaterally and from alveolar crest to lower border of mandible superoinferiorly. Roots of 73 and 32 showed resorption and root displacement was seen with 31 and 32 (Figure 4). A provisional diagnosis of dentigerous cyst was made and as the lesion was relatively larger we felt a need to evaluate anteroposterior dimension so made a CBCT scan. The CBCT scan showed the lesion

* Corresponding author.

E-mail address: omdrhod@gmail.com (M. Patait).

of size 29.60mm X 29.36mm X 16.61mm. The perforation of buccal and lingual cortical plates with resorption of lower border of mandible was seen (Figure 5).

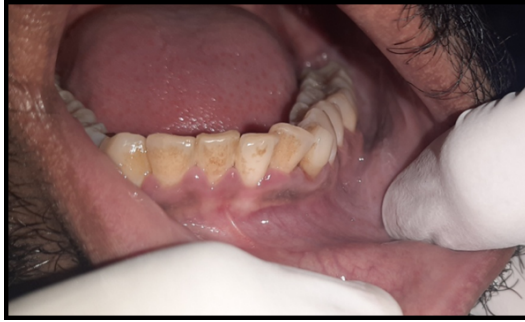

Fig. 1: Intraorally overretained 73 is present no swelling was seen

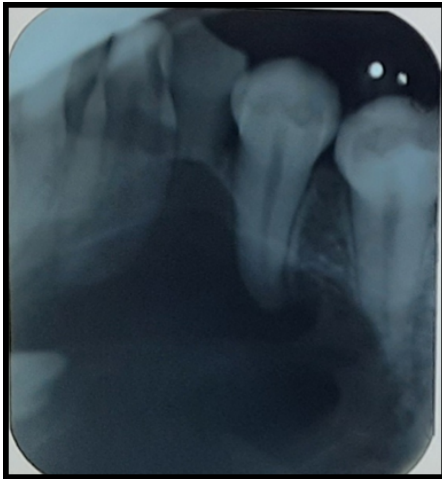


Fig. 2: IOPA

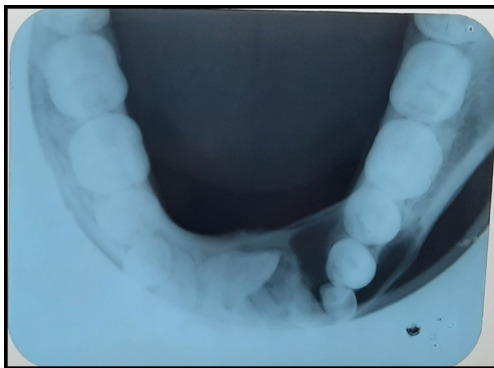


Fig. 3: Maxillary occlusalradio graph

The primary canine (73) exfoliated on its own, on the third day of patient's visit.

After radiographic evaluation the surgical enucleation with removal of an impacted canine was planned but due to

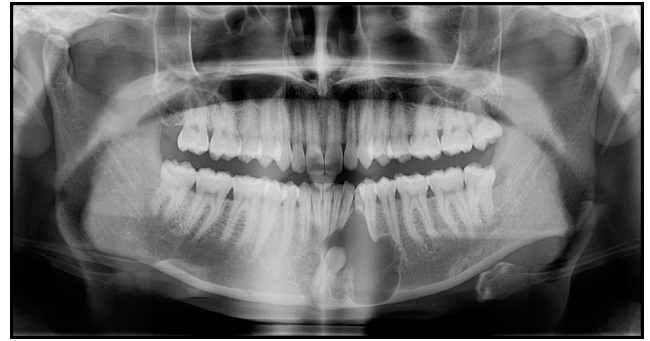


Fig. 4: OPG

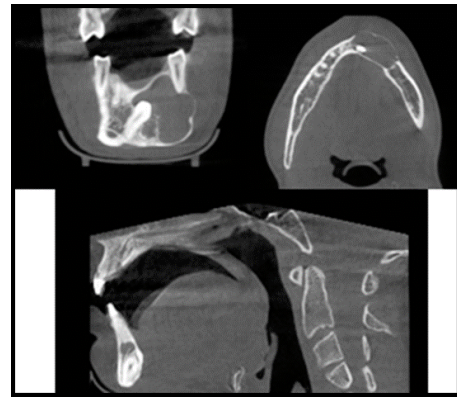


Fig. 5: Coronal, axial and sagittal view of CBCT showing impacted canine surrounded by cyst

perforations there was a risk of the jaw fracture either during surgery or postoperatively. To avoid this consequence it was decided to prepare 3D printed anatomical model which can assist in surgical planning and patient education. A 3D model of the patient's mandible was obtained from the DICOM data of the CBCT scan. The DICOM data was converted into STL file and printed using a 3D FDM printer (Figure 6).

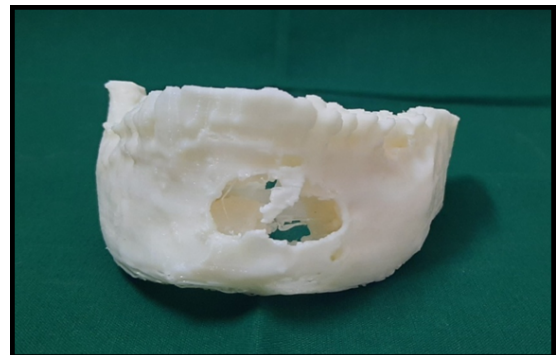


Fig. 6: 3D printed model

Before the surgical procedure was carried out an endodontic intervention was needed as the multiple teeth

were involved. Hence, the patient was referred to the Department of Conservative Dentistry and Endodontics for further evaluation of the treatment procedure. On clinical examination it was seen that there was mobility with the teeth 35, 34, 32, 31, 41 and 42 as well. Radiographic examination was done with the help of CBCT and OPG which was already taken during the initial diagnostic phase.

On complete clinical and radiographic examination, endodontic therapy was planned and the treatment plan was completely explained to the patient with the possibility of surgical intervention at the time of excision. The access cavity was prepared with the teeth 35, 34, 32, 31, 41 and 42. The root canals were instrumented to check for any exudates and at the same time copious irrigation was performed with normal saline. The biomechanical preparation was done with crown down technique using rotary instruments. The working length was constantly checked with the help of apex locator. The canals were constantly irrigated using normal saline and 2.35% sodium hypochlorite. There was no active drainage from the root canal, hence a calcium hydroxide dressing with temporary restoration was given after complete preparation of the root canals. The calcium hydroxide dressing was renewed every week for 6 weeks. The mobility decreased gradually and obturation was completed with all the teeth.

The patient was briefed about the surgical procedure, its need and risks. Informed consent was obtained from the patient. The procedure was performed under local anesthesia. A crevicular incision was made from the distal aspect of 35 till the distal aspect of 43, vertical releasing incisions were made on both the sides and a full thickness mucoperiosteal flap was raised (Figure 7). Sharp dissection was done to lift the mucoperiosteal flap atraumatically keeping a constant view on the mental nerve. A minimally invasive bony window of 1.5 cm approximately was made below 31, 32 (Figure 8). The cyst was enucleated followed by disimpaction of 33. A thorough curettage was done followed by lavage of the cystic cavity with copious normal saline irrigation (Figure 9). The excised tissue (Figure 10) was immersed in 10% formalin and sent for histopathologic examination.

Before starting surgical procedure, 10 ml of blood was derived from the medial cubital vein of the left arm of patient. It was then transferred into a test tube (without anti-coagulant) and centrifuged (REMI Model R-8c, India) at 3000 rpm for 10 minutes to obtain platelet rich fibrin. After centrifugation, the test tube showed three layers the uppermost is acellular platelet poor plasma, below that a PRF clot and red blood cells at the bottom. PRF was removed with the sterile tweezer from the test tube and placed in a post surgical defect along with absorbable sponge of gelatin (Figures 11 and 12). The wound closure was done with suture following and placement of pressure pack (Figure 13). Once the procedure was completed an IM

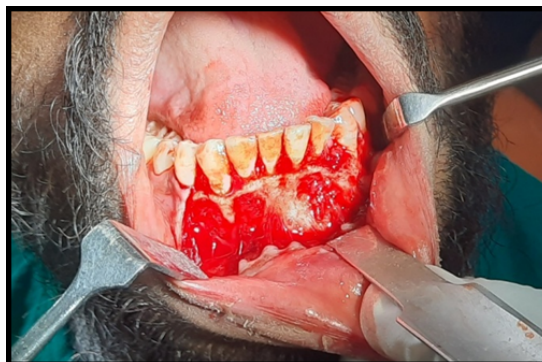

Fig. 7: Full thickness mucoperiosteal flap was raised

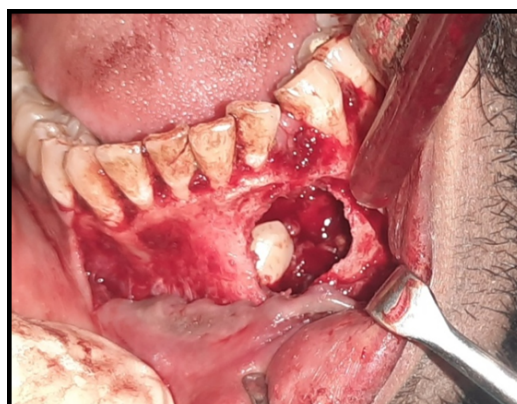

Fig. 8: Impacted canine

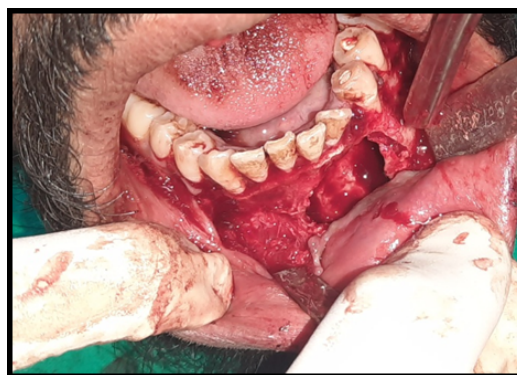

Fig. 9: Complete excision of cyst and removal of impacted canine

injection of dexamethasone and diclofenac was given.

The histopathologic examination showed cystic lumen lined by proliferative nonkeratinized stratified squamous epithelium. The connective tissue capsule was fibrocellular and collagen bundles were arranged haphazardly. Diffusely distributed moderate amount of chronic inflammatory cell infiltrate consisting of plasma cells and lymphocytes was seen. The islands of odontogenic epithelium were present along with areas of extravasation and degeneration.

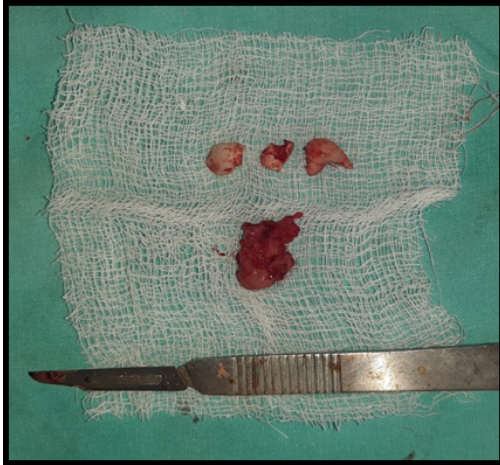

Fig. 10: Extracted tooth and excised specimen

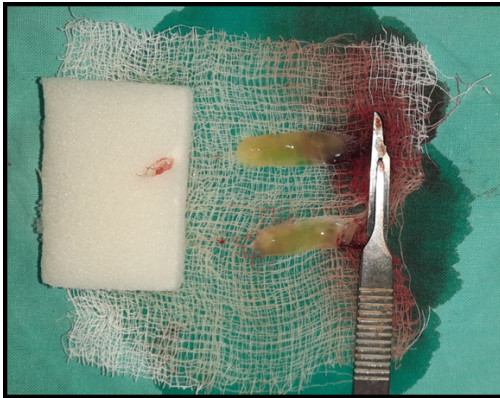


Fig. 11: PRF and gelatin sponge

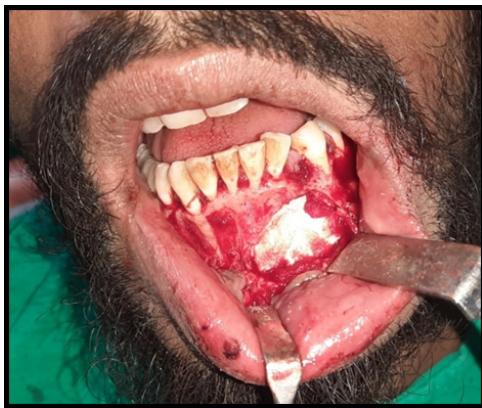

Fig. 12: Placement of gelatin sponge and PRF in the defect

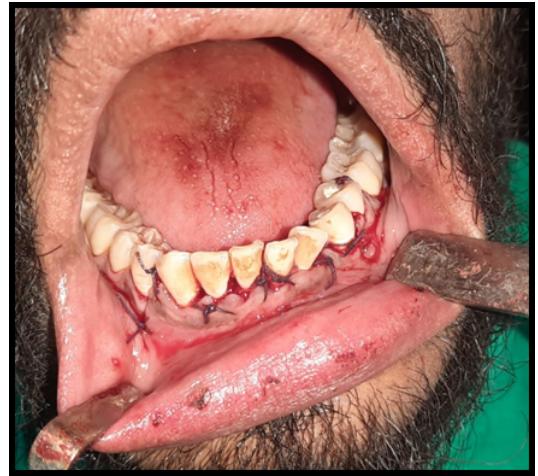

Fig. 13: Suture placement

Regular follow-ups were taken at 1 week, 2 weeks and 1 month which showed uneventful healing of the wound (Figures 14 and 15).

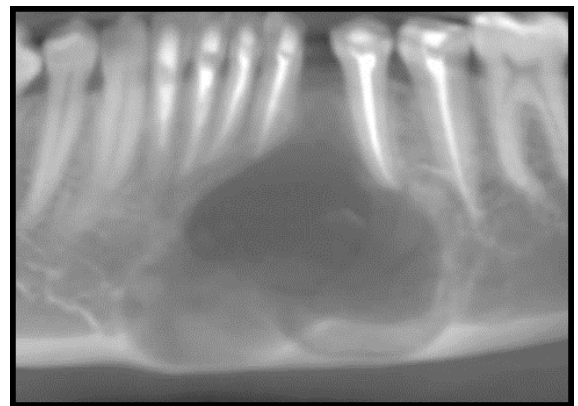


Fig. 14: Post-operative OPG

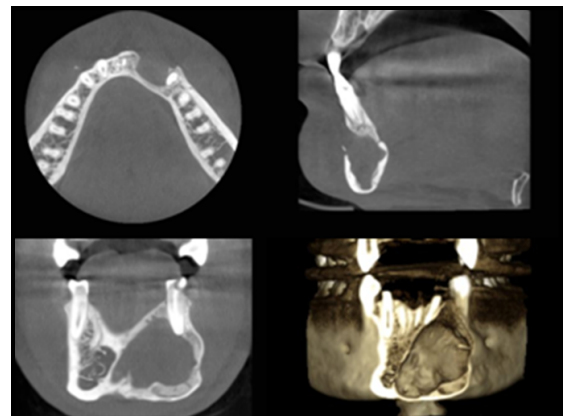


Fig. 15: Post-operative CBCT scan

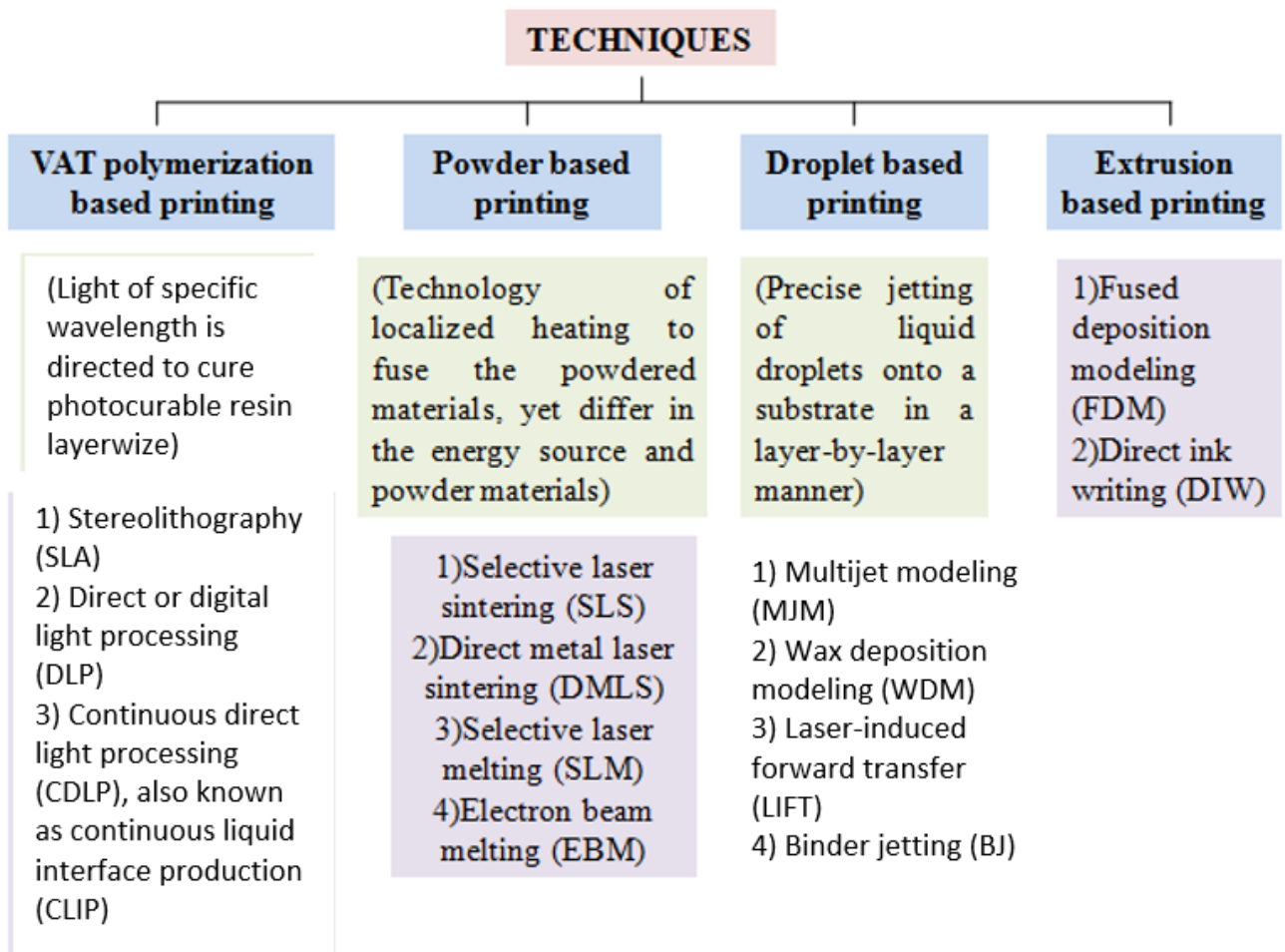


Diagram 1: Intraorally overretained 73 is present no swelling was seen

2. Discussion

The dentigerous cyst is a second most common developmental odontogenic cyst, also known as follicular cyst. The sites frequently affected by dentigerous cyst are mandibular third molar, maxillary canine, mandibular premolar and maxillary third molar. According to literature mandibular canine is affected less frequently. The exact etiology is unclear, but an infection of the primary tooth can be considered as possible cause for the formation of a dentigerous cyst with respect to the underlying permanent tooth.⁴ The accumulation of fluid is seen between reduced enamel epithelium and crown of an unerupted tooth. The pathogenesis is considered as, pressure exerted by an erupting tooth obstructs venous flow which induces the accumulation of exudates between the reduced enamel epithelium and the crown of tooth. Hence, radiographically the follicular space more than 5mm is considered as dentigerous cyst.⁵ It is usually asymptomatic unless secondarily infected. It has a great potential for growth, differentiation and degeneration. Hence, it can grow to a

huge size before getting diagnosed, causing perforation of bone and resorption or displacement of roots of adjacent teeth.

Radiographically dentigerous cyst appears as well-defined unilocular radiolucency with sclerotic borders. The internal structure is completely radiolucent with involvement of an impacted tooth. Radiographically it shows three types – central, lateral and circumferential. Resorption of roots of adjacent teeth, displacement of adjacent teeth, perforation of cortical plates and sometimes involvement of nearby nerve is also seen.

The treatment protocol is surgical enucleation with disimpaction of involved tooth. When the cyst is large marsupialization is done prior to surgical enucleation.

The three-dimensional (3D) printing technique, also commonly known as additive manufacturing or rapid prototyping has been introduced in 1980 by Charls W. Hull and considered as significant industrial revolution. Since then for three decades it is in use in various fields worldwide. Amongst them the healthcare field being the

third largest market that covers approximately 16% area in 3D printing. 3D printing enables production of customized, anatomically matched devices with high complexity which is not possible with conventional fabrication technique. It uses patient's own medical images like CT or MRI for construction of various models.^{6,7}

The 3D printing has been adopted in healthcare faculty for wide range of applications including dentistry, tissue engineering, fabrication of medical devices, anatomical models and drug formulations. The main indications concerning dentistry are dental implant placement, orthognathic surgery, mandibular reconstruction and midface reconstruction. According to their use the 3D printed models are categorized as surgical guides, anatomic models, occlusal splints, facial epithesis, PSIs (osteosynthesis plate, skeletal reconstruction plate etc).^{6,8}

The various techniques of 3D printing can be summarized in Diagram 1.⁶

3. Source of Funding

None.


4. Conflict of Interest

None.

References

- Nahajowski M, Hnitecka S, Antoszevska-Smith J, Rumin K, Dubowik M, Sarul M. Factors influencing an eruption of teeth associated with a dentigerous cyst: a systematic review and meta-analysis. *BMC Oral Health*. 2021;21(1):180.
- Martelli N, Serrano C, Brink HVD, Pineau J, Prognon P, Borget I, et al. Advantages and disadvantages of 3-dimensional printing in surgery: a systematic review. *Surgery*. 2016;159(6):1485–500.
- Ghai S, Sharma Y, Jain N, Satpathy M, Pillai AK. Use of 3-D printing technologies in craniomaxillofacial surgery: a review. *Oral Maxillofac Surg*. 2018;22(3):249–59.
- Gupta D, Rao A, Sridhar S. Evidence based treatment planning for dentigerous cysts; 2021. Available from: <https://www.guident.net/articles/pedodontics/EVIDENCE-BASED-TREATMENT-PLANNING-FOR-DENTIGEROUS-CYSTS.html>.
- Louvrier A, Marty P, Barrabé A, Euvrard E, Chatelain B, Weber E, et al. How useful is 3D printing in maxillofacial surgery?. *J Stomatol Oral Maxillofac Surg*. 2017;118(4):206–12.
- Liaw CY, Guvendiren M. Current and emerging applications of 3D printing in medicine. *Biofabrication*. 2017;9(2):024102.
- Martelli N, Serrano C, Brink HVD, Pineau J, Prognon P, Borget I, et al. Advantages and disadvantages of 3-dimensional printing in surgery: a systematic review. *Surgery*. 2016;159(6):1485–500.
- Haymenth V, Christopher PJ, Srivatsa K, Vandana S, Kumar S, Ashwan P. Bilateral Dentigerous Cyst in Impacted Mandibular Third Molars: A Case Report. *Cureus*. 2018;10(12):e3691.

Author biography

Mahendra Patait, Professor and HOD  <https://orcid.org/0000-0002-9046-9587>

Mrunmayee Durugkar, PG Student 3rd Year

Ashwin Thakare, Reader

Satish Abraham, Professor & Head

Omkar Darade, Postgraduate Student

Cite this article: Patait M, Durugkar M, Thakare A, Abraham S, Darade O. Use of 3D printed model as an aid in surgical removal of dentigerous cyst in the left medio-lateral aspect of mandible associated with an impacted canine – A case report. *J Oral Med, Oral Surg, Oral Pathol, Oral Radiol* 2022;8(3):167-172.