



Content available at: <https://www.ipinnovative.com/open-access-journals>

Journal of Oral Medicine, Oral Surgery, Oral Pathology and Oral Radiology

Journal homepage: www.joooo.org



Original Research Article

Mental foramen of mandible in South Kerala population - A digital radiographic study

Nivia Mahadoon^{1,*}, R Sivakumar¹, S. K Padmakumar¹, Asish Rajasekharan², Jeffy Binu³, Andrews Anu⁴

¹Dept. of Oral Pathology and Microbiology, Government Dental College, Thiruvananthapuram, Kerala, India

²Dept. of Medicine and Radiology, Government Dental College, Thiruvananthapuram, Kerala, India

³Dept. of Biostatistics, Azezia College of Medical Sciences and Research, Kollam, Kerala, India

⁴Dept. of Oral Pathology and Microbiology, Government Dental College, Alappuzha, Kerala, India



ARTICLE INFO

Article history:

Received 30-08-2022

Accepted 20-10-2022

Available online 02-12-2022

Keywords:

Morphology

Digital radiography

Mental foramen

ABSTRACT

Aims: To assess whether there is sexual dimorphism in the location of mental foramen from base of mandible in South Kerala population.

Materials and Methods: A two-year retrospective study was conducted in 200 subjects [100 males and 100 females] using digital radiographs. The location of mental foramen mandible was assessed from digital orthopantomogram. The vertical distance was measured from the superior border of the mental foramen to the lower border of the mandible and the inferior border of the mental foramen to the lower border of the mandible. The obtained data statistically analyzed using SPSS software version 20. Descriptive statistics was analyzed. Independent t-test was done to determine the association between gender and different parameters. The level of significance set at $p \leq 0.05$.

Results: The average value of the distance of lower border of mandible from the superior and inferior border of mental foramen is found to be significantly higher in males than females.

Conclusion: The study revealed that there is sexual dimorphism in the location of mental foramen in South Kerala population.

This is an Open Access (OA) journal, and articles are distributed under the terms of the [Creative Commons Attribution-NonCommercial-ShareAlike 4.0 License](https://creativecommons.org/licenses/by-nc-sa/4.0/), which allows others to remix, tweak, and build upon the work non-commercially, as long as appropriate credit is given and the new creations are licensed under the identical terms.

For reprints contact: reprint@ipinnovative.com

1. Introduction

Mental foramen is defined as an opening of the mental canal onto the lateral surface of mandible.¹ The mental nerve which is a branch of inferior alveolar nerve exits the mandible through the mental foramen. The most common shape of mental foramen found in Indian population is round followed by oval horizontal.² Personal identification using metric and nonmetric features is important in forensic studies.³ The position of mental foramen can guide in determining the age and sex of an individual.⁴ Identification of individuals from the features of teeth and jaw has

been used from the time of Romans. Forensic dentists and anthropologists use the morphological features of mandible in determination of sex.⁵ Among different landmarks in human skull, mental foramen is a stable landmark in mandible.⁶ The position of mental foramen can be located with the help of orthopantomogram.

The aim of the present study was to compare the vertical distance of the lower border of mandible from the superior border and inferior border of mental foramen in both males and females using orthopantomogram.

* Corresponding author.

E-mail address: nivianees@gmail.com (N. Mahadoon).

2. Materials and Methods

A quantitative observational study of two-year duration was done in Government Dental College, Alappuzha. The sampling technique used was convenient sampling technique. The digital orthopantomogram of patients visiting the outpatient department of Dental College for orthodontic corrections were selected for the study. Radiographs meeting the inclusion and exclusion criteria were included in the study.

2.1. Inclusion criteria

Orthopantomograms with clearly visible mental foramen with in the age group of 18-40 years were selected in the study group.

2.2. Exclusion criteria

Mandible having developmental anomalies, cyst, tumors, fractures, edentulous areas were not included in the study.

2.3. Data collection tools

Digital Orthopantomogram, EZ Dent I software.

2.4. Data collection procedure

A two-year digital radiographic study was conducted in 100 males and 100 females (Total 200 radiographs) with digital orthopantomogram. The upper and lower border of mental foramen was located and the vertical measurements were taken from the upper and lower border of mental foramen to the lower border of mandible. The two measurements obtained in mm were entered for both males and females in an excel sheet.

2.5. Ethics

Study presented before Institutional ethics committee of T D Medical College, Alappuzha and received ethical clearance (IEC No: EC72/ 2019 dated 18/07/2019).

2.6. Statistics

The measurements entered in excel sheet were statistically analyzed using the version 20 of SPSS software. Descriptive statistics was analyzed. Independent t test was done to find the association between measurement of mental foramen from lower border of mandible and sex. The obtained data is statistically significant if the p-value is < 0.05.

3. Results

The mean distance from the upper border of mental foramen to lower border of mandible in males is 13.60mm compared to 12.09mm in females (Figures 1 and 2). A statistically significant difference obtained in the mean distance from

the upper border of mental foramen to the lower border of mandible between males and females ($P < 0.001$) (Table 1). The mean distance from the lower border of mental foramen to lower border of mandible in males is 11.21mm compared to 10.02mm in females (Figures 1 and 2). A statistically significant difference obtained in the mean distance from the lower border of mental foramen to the lower border of mandible between males and females ($P < 0.005$) (Table 2).

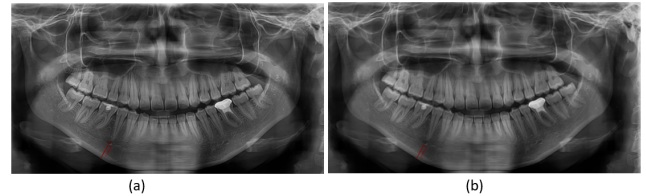


Fig. 1: (a): Showing the distance from superior border of mental foramen to base of mandible in males (b): Showing the distance from inferior border of mental foramen to base of mandible in males

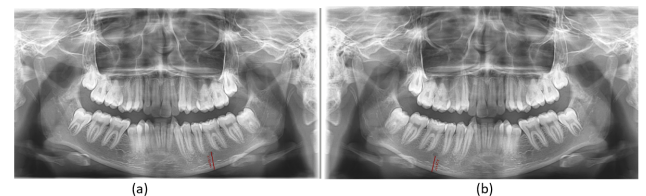

Fig. 2: (a): Showing the distance from superior border of mental foramen to base of mandible in females (b): Showing the distance from inferior border of mental foramen to base of mandible in females

4. Discussion

Sexual dimorphism in humans is used for personal identification in forensic odontology. Men requires more calories than women to maintain a healthy body weight.⁷ The greater masticatory muscle size and greater maxillary molar bite force may be responsible for the facial sexual dimorphism.⁸ Identification of skeletal remains is important in anthropology and forensic investigations. Previous studies show that there are significant differences in relation to race and sex in mandible. These differences are determined by different growth factors and environmental factors.⁹ As there is an increase in population intermixing, population specific standards are important in the present situation.¹⁰

Mandible is one of the most durable and hardest bone of facial skeleton. Mandible is subjected to great stress due to the process of mastication.¹¹ Mandible can be used with increased sensitivity and specificity for identifying both males and females.¹² Sexual dimorphism of mandible is due to the difference in growth pattern and maturation rate

Table 1: Mean distance from superior border of mental foramen to base of mandible

Gender	Mean distance from superior border of mental foramen to base of mandible	Std. Deviation	Std. Error Mean	Independent t test	P value
Male	13.60 mm	2.050	.205	6.133	P<0.001
Female	12.09 mm	1.364	.136		

Table 2: Mean distance from inferior border of mental foramen to base of mandible

Gender	Mean distance from inferior border of mental foramen to base of mandible	Std. Deviation	Std. Error Mean	Independent t test	P value
Male	11.21mm	2.076	0.208	4.700	P<0.005
Female	10.02mm	1.449	0.145		

of bone which occurs early in females compared to males. Mandible in males found to be more robust than in females. Among the skull bones, mandible is the last bone to stop growth.¹³ The size of mental foramen has a tendency to increase with age in females and has tendency to decrease with age in males and it is due to the influence of sex hormones.¹⁴

In the present study, the distance of the superior and inferior border of mental foramen from the base of mandible found to be greater in males compared to females. Rashid and Ali in 2011 studied the position of mental foramen in Iraqi population and obtained similar results.¹⁵ Chandra A et al in 2014 found similar findings in their study in North Indian population.⁶ Sheikhi M and Kheir M K in 2016 studied the position of mental foramen using CBCT in Irani population and found the distance of mental foramen from lower border of mandible to be greater in males than females.¹⁶ Malik M et al in 2016 found similar results in Haryana population.¹⁷ Elgazzar et al in 2016 in Egyptian population found sexual dimorphism in the position of mental foramen.¹⁸ Rodriguez Cardenar YA in 2018 studied the distance of lower border of mental foramen to base of mandible in Peruvian subjects and found the measurements were found to be greater in males.¹⁹ Rani A et al in 2019 studied the position of mental foramen in West Bengal population and found results similar to our study.²⁰ Renjith G et al in 2019 studied the position of mental foramen in Chinese population and confirmed the presence of sexual dimorphism with the help of discriminant function analysis.²¹ Atallah H N et al in 2019 studied the position of mental foramen using Computed Tomographic analysis in Iraqi population and found similar results.²² Subhash T S et al in 2019 got similar results in Karnataka population.

TM Wang et al in 100 Chinese cadavers measured the distance of lower border of mandible from lower border of mental foramen and found to be 14.7mm.²³ Mandible exhibits high degree of sexual dimorphism.¹¹ The mental foramen lies below the depressor labii inferioris muscle. The greater distance of the mental foramen from lower border of mandible may be due to the decrease in size of mental

foramen due to increase in muscle pull in males compared to females.

5. Conclusion

The results from this study focus on the sexual dimorphism of mental foramen in an Indian sub-population. The study can be carried with more sample size to know the specificity of the results. Location of mental foramen can be used as an adjunct tool in forensic identification of sex.

6. Source of Funding

This research did not receive any funding.

7. Conflict of Interest

Nil.

8. Acknowledgement

Authors acknowledge technical help done by radiographers Smt. Jaseem Sajil and Mr. Aravindakshan.

References

1. Phillips JL, Weller RN, Kulild JC. The mental foramen: 1. Size, orientation, and positional relationship to the mandibular second premolar. *J Endod.* 1990;16(5):221–3.
2. Singh R, Srivastav AK. Study of Position, Shape, Size and Incidence of Mental Foramen and Accessory Mental Foramen in Indian Adult Human Skulls. *Int J Morphol.* 2010;28(4):1141–6.
3. Suragimath G, Ashwinirani SR, Christopher V, Bijjargi S, Pawar R, Nayak A. Gender determination by radiographic analysis of mental foramen in the Maharashtra population of India. *J Forensic Dent Sci.* 2016;8(3):176.
4. Ghouse N, Nagaraj T, James L, Swamy N, Jagdish C, Bhavana TV. Digital analysis of linear measurements related to the mental and mandibular foramina in sex determination. *Pathol Surg.* 2016;2:5–9.
5. Sweet D. Why a dentist for identification? *Dent Clin North Am.* 2001;45(2):237–51.
6. Chandra A, Singh A, Badni M, Jaiswal R, Agnihotri A. Determination of sex by radiographic analysis of mental foramen in North Indian population. *J Forensic Dent Sci.* 2013;5(1):52–5.
7. Crane MM, Jeffery RW, Sherwood NE. Exploring Gender Differences in a Randomized Trial of Weight Loss Maintenance. *Am J Mens Health.* 2017;11(2):369–75.

8. Palinkas M, Nassar MSP, Cecilio FA, Siéssere S, Semprini M, Machado-De-Sousa JP, et al. Age and gender influence on maximal bite force and masticatory muscles thickness. *Arch Oral Biol*. 2010;55(10):797–802.
9. Green H, Curnoe D. Sexual dimorphism in southeast Asian crania: a geometric morphometric approach. *Homo*. 2009;60(6):517–34.
10. Saini V, Srivastava R, Rai RK, Shamal SN, Singh TB, Tripathi SK. An osteometric study of northern Indian populations for sexual dimorphism in craniofacial region. *J Forensic Sci*. 2011;56(3):700–5.
11. Saini V, Srivastava R, Rai RK, Shamal SN, Singh TB, Tripathi SK. Mandibular ramus: an indicator for sex in fragmentary mandible. *J Forensic Sci*. 2011;56(Suppl 1):13–6.
12. Hazari P, Hazari RS, Mishra SK, Agrawal S, Yadav M. Is there enough evidence so that mandible can be used as a tool for sex dimorphism? A systematic review. *J Forensic Dent Sci*. 2016;8(3):174.
13. Saloni, Verma P, Mahajan P, Puri A, Kaur S, Mehta S. Gender determination by morphometric analysis of mandibular ramus in sriganaganagar population: A digital panoramic study. *Indian J Dent Res*. 2020;31(3):444–8.
14. Alsolihat F, Al-Omari FA, Al-Sayyed AR, Al-Asmar AA, Khraisat A. The mental foramen: A cone beam CT study of the horizontal location, size and sexual dimorphism amongst living Jordanians. *HOMO*. 2018;69(6):335–9.
15. Rashid S, Ali J. Sex determination using linear measurements related to the mental and mandibular foramina vertical positions on digital panoramic images. *J Bagh Coll Dent*. 2018;23:59–64.
16. Sheikhi M, Kheir MK. CBCT Assessment of Mental Foramen Position Relative to Anatomical Landmarks. *Int J Dent*. 2016;2016:5821048. doi:10.1155/2016/5821048.
17. Malik M, Laller S, Saini RS, Mishra RK, Hora I, Dahiya N. Mental foramen: An Indicator for Gender Determination - A Radiographic Study. *Santosh Univ J Health Sci*. 2016;2(1):12–4.
18. Elgazzar FM, El-Sarnagawy GN, El-Gendy AER. Sexual dimorphism of the mandible in Egyptian population sample: a panoramic radiographic study. *Egypt J Forensic Sci Appl Toxicol*. 2016;16(2):127–37.
19. Rodríguez-Cárdenas YA, Casas-Campana M, Castillo AAD, Castillo A, Ruiz-Mora GA, Guerrero ME. Sexual dimorphism of mental foramen position in peruvian subjects: A cone-beam-computed tomography study. *Indian J Dent Res*. 2020;31(1):103–8.
20. Rani A, Kanjani V, Kanjani D, Annigeri RG. Morphometric assessment of mental foramen for gender prediction using panoramic radiographs in the West Bengal population – A retrospective digital study. *J Adv Clin Res Insights*. 2019;6(3):63–6.
21. Renjith G, Mary DP, Soe K, Wan MY, Beh HC, Phuah WH, et al. Sex estimation by discriminant function analysis using anatomical location of mental foramen. *Forensic Sci Int Rep*. 2019;1:100018.
22. Atallah HN, Hameed SA, Al-Fadhily ZM, Ibrahim SA. Computed Tomographic Analysis of Mental Foramen for Age and Sex Determination in Iraqi Population. *J Res Med Dent Sci*. 2019;7(5):85–8.
23. Wang TM, Shih C, Liu JC, Kuo KJ. A clinical and anatomical study of the location of the mental foramen in adult Chinese mandibles. *Acta Anat (Basel)*. 1986;126(1):29–33.

Author biography

Nivia Mahadoon, Assistant Professor

R Sivakumar, Associate Professor

S. K Padmakumar, Professor

Asish Rajasekharan, Associate Professor

Jeffy Binu, Assistant Professor

Andrews Anu, Senior Resident

Cite this article: Mahadoon N, Sivakumar R, Padmakumar SK, Rajasekharan A, Binu J, Anu A. Mental foramen of mandible in South Kerala population - A digital radiographic study. *J Oral Med, Oral Surg, Oral Pathol, Oral Radiol* 2022;8(4):189-192.