



Content available at: <https://www.ipinnovative.com/open-access-journals>

Journal of Oral Medicine, Oral Surgery, Oral Pathology and Oral Radiology

Journal homepage: [www.joooo.org](http://www.joooo.org)



## Case Report

# Giant mandibular osteoma: A case report and review of literature

Tushar Deshmukh<sup>1</sup>, Lalit Janjani<sup>1</sup>, Ashish Kamboj<sup>2,\*</sup>, Doddamani Diwakar<sup>3</sup>, Nishant Sinha<sup>2</sup>

<sup>1</sup>Army Dental Corps, India

<sup>2</sup>Government Dental Centre, Leh, UT of Ladakh, India

<sup>3</sup>Dept. of Radiodiagnosis, JJM Medical College, Davangere, Karnataka, India



## ARTICLE INFO

### Article history:

Received 05-11-2022

Accepted 16-11-2022

Available online 02-12-2022

### Keywords:

Peripheral Osteoma

Bony growth

Surgical management

## ABSTRACT

Osteomas are benign osteogenic lesions that result from the proliferation of mature bone. Three variants are known: central, peripheral, and extra skeletal. The peripheral variant is the most common and it most frequently affects the paranasal sinuses, rarely occurring in the jaws. Mostly peripheral osteomas are of small size and rarely requiring surgical treatment. Multiple osteomas occur in Gardner's syndrome however isolated lesions are non-syndromic. Neoplastic, inflammatory, developmental and traumatic theories are given as etiologic causes. Here we have described a case of 66-year-old female patient who developed a giant peripheral osteoma in mandibular body region which was managed surgically and no recurrence noticed. Radiological evaluation portrayed a different picture and histopathology confirmed the diagnosis.

This is an Open Access (OA) journal, and articles are distributed under the terms of the [Creative Commons Attribution-NonCommercial-ShareAlike 4.0 License](https://creativecommons.org/licenses/by-nc-sa/4.0/), which allows others to remix, tweak, and build upon the work non-commercially, as long as appropriate credit is given and the new creations are licensed under the identical terms.

For reprints contact: [reprint@ipinnovative.com](mailto:reprint@ipinnovative.com)

## 1. Introduction

Osteomas are benign tumors of slow growing nature consisting of mature bone either cancellous or compact in nature.<sup>1</sup> These are generally painless tumors of chronic nature which rarely cause any discomfort to patient other than aesthetic issues. Osteomas are classified and central, peripheral or extraskeletal types.<sup>2</sup> Central osteomas originate from endosteum, peripheral from periosteum and extraskeletal from muscular tissue structures.<sup>3,4</sup> Peripheral osteomas are generally found in sinuses and rarely in maxilla and mandible.<sup>5</sup> Males are affected more than females and general age group is 14 to 57.<sup>6,7</sup>

Their growth is very slow and they don't require any surgical intervention in most cases. But if size increases over a period of time, then facial disfigurement or functional issues warrant surgical intervention.<sup>8,9</sup>

Patients with multiple osteomas should be evaluated for other systemic issues to rule out Gardner's syndrome. This syndrome has genetic predisposition and hence period review to rule out new osteomas should be carried out.<sup>10</sup>

The diagnosis of peripheral osteoma is on the basis of histopathological evaluation which may be of two types. Compact osteomas which contain mature lamellar bone and no fibrous component is present. Second type trabecular osteomas contain cancellous trabecular bone surrounded by cortical bone.<sup>11</sup>

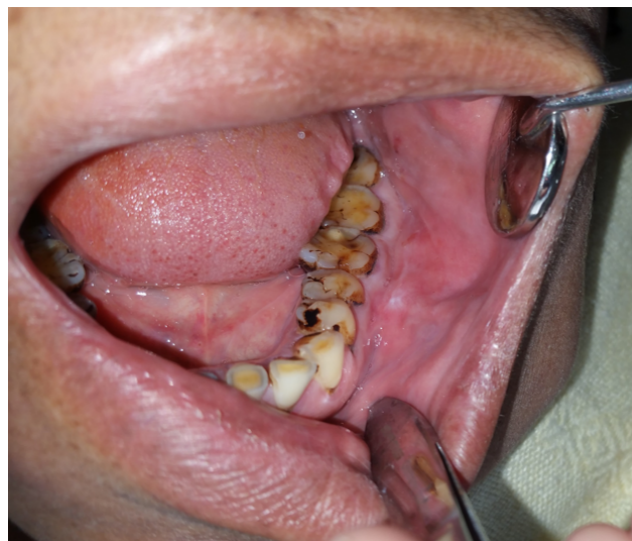## 2. Case Report

A 66 years old female patient was brought by her son with chief complaint of swelling in left lower region of face since last 12 years (Figure 1). On taking history patient told that from last 12 years the swelling is of almost same size and no increase has been noted. There was no history of any trauma or injury before 12 years and also no history

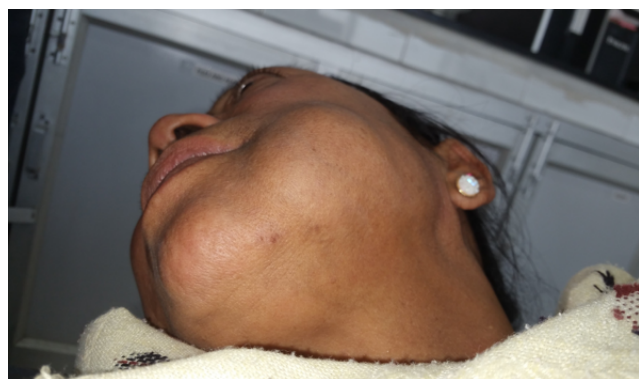\* Corresponding author.

E-mail address: [aashishkamboj@gmail.com](mailto:aashishkamboj@gmail.com) (A. Kamboj).

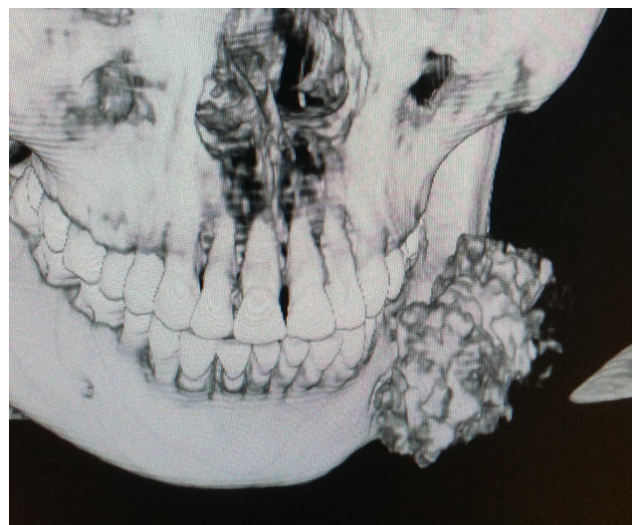of any dental treatment. There was no pain and hence patient ignored the swelling for so many days. On clinical examination no clear demarcation of swelling was seen and skin as well as mucosa over swelling was normal. On palpation the swelling was bony hard with no tenderness and anterior and posterior border of swelling was palpable. The skin over swelling was tense but not fixed and normal jaw movements were present and no restriction of any movement due to the swelling was noticed. There was no functional problem associated the swelling and masticatory efficiency was normal. Intraorally the swelling appeared to originate from buccal surface of mandible covering 34 to 37 regions (Figure 2). Patient was advised NCCT to check for the bony architecture and extension. The NCCT revealed a large pedunculated bony growth from buccal cortex of mandible in left molar region (Figures 3 and 4). The overall bony architecture was normal and no resorption of bone or roots of the teeth were noticed. The dimension calculated on NCCT images was around 4.2 cm x 2.8 cm. It was decided to do biopsy of the growth. Incision was given under LA and using small round bur a sample was obtained and sent for HPE. The report revealed normal bone and hence it was planned to remove entire bony growth under General Anaesthesia.



**Fig. 2:**



**Fig. 1:**



**Fig. 3:**

### 2.1. Surgical procedure

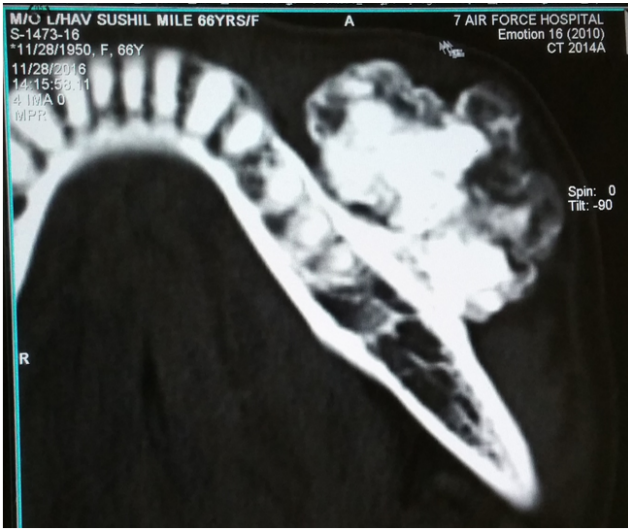
Patient was taken up under general anaesthesia after pre anaesthesia check-up. Intraoral approach was used and an incision in buccal vestibule was given. (Figure 5). The dissection was done and wide exposure was achieved. Using micromotor handpiece with surgical bone cutting burs initial marking was done and deep punch using round bur were done. By joining the bur holes the bone cutting was done from the peduncle. After removing major bulk, a fine osteotome and mallet was used to remove the peduncle and osteoplasty was done (Figure 6). Finally, using a broad Vulcanite bur buccal cortex smoothing was done. Care was taken not to damage any tooth or normal bone. Primary closure was done using silk 3-0. The excised specimen

was sent for Histopathology which revealed mature bone with normal lamella suggestive of peripheral osteoma. The sutures were removed on seventh day and no paresis of nerve was noticed. Radiological evaluation was done postop (Figures 7 and 8). Clinical follow up was done for 01 year and till date no recurrence has been reported.

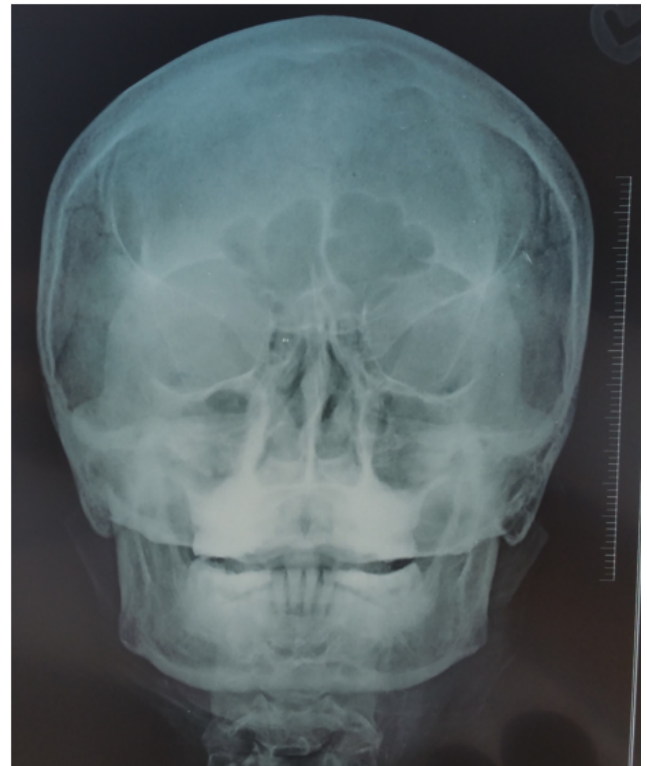### 3. Discussion

Osteoma is a benign slow growing tumour of jaw bone that affects the craniofacial region. Osteomas are benign neoplasm of mature bone which may be cancellous or compact.<sup>12</sup> Males are affected more than females with age 30-to-50-year range mentioned in literature.<sup>13</sup> Few articles mention no specific predilection for males over females.<sup>6</sup>

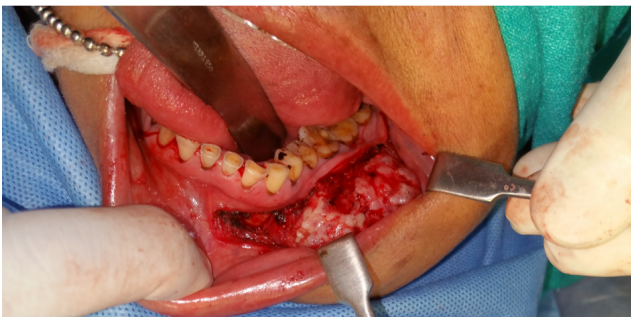



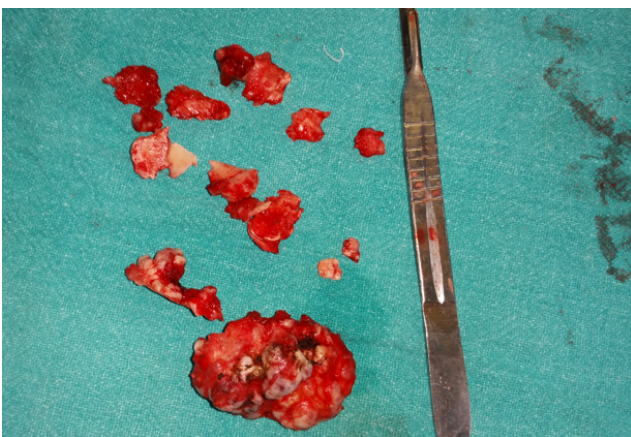**Fig. 4:**



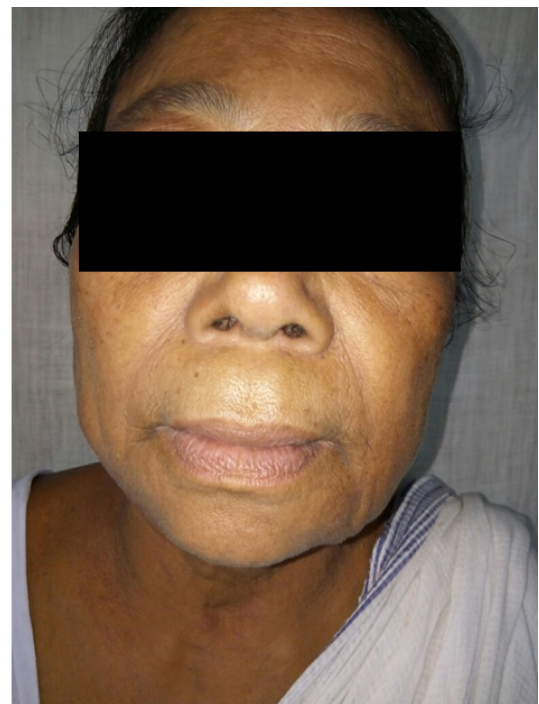**Fig. 7:**



**Fig. 5:**



**Fig. 6:**



**Fig. 8:**

Peripheral osteomas are rare and involvement of mandible is more compared to maxilla.<sup>14</sup> Peripheral osteomas have site predilection for mandibular buccal cortical plate in molar region, mental region and sometimes lingual region.

The etiology of osteomas is not clear. Few authors have proposed neoplastic theory of origin. But as the rate of growth is very slow it is not substantiated. Developmental theory<sup>15</sup> is also not convincing as most of osteomas are reported in old adults. Also, other theories like due to trauma or increased muscle activity are also there.

Osteomas are generally unilateral, isolated and pedunculated mushroom-like in appearance.<sup>6</sup> Most osteomas are asymptomatic and the patient generally notices swelling only when facial disfigurement takes place.

The histopathological picture of osteomas shows osteoid cells with normal woven bone appearance. Presence of osteoblasts and osteoclasts as well as normal haversian canals are frequently seen.<sup>16</sup> Osteomas which develop in bone are central and those which develop from periosteum are peripheral. The growth of the osteomas is exophytic mushroom like pedunculated.<sup>17</sup> Multiple osteomas are reported in Gardner's syndrome but in this case a solitary growth was present with no other abnormality clinically or radiologically. Differential diagnosis of this type of lesions is quite difficult but should be done so as to come to a final diagnosis. Osteoblastoma, peripheral ossifying fibroma and bony exostosis are some lesions which have similar features. Osteoblastomas are generally painful and growth is also aggressive.<sup>18</sup> Peripheral ossifying fibroma is generally present in anterior maxilla and its infiltration pattern is different.<sup>19</sup> Bony exostosis is generally of small size and rarely attend growth of this proportion. Osteoid osteoma is a type of osteoma but it is intracortical growth with variable amount of calcification and generally of small size. The characteristic feature of osteoid osteoma is pain which is relieved by aspirin like NSAID.<sup>20</sup>

In this case there was no history of any trauma present. The examination of masseter muscle has not shown any evidence of hypertrophy or any bone resorption near muscle insertion. The patient gave history that initially a very small swelling was present which increased to present size in few years.

Radiographically most osteomas are radiopaque with well-defined borders.<sup>21</sup> NCCT is a very useful tool to determine all the boundaries, structural changes, size calculation and to anticipate surgical difficulties.<sup>22</sup> In this case also NCCT was used which gave detailed information of the lesion. As it is very essential to differentiate the lesion from more aggressive carcinomas, one should always check the resorption associated with swelling. Root resorption is again very important parameter and it should be evaluated thoroughly. In our case no bone resorption or root resorption was observed and also pedunculated appearance with mushroom like growth was clearly visible on NCCT. Also,

the density was evaluated for this lesion and no difference in normal bone and this growth was seen.

Hasan in his work has gathered a very good data of most peripheral osteomas, their size and treatment considerations. According to him those osteomas which are greater than 3cm are giant osteomas and hence in this case we called our osteoma giant osteoma.<sup>23</sup>

Rodriguez Y, Baena R, Rizzo S, et al. explained in their study that greater proportions of the peripheral osteoma are possible and their removal via surgical modality is required to treat the asymmetry.<sup>24</sup>

The patient was evaluated for systemic problems like intestinal polyposis and epidermoid cyst. There were no supernumerary teeth present and no other osteomas were found in patients upper or lower jaw. Hence, Gardner's syndrome was ruled out in our patient.<sup>25</sup>

#### 4. Conclusion

Peripheral osteomas of the jaw bones are rare. They are slow growing, asymptomatic benign lesions generally of small size. Surgical management is generally for facial disfigurement and rarely for any functional problems. Multiple osteomas is a feature of Gardner's syndrome and so all patients should be thoroughly evaluated for same. Recurrence and malignant transformation are very rare and patient should be evaluated clinically and radiologically for same.

#### 5. Source of Funding

None.

#### 6. Conflict of Interest

None

#### 7. Informed Consent


Patient has given her consent for the publication of study.


#### References


- Fourcade A, Salmon B, Pelletier FL, Ejeil AL. Peripheral osteoma of the mandibular crest: a short case study. *J Oral Med Oral Surg.* 2018;24(1):29–32.
- Sekerci AE, Sahman H, Ertas ET, Sisman Y. An unusual peripheral osteoma of the mandibular notch: a case report with computed tomography evaluation. *Oral Radiol.* 2011;27:78–82.
- Bodner L, Bar-Ziv J, Kaffe I. CT of cystic jaw lesions. *J Comput Assist Tomogr.* 1994;18(1):22–6.
- Soni S, Bhargava A. Revisiting peripheral osteoma of the mandible with case series and review of literature. *Indian J Otolaryngol Head Neck Surg.* 2014;66(2):212–8.
- Kaplan I, Calderon S, Buchner A. Peripheral osteoma of the mandible: a study of 10 new cases and analysis of the literature. *J Oral Maxillofac Surg.* 1994;52(5):467–70.
- Sayan NB, Uçok C, Karasu HA, Günhan O. Peripheral osteoma of the oral and maxillofacial region: a study of 35 new cases. *J Oral Maxillofac Surg.* 2002;60(11):1299–301.

7. Woldenberg Y, Nash M, Bodner L. Peripheral osteoma of the maxillofacial region. *Med Oral Patol Oral Cir Bucal*. 2005;10(Suppl 2):139–42.
8. Olivares CM, Francisco PL, Claudio HM, Francisco PH. Multiple mandibular osteomas not associated with gardner syndrome: case report and literature review. *Res Rep Oral Maxillofac Surg*. 2020;4(2):38.
9. Viswanatha B. Maxillary sinus osteoma: two cases and review of the literature. *Acta Otorhinolaryngol Ital*. 2012;32(3):202–5.
10. Manjunatha BS, Das N, Sutariya R, Ahmed T. Peripheral osteoma of the body of mandible. *BMJ Case Rep*. 2013;2013. doi:bcr2013009857.
11. Kashima K, Rahman OI, Sakoda S, Shiba R. Unusual peripheral osteoma of the mandible: report of 2 cases. *J Oral Maxillofac Surg*. 2000;58(8):911–3.
12. Ozturk H, Torul D, Yuceer E, Karli R, Baris S. Peripheral osteoma of mandibular angulus: analysis of the literature and report of a new case. *Odovtos Int J Dental Sci*. 2018;20(2):61–70.
13. Figueiredo NR, Meena M, Dinkar AD, Malik S. Peripheral osteoma of the angle of mandible. *Int J Oral Health Sci*. 2014;4:33–6.
14. Singhal P, Singhal A, Ram R, Gupta R. Peripheral osteoma in a young patient: a marker for precancerous condition? *J Indian Soc Pedod Prev Dent*. 2012;30(1):74–7.
15. Bulut E, Acikgoz A, Ozan B, Gunhan O. Large peripheral osteoma of mandible. *Int J Dent*. 2010;2010:834761. doi:10.1155/2010/834761.
16. Matthies L, Rolvien T, Pakusa TJ, Knipfer C, Gosau M, Amling M, et al. Osteoid Osteoma of the Mandible - Clinical and Histological Findings. *Anticancer Res*. 2019;39(1):291–6.
17. Woldenberg Y, Nash M, Bodner L. Peripheral osteoma of the maxillofacial region. *Med Oral Patol Oral Cir Bucal*. 2005;10:139–42.
18. Rao S, Rao S, Pramod DSR. Transoral removal of peripheral osteoma at sigmoid notch of the mandible. *J Maxillofac Oral Surg*. 2015;14:255–7.
19. Johann AC, DeFreitas JB, DeAguir MC, DeAraújo NS, Mesquita RA. Peripheral osteoma of the mandible: case report and review of the literature. *J Craniomaxillofac Surg*. 2005;33(4):276–81.
20. Neville BW, Damm DD, Allen CM, Bouquot JE. Oral and maxillofacial Pathology. 2nd ed. Philadelphia: Elsevier Publishing; 2002. p. 569.
21. Mittal A, Iyer N. Large peripheral osteoma of the mandible. *Oral Radiol*. 2008;24:39–41.
22. Saati S, Nikkerdar N, Golshah A. Two huge maxillofacial osteoma cases evaluated by computed tomography. *Iran J Radiol*. 2011;8(4):253–7.
23. Hasan S. Giant Osteoma of the Mandible: Report of a Rare Case with Review of Literature. *Indian J Otolaryngol Head Neck Surg*. 2021;doi:10.1007/s12070-021-02565-1.
24. Baena RRY, Rizzo S, Fiandrino G, Lupi S, Galioto S. Mandibular traumatic peripheral osteoma: a case report. *Oral Surg Oral Med Oral Pathol Oral Radiol Endod*. 2011;112(6):44–8.
25. Koh KJ, Park HN, Kim KA. Gardner syndrome associated with multiple osteomas, intestinal polyposis, and epidermoid cysts. *Imaging Sci Dent*. 2016;46(4):267–72.

### Author biography

**Tushar Deshmukh**, Oral and Maxillofacial Surgeon  
 <https://orcid.org/0000-0001-6930-2152>

**Lalit Janjani**, Oral and Maxillofacial Surgeon  <https://orcid.org/0000-0003-2373-5803>

**Ashish Kamboj**, Orthodontist  <https://orcid.org/0000-0002-1836-6786>

**Doddamani Diwakar**, Assistant Professor

**Nishant Sinha**, Endodontist

**Cite this article:** Deshmukh T, Janjani L, Kamboj A, Diwakar D, Sinha N. Giant mandibular osteoma: A case report and review of literature. *J Oral Med, Oral Surg, Oral Pathol, Oral Radiol* 2022;8(4):221-225.