



Content available at: <https://www.ipinnovative.com/open-access-journals>

Journal of Oral Medicine, Oral Surgery, Oral Pathology and Oral Radiology

Journal homepage: www.joooo.org



Editorial

Cells too get ambiguous

Ketki Kalele^{1,*}, Raman Bonde²

¹Dept. of Oral Pathology and Microbiology, V.Y.W.S Dental College and Hospital, Maharashtra, India

²Consultant, Oral and Maxillofacial Surgery, Maharashtra, India



ARTICLE INFO

Article history:

Received 03-03-2023

Accepted 08-03-2023

Available online 10-03-2023

This is an Open Access (OA) journal, and articles are distributed under the terms of the [Creative Commons Attribution-NonCommercial-ShareAlike 4.0 License](https://creativecommons.org/licenses/by-nc-sa/4.0/), which allows others to remix, tweak, and build upon the work non-commercially, as long as appropriate credit is given and the new creations are licensed under the identical terms.

For reprints contact: reprint@ipinnovative.com

Ambiguity around the histopathology diagnosis!!!

Histopathology is considered as a gold standard for diagnosis. It gives a direct insight on exact cellular and molecular phenomenon and as we all know “cells don’t lie”...

However, if the question is asked that whether histopathology answers all the problems accurately? The answer is “may be not”...

There are some entities which carry their own spectrums, their own questions and their own controversies. This particularly, is not in best interest of the histopathologists. Giving diagnosis is just not about identifying the pathology, but also understanding the pathology to the core and to give the surgeon the basic idea about the general prediction of the behavior and thereby the prognosis of that particular pathology.

Hence, the roadmap of the disease should be clear to establish the authentic diagnosis. However, there are certain pathologies in oral pathology which does not have their roots of existence clear. Controversies and differing opinions regarding their genesis, independent existence and thereby their future prognosis...

As an oral pathology practitioner, I feel the first step towards proper management of such cases with controversial nature, is documentation...

Today’s editorial is directed towards reporting one such controversial case of Unicystic Ameloblastoma arising from the lining of dentigerous cyst (DC).

The concept of Ameloblastoma arising from the lining of dentigerous cyst has long been under discussion with multiple schools of thoughts published regarding its evolution and behavior.¹ Let us have an update regarding the same.

It has long been postulated that the epithelial lining of the cysts are having potential to transform into benign or malignant tumors and the epithelial lining of DC is not an exception to that.² Although challenged by the “horses” himself that is Shear that the occurrence of the tumor from the cystic lining is just an over exaggeration of the simple stage of tumorigenesis.³ It has been evaluated and confirmed on the molecular level too that cyst linings have the potential of tumor formation. There has been increase in the expression of proliferative markers including Ki-67, p63, CD -10, osteopontin, etc in the cystic lining which shows ameloblastomatous transformation. Other studies have also reported loss of heterozygosity (LOH) and mutation in PTCH genes in odontogenic keratocyst as well as DC. Researchers thereby have also laid down conclusions that lining of DC is made up of single lineage of monoclonal cells that possess a neoplastic genotype.^{2,4} Thereby, tumors including ameloblastomas are known to arise from the cyst lining due to disruption in regular cell cycle and imbalance between oncogenes and tumor suppressor genes leading to

* Corresponding author.

E-mail address: drketkikalele@gmail.com (K. Kalele).

hyperproliferation of the lining cells.²

The early ameloblastomatous changes as put forward by Vicker and Gorlin (VG)⁵ include-

1. Epithelial lining cells comprising of columnar cells
2. Nuclear hyperchromatism
3. Palisading and polarization of nucleus
4. Cytoplasmic vacuolization
5. Intercellular spacing
6. Subepithelial hyalinization
7. Presence of stellate reticulum

These characteristics helps the pathologists identify the ameloblastomas on their most early phases also sometimes referred to as “Unicystic Ameloblastoma” (Figure 1).

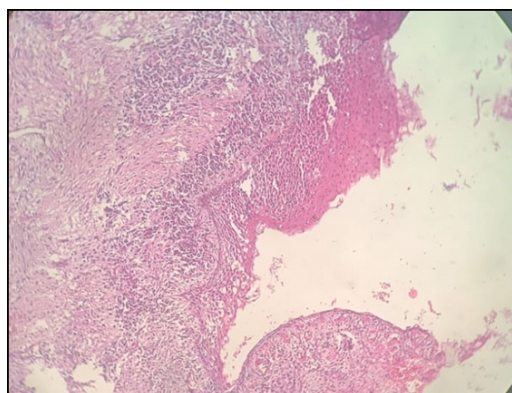


Fig. 1: 10X view of the H & E section showing Dentigerous Cyst lining proliferating into unicystic ameloblastoma with basal palisading & stellate reticulum like cells

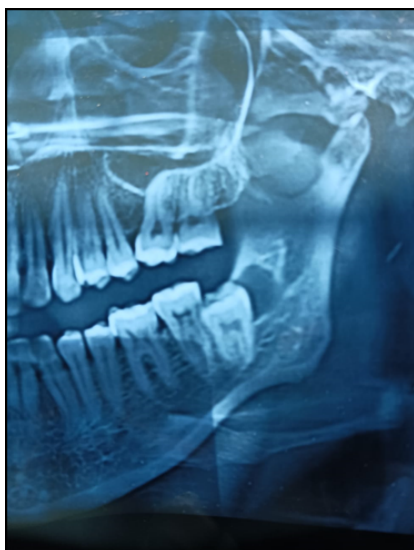

Fig. 2: Radiographic view with radiolucency around the crown of impacted 3rd molar

The case in the present editorial reports a similar case where such picture of ameloblastomatous transformation along the lining of DC was observed. The findings are similar with the case published in the year 2017 where the occurrence of the tumorous changes away from the cystic lining of DC, features of VG criteria and presence of unerupted tooth in the proximity confirms the occurrence of an ameloblastoma arising from the lining of DC.² (Figure 2)

The silver lining to the dark cloud though is amongst all this controversy of whether there is transformation of cyst lining or unicystic ameloblastoma is an independent entity, the biologic behavior is not aggressive as conventional ameloblastomas and thereby conservative treatment with carnoy’s solution and follow up is the protocol for such cases. However, knowledge regarding these ambiguous entities warrants attention especially for histopathologists for longterm evaluation of such lesions.

References

1. Holmulnd A, Anneroth G, Lunquist G, Nodenram A. Ameloblastoma originating. *J Oral Pathol Med.* 1991;20:318–21.
2. Kondamari SK, Taneeru S, Guttikonda VR, Masabattula GK. Ameloblastoma arising in the wall of dentigerous cyst: Report of a rare entity. *J Oral Maxillofac Pathol.* 2018;22:7–10.
3. Shear M, Speight P. Cysts of the oral and maxillofacial regions. New York: John Wiley & Sons; 2008.
4. Jayanandan M, Shamsudeen SM, Srinivasan SK. Desmoplastic Ameloblastoma Arising in a Dentigerous Cyst - A Case Report and Discussion. *J Clin Diagn Res.* 2016;10(8):38–40.
5. Vickers RA, Gorlin RJ. Ameloblastoma: Delineation of early histopathologic features of neoplasia. *Cancer.* 1970;26:699–710.

Author biography

Ketki Kalele, Assistant Professor  <https://orcid.org/0000-0002-3306-7266>

Raman Bonde, Consultant (Oral and Maxillofacial Surgery)

Cite this article: Kalele K, Bonde R. Cells too get ambiguous. *J Oral Med, Oral Surg, Oral Pathol, Oral Radiol* 2023;9(1):1-2.