



Content available at: <https://www.ipinnovative.com/open-access-journals>

Journal of Oral Medicine, Oral Surgery, Oral Pathology and Oral Radiology

Journal homepage: [www.joooo.org](http://www.joooo.org)



## Review Article

# Use of social networking sites and applications in identification of missing and unidentified persons: A robust forensic tool

Meghashyama Kulkarni<sup>1,\*</sup>, Sahana N S<sup>1</sup>, Rhea Verghese<sup>1</sup>, Hajira Khatoun<sup>2</sup>,  
Renuga S<sup>1</sup>, Akalya P<sup>1</sup>

<sup>1</sup>Rajiv Gandhi University of Health Sciences, Bengaluru, Karnataka, India

<sup>2</sup>Government Dental College and Research Institute, Bangalore, Karnataka, India



## ARTICLE INFO

### Article history:

Received 06-01-2023

Accepted 14-01-2023

Available online 10-03-2023

### Keywords:

Dental superimposition  
Disaster victim identification  
Forensic odontology tool  
Human identification  
Smile photograph

## ABSTRACT

Social media is an invaluable tool when seeking information or evidence in criminal cases or in finding missing persons. Social media encompasses vast amount of information such as videos, photos, texts posted by criminals, witnesses and/or victims itself.

Social media forensics helps recuperation of electronic evidence from social networking sites which often plays a crucial role in the conviction of a suspect. However, there barely exist any applications which can aid in identifying a deceased person.

For identification of deceased, forensic odontologists search for antemortem data such as dental casts, X-ray images, portrait pictures showing the anterior teeth etc., for comparison with the post-mortem data. Archetypal features such as tooth rotations, diastemas, missing teeth, supernumerary teeth, crowded teeth, recognizable removable/fixated prostheses and other attributes could be present in the missing person's profile and can be crosschecked during the autopsy of the unidentified corpse. For this reason, smile photos represent one of the most common sources of dental information, especially when no technical antemortem dental data is available. To date, there is only one forensic application for smartphones which helps in storage of antemortem smile photo of individuals. Storing the antemortem data that is easily accessible from the social media network aids as an important forensic tool especially in natural disasters or terrorist attacks where human identification process can be arduous.

This is an Open Access (OA) journal, and articles are distributed under the terms of the [Creative Commons Attribution-NonCommercial-ShareAlike 4.0 License](https://creativecommons.org/licenses/by-nc-sa/4.0/), which allows others to remix, tweak, and build upon the work non-commercially, as long as appropriate credit is given and the new creations are licensed under the identical terms.

For reprints contact: [reprint@ipinnovative.com](mailto:reprint@ipinnovative.com)

## 1. Introduction

Human identification is one of the strenuous tasks for the forensic specialists whenever a catastrophe strikes. Identification of the victims of the disaster is imperative from a judicial point of view as well as from a humanitarian point of view.<sup>1</sup> For discerning the unidentified bodies, the antemortem data is compared with the postmortem findings.<sup>2</sup>

Recognition using clothes and belongings, identification using scars, tattoos, analysis of skeletal remains, DNA

fingerprinting are some of the commonly used procedures for human identification.<sup>3</sup>

However dental identification remains one of the most dependable and widely applied parameters in identification of bodies since dental tissue is amongst the hardest structures in the human body which is resistant to a number of adverse conditions such as trauma, mutilation, immersion, incineration and putrefaction.<sup>4</sup> The tooth has the ability to withstand extremely high temperatures without perceptible loss of microstructure, it can survive for a long time even after the destruction of other skeletal and soft tissues.<sup>5</sup> Therefore, forensic odontology has always

\* Corresponding author.

E-mail address: [meghashyamakulkarni@gmail.com](mailto:meghashyamakulkarni@gmail.com) (M. Kulkarni).

played a vital role in identification of individuals in several circumstances such as mass disasters, crime investigations, ethnic studies as well as in cases of decomposed, and disfigured remains in traffic accidents, fires, and man-made disasters like terrorist attacks and bomb-blasts.<sup>6</sup>

## 2. Social Media Forensics

Social Networking websites are widely used for people to openly exchange ideas and to interact publicly in cyber space. It would seem that the introduction of Social Networking Sites (SNSs) tapped into the human desire to be able to communicate with other like-minded individuals in a convenient and reasonable way. Social media helps the users to interact and socialize, and upload photos and files, participate in various activities/events.<sup>7</sup> Globally, around 58.4% use social media, which comprises more than half of the world's population. As of 2022, 4.62 billion people around the world are using social media.<sup>8</sup> The social media mammoth attracts billions of people every day, and it is increasing exponentially.

With the understanding that a majority of the world population is using social media in some or the other form, it is implied that criminals and suspects in question are also likely to have social media accounts. The texts, pictures or any other probative evidence posted by the person of interest (POI) can be obtained, easily assessed and monitored which can help in solving many criminal cases.<sup>9</sup>

The global positioning systems (GPS) technology usage in social media has leveraged location-based searching of the POI. This process, known as geolocation, allows users to tag locations in different social media applications. In addition to identifying the location of criminal activities, investigators can use geolocation data to identify, monitor and solve missing person's cases.<sup>10</sup>

## 3. Role of Forensic Odontologist in Social Media Forensics

Forensic odontology has been playing a significant role in the identification of missing persons as well as commingled and dismembered human remains. Dental anomalies, restorations, prostheses etc. peculiar for each individual guides the forensic odontologists in identification of the victims of mass disasters.<sup>11</sup> And in order to retrieve the ante-mortem data, the experts can rely on the pictures uploaded on social media owing to the fact that smile photographs constitute a well-founded reference in dental antemortem data collection.<sup>12</sup>

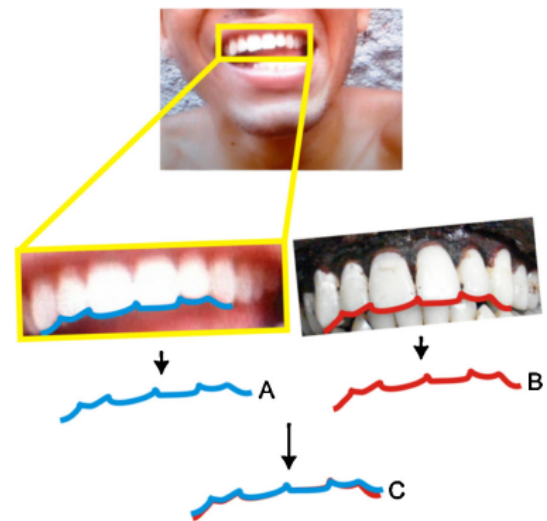
Dental characteristics in unidentified persons helps in the comparison of ante-mortem and post-mortem data and confirm the identity of an individual. The dental attributes can potentially lead to a positive identification in similar manner as in case of morphological fingerprints and DNA profiling. However, these dental characteristics may not be

of much help to the forensic investigator in absence of ante-mortem dental records.<sup>13</sup>

## 4. Use of Selfie Photographs as a Forensic Tool

In the absence of dental documentation, the smile photographs play an important role in this comparison of ante-mortem and post-mortem data.<sup>14</sup> Comparisons between the ante-mortem and post-mortem photographs can be made using two techniques which are the 'smile line' and 'superimposition.'<sup>12</sup>

Miranda et al were the first ones to use 'selfie' photographs in order to identify a carbonized body's identity.<sup>15</sup> The investigators compared the post-mortem smile line with ante-mortem smile line from the selfie images retrieved from the deceased's cellphone (Figure 1). Hence, the selfie photographs helped in identification of the completely carbonized body.

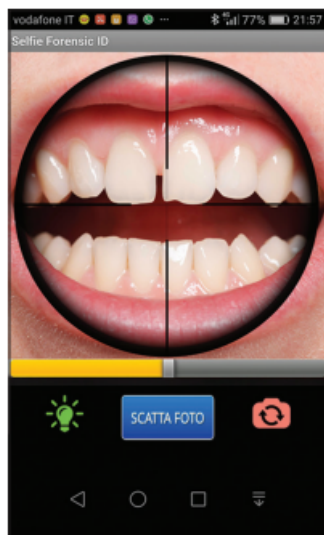

**Fig. 1:** Ante-mortem (A) and post-mortem (B) smile lines superimposed (C) for comparison

**Image courtesy:** Miranda GE, de Freitas SG, de Abreu Maia LV, Melani RF. An unusual method of forensic human identification: use of selfie photographs. *Forensic science international*. 2016 Jun 1;263:e14-7.

Analysis of smile photographs for human identification has the advantages of low cost, rapid speed, and high reliability of the results. However, there are some disadvantages as well, such as the low image quality, limited number of teeth visibility in the photograph and possibility of morphological changes in the tooth features since the antemortem photo has been taken.<sup>16</sup>

Nuzzolese et al. introduced an application for smartphones called "Selfie Forensic ID" App which employs selfie and face photographs to create a social networking archive of dental data and dental features of the anterior teeth and smiles of registered individuals.<sup>17</sup>



**Fig. 2:** A selfie picture of visible teeth within the centering grip of the selfie forensic ID App

**Image courtesy:** Nuzzolese E, Lupariello F, Di Vella G. Selfie identification app as a forensic tool for missing and unidentified persons. *Journal of forensic dental sciences*. 2018 May;10(2):75.

Individuals have to enter their names and click selfies in a smiling position which will be stored in the social media archives with a unique ID. The images taken in the application will be clear and oriented since there is a central grid available while clicking pictures. When searching for unidentified and missing persons such as in disasters or terrorist attacks, search of a name or surname in the internet may reveal photos of the face and the smile of a missing person with a profile compatible with the postmortem data. The dental characteristics and variations aid in the comparison of antemortem and postmortem match therefore confirming or excluding the identity of one or more individuals.<sup>17</sup>

The uncalled catastrophes and terrorist attacks result in the premature death of innocent people and it is paramount that the victim's bodies do not go unidentified for humanitarian reasons. Hence, the use of Applications to store the ante-mortem data is critical.

## 5. Conclusion

The dental characteristics can be an excellent source of antemortem data which aid in identification of victims of mass disasters as well as the bodies of those which are completely burnt, mutilated or putrefied, thus revolutionizing the face of forensic identification. It is suggested that dental practitioners make a note of these defects in their routine practice so that the information is available for matching dental records during forensic investigations. In forensic odontology, new methods of

identification must be sought to accommodate technological evolution, particularly in the absence of traditional methods of comparison, such as clinical record charts and radiographs.

## 6. Source of Funding

None.


## 7. Conflict of Interest

None.

## References


- de las Heras SM, Valenzuela A, Villanueva E, Marques T, Exposito N, Bohoyo JM. Methods for identification of 28 burn victims following a 1996 bus accident in Spain. *J Forensic Sci*. 1999;44(2):428–31.
- Gojanović MD, Sutlović D. Skeletal Remains from World War II Mass Grave: from Discovery to Identification. *Croat Med J*. 2007;48(4):520–7.
- Marjanović D, Durmić-Pašić A, Bakal N, Haverić S, Kalamujić B, Kovačević L, et al. DNA identification of skeletal remains from the World War II mass graves uncovered in Slovenia. *Croat Med J*. 2007;48(4):513–9.
- Manjunath BC, Chandrashekar BR, Mahesh M, Rani RV. DNA profiling and forensic dentistry-A review of the recent concepts and trends. *J Forensic Legal Med*. 2011;18(5):191–7.
- Pretty IA, Sweet D. A look at forensic dentistry-Part 1: The role of teeth in the determination of human identity. *Br Dent J*. 2001;190(7):359–66.
- Saxena S, Sharma P, Gupta N. Experimental studies of forensic odontology to aid in the identification process. *J Forensic Dent Sci*. 2010;2(2):69.
- Son J. Social Network Forensics: evidence extraction tool capabilities. New Zealand; 2012. Available from: <https://orapp.aut.ac.nz/handle/10292/4068>.
- Chaffey D. Global social media statistics research summary 2023; 2021. Available from: <https://www.smartinsights.com/social-media-marketing/social-media-strategy/new-global-social-media-research/>.
- Choo KK, Dehghantanha A. Contemporary digital forensic investigations of cloud and mobile applications. Syngress; 2016.
- Mugisha D. Role and impact of digital forensics in cyber-crime investigations. *Int J Cyber Criminol*. 2019;47(3).
- Girish KL, Rahman FS, Tippu SR. Dental DNA fingerprinting in identification of human remains. *J Forensic Dent Sci*. 2010;2(2):63–8.
- Silva RF, Pereira SD, Prado FB, Daruge E, Daruge E. Forensic odontology identification using smile photograph analysis-case reports. *J Forensic Odontostomatol*. 2008;26(1):12–7.
- Krishan K, Kanchan T, Garg AK. Dental evidence in forensic identification—An overview, methodology and present status. *Open Dent J*. 2015;9:250.
- Mckenna JJ. A qualitative and quantitative analysis of the anterior dentition visible in photographs and its application to forensic odontology. Hong Kong; 1986. Available from: <https://hub.hku.hk/handle/10722/33005>.
- Miranda GE, DeFreitas SG, Maia L, Melani RF. An unusual method of forensic human identification: use of selfie photographs. *Forensic Sci Int*. 2016;263:e14–7.
- Angelis DD, Cattaneo C, Grandi M. Dental superimposition: a pilot study for standardising the method. *Int J Legal Med*. 2007;121(6):501–6.
- Nuzzolese E, Lupariello F, Vella GD. Selfie identification app as a forensic tool for missing and unidentified persons. *J Forensic Dent Sci*. 2018;10(2):75–8.

## Author biography

**Meghashyama Kulkarni**, PG Student  <https://orcid.org/0000-0003-2686-1151>

**Sahana N S**, Professor and Head

**Rhea Verghese**, Post Graduate Student

**Hajira Khatoon**, Post Graduate Student  <https://orcid.org/0000-0002-6231-123X>

**Renuga S**, Post Graduate Student

**Akalya P**, Post Graduate Student

**Cite this article:** Kulkarni M, Sahana N S, Verghese R, Khatoon H, Renuga S, Akalya P. Use of social networking sites and applications in identification of missing and unidentified persons: A robust forensic tool. *J Oral Med, Oral Surg, Oral Pathol, Oral Radiol* 2023;9(1):18-21.