

Content available at: <https://www.ipinnovative.com/open-access-journals>

Journal of Oral Medicine, Oral Surgery, Oral Pathology and Oral Radiology

Journal homepage: [www.joooo.org](http://www.joooo.org)

## Original Research Article

## Comparing and evaluating the obturation techniques by 3 type of delivery system: An invitro method

Rohit R Koppalkar <sup>1,\*</sup>, Chandana V <sup>2</sup><sup>1</sup>Dept. of Preventive and Pediatric Dentistry, Alloli Dental Clinic, Gadag, Karnataka, India<sup>2</sup>Dept. of Oral Medicine & Radiology, Alloli Dental Clinic, Gadag, Karnataka, India

## ARTICLE INFO

## Article history:

Received 25-07-2023

Accepted 14-08-2023

Available online 08-09-2023

## Keywords:

Primary dentition

Pulpectomy

Iodontin

Lentulo spiral

Plugger

Obturation

## ABSTRACT

**Purpose:** The purpose of this study was to compare in vitro three methods of root canal obturation technique in deciduous dentition using conventional radiographic technique.**Materials and Methods:** 45 root canals of primary molars were prepared by regular manual technique and obturated using zinc oxide eugenol and calcium hydroxide-based syringe form. Obturation methods compared were lentulo spiral, plugger and Iodontin syringe form. Conventional radiographic technique was used to evaluate the Root canal length, Obturation and the presence of voids. The obtained data were analyzed using Chi-square test.**Results:** The results showed significant differences between the three groups for the radioopacity of obturation ( $P < 0.05$ ). The results showed Iodontin syringe form has fewer voids compared to lentulo spiral ZOE paste and Plugger for obturation quality. Statistically significant difference was found between Iodontin syringe form and Plugger technique ( $p = <0.05$ ).**Conclusions:** Iodontin syringe form showed the best results in the length of obturation and as well as controlling paste extrusion through the apical foramen. The lentulo spiral and plugger can also be used as an alternative method.This is an Open Access (OA) journal, and articles are distributed under the terms of the [Creative Commons Attribution-NonCommercial-ShareAlike 4.0 License](https://creativecommons.org/licenses/by-nc-sa/4.0/), which allows others to remix, tweak, and build upon the work non-commercially, as long as appropriate credit is given and the new creations are licensed under the identical terms.For reprints contact: [reprint@ipinnovative.com](mailto:reprint@ipinnovative.com)

## 1. Introduction

The pulpal treatment is important among children as it helps to preserve the primary tooth as complete functional and physiological part in the oral cavity. This helps in maintaining mastication, phonation, swallowing and to maintain the arch shape and length. The primary teeth preservation becomes essential in order to guide the permanent dentition and prevention of expected psychological effects due to loss of teeth.<sup>1</sup>

Pulpectomy of deciduous teeth is advised during the inflammation of the pulp is involved or the tooth has been diagnosed as non-vital. The treatment consists of extirpation or removal of pulp tissue, filing of the canals to

remove the organic debris and later the canals will be filled with obturation material which has antibacterial, resorbable filling material.<sup>2,3</sup>

Many products have become successful as filling materials for the procedures of pulpectomies in primary teeth.<sup>4</sup> The most common materials used during obturation of primary dentition are Zinc oxide and Eugenol (ZOE), Iodoform, Calcium hydroxide, Endoflas, Kri paste, Maisro's paste and Vitapex.<sup>5</sup> The outcome of all the available materials appears from 68.7%-100%.<sup>6-11</sup> The filling techniques have been recorded, like the pressure syringe, premixed syringe, lentulo spiral and endo plugger. An ideal filling technique should accurately fill off the canal without overfilling of the canal and with a smaller number of or no voids. Over filled canal can be manipulated or can be

\* Corresponding author.

E-mail address: [chanduv39@gmail.com](mailto:chanduv39@gmail.com) (R. R. Koppalkar).

corrected by taking off the excess filling material out of the coronal portion of the canal while doing the obturation of the canals and this can be assessed by taking post operative radiographs. Sometimes, material reinsertion is necessary, which increase the treatment time. Dandashi et al. studied similar technique for primary teeth and found no such advisable differences among them.<sup>12</sup>

Vitapex and iodoform - calcium hydroxide-based paste, which is delivered by a disposable syringe having a connected plastic needle. Recently a thin, very flexible syringe with plastic tip was introduced to the market to deliver root canal sealer Iodotin, iodoform and calcium hydroxide-based material (TechnoDent, Russian manufacturer of dental materials).

The purpose of this study was to outline a simple, effective technique to outline the obturating materials for primary tooth root canals using three delivery systems on extracted primary molars.

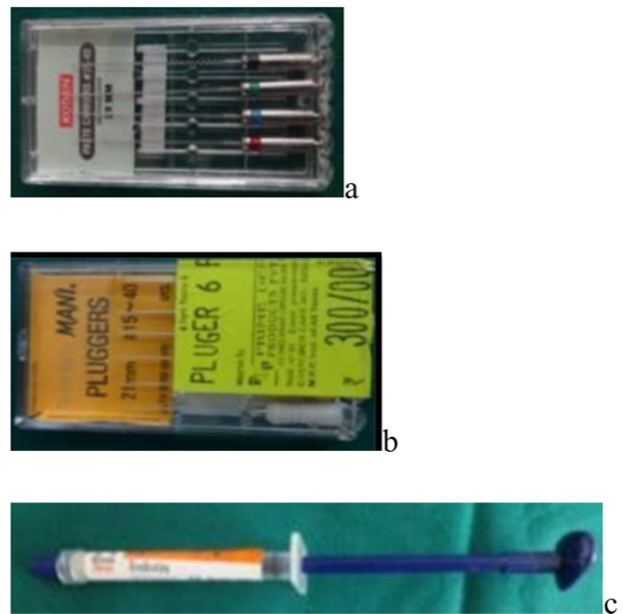## 2. Materials and Methods

45 extracted primary posterior teeth of maxillary and mandibular arch were selected. These extracted teeth were having at least two-third of the remaining root structure and no signs of advanced inflammatory root resorption. These extracted teeth were immersed in 10% formalin. All the soft tissue remnants were cleaned with an ultrasonic scaler. Carious tissue was removed with a #4 round bur. The teeth were thoroughly washed using coarse pumice (Henry Schein Inc, Indianapolis, IN) and stored in distilled water.

The samples were placed on a towel to air dry. After complete drying teeth were mounted and red modelling wax was used to cover the apex of each root. A hollow center was made in the wax to behave as a storing area for any extruded canal filling material. Each tooth was suspended vertically in a disposable dappen dish leaving two to three millimeters between the wax and bottom of the dish. Pink orthodontic acrylic (Dentsply-Caulk, Milford, DE) was poured into the dish by completely covering the roots, keeping the coronal third of the root and the coronal part by not covering it with acrylic material. After 2 days, specimens were placed on a straight area and radiographs were taken in facial-lingual direction which is perpendicular to the long axis of the teeth with the distance of 10 mm from the cone (VIX7010, INTRA ORAL X-RAY) and these radiographs marked as pre operative radiographs.

Access opening to the pulp chamber was gained by using a #330 carbide bur. Coronal pulp tissue was removed with #4 round carbide bur. The canals were hand instrumented to a size 35 file. Saline was used to clean the canals between file sizes and at the completion of instrumentation. The canals were dried with medium paper points and obturation was performed with three delivery system. (Figure 1).

The 45 sample teeth were divided into 3 groups of which 15 were in each group.



**Fig. 1:** a): Lentulo spiral, b): Pluggers, c): Iodotin syringe form

In group 1 teeth, the root canals were obturated with a ZOE based paste, mixing zinc oxide powder (company) with eugenol until a creamy consistency was obtained. A size thirty lentulo spiral was placed to a slow speed handpiece which was used as the deliver method to deliver the obturative material. A rubber stop was adjusted for every tooth based on preoperative measurement, staying one to two millimetres from the radiographic apex. The backfilling of the material was assumed as over filling of the obturative material into the canal, so the lentulo spiral was removed.

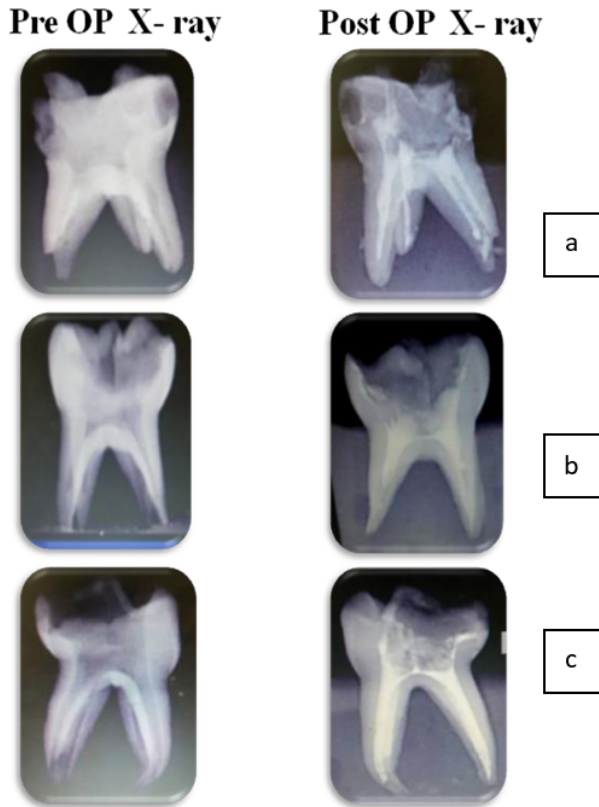
In group 2 the root canals were obturated with a ZOE based paste. A size twenty-five plugger was used as the delivery method. A rubber stop was adjusted to every canal according to the measurement which was taken during the pre-operative radiographs.

In group 3 the canals of the roots were filled with Iodotin syringe system. The plastic tip was placed into the canal opening and the material was injected, if the backfill is observed then the syringe will be withdrawn by assuming that the canal will be obturated.

Two postoperative radiographs were taken, one facial-lingual and the other from the mesial-distal aspect of each tooth using the same radiographic technique and parameters.

All the intra oral periapical radiographs were mounted on a slide frame and projected. The following were assessed a) radiopacity, b) presence of voids and c) canal obturation quality. Quality of canal obturation was based on the amount of paste in the canal was done according to the study done which was done by Memarpur M et al, 2013; greater than half of the root length, less than or equal to half of

the root length (underfilling), filling material ending at the radiographic apex or up to 2mm short of apex (optimal filling) and filling extruding from the apex (overfilling).<sup>13</sup> The radiograph was evaluated and a diagnostic consensus was reached (Figure 2). Data was statistically analysed using SPSS program for windows.



**Fig. 2:** Preoperative and postoperative radiographs of a): Lentulo spiral, b): Plugger, c): Iodotin syringe form

**3. Results**

Chi-square test indicated Iodotin syringe showed significantly less radio opacity than the other groups (p<.05). No significant differences were noted between the radio-opacity of the lentulo spiral technique and Iodotin syringe form paste and the groups regardless the delivery method used (Table 1).

A pairwise comparison was conducted in order to record for the appearance or the nature of the voids. The results indicated Iodotin syringe form has fewer voids (6.6%) compared to the lentulo spiral ZOE paste (33.3%) and Plugger technique (53.3%), Table 2. For canal obturation quality. The chi-square test indicated that Iodotin form was not statistically different than lentulo spiral technique (73.3%). When Plugger technique was compared to the lentulo spiral, no statistical difference was found.

Statistically significant difference was observed between Iodotin syringe form and Plugger technique(p=<0.05) Table 3.

**Table 1:** Distribution of the groups based on radiopacity

	Poor	Good	N
Lentulo ZOE	2(25.3)	13(86.6%)	15 (100%)
Plugger ZOE	12(80%)	3(20%)	15 (100%)
Iodotin	0(0)	15 (100%)	15 (100%)

Chi-square value- 21.38  
Value- 0.00\*

**Table 2:** Distribution of the groups based on voids

	Presence	Absence	N
Lentulo ZOE	5(33.33%)	10 (66.67%)	15 (100%)
Plugger ZOE	8 (53.3%)	7 (46.67%)	15 (100%)
Iodotin	1 (6.6%)	14 (93.3%)	15 (100%)

Chi-square value-5.62  
p value- 0.06

**Table 3:** Distribution of the groups based on obturation quality

		Frequency	Percent
Lentulo ZOE	<1/2	4	26.7
	>1/2< flush	11	73.3
	Total	15	100.0
Plugger ZOE	<1/2	11	73.3
	>1/2< flush	4	26.7
	Total	15	100.0
Iodotin	<1/2	2	13.3
	>1/2< flush	11	73.3
	flush	2	13.3
	Total	15	100.0

**Table 4:** Comparison of the groups using anova (Obturation quality)

	F	Sig.
ANOVA	8.797	.001*

**Table 5:** Post-hoc bonferroni

Group	Groups	Mean Difference	p value
Lentulo ZOE	Plugger ZOE	.467*	.035*
	Iodotin	-.267	.418
Plugger ZOE	Iodotin	-.733*	.000*

\*Significant

#### 4. Discussion

Voids presence was observed constantly in this study. The detailed observation was due to two directions in which radiographs were taken. The least amount of voids noted in the Iodontin syringe compared to all the techniques. In a report by Dandashi et al.<sup>12</sup> voids were also more commonly observed, with the pressure syringe there were very less voids, but also said as the most complex and time-consuming technique. No changes were found between Iodontin syringe and mixed ZOE with lentulo spiral technique for radiodensity. Plugger technique showed poor contrast, but a presence could be identified radiographically by disappearance of the lumen of the canal when comparison of the pre and post fill radiographs was made (Figure 2). When the reports of clinical investigations were analyzed about the obturation quality, regardless the material used, high success rates were obtained with flush and underfilled fillings.<sup>8–10</sup> The success rate showed downward curve significantly when overfilling occurred, despite the materials were used.<sup>8–10</sup> Coll and Sadrian<sup>14</sup> stated that the important radiographic diagnostic criteria is the amount of preoperative root resorption which helps in determining whether a pulpectomy will likely succeed. Holan and Fuks<sup>9</sup> reported that the success rate of the treatment is directly proportional to the pathological condition of the tooth before any kind of treatment. Lentulo spiral is a widely accepted technique for endodontic deliver of root canal sealers.<sup>15</sup> The skills of the operator need to be developed and practice should be done to obtain good results. Sometimes even the experienced operators reinsert material to assure good filling quality, consequently taking more treatment time.<sup>9</sup> The pre-mixed Iodontin syringe delivered by a plastic tip used in our study resulted in 13.3% of the short fillings and 13.3% of the flush fillings, 73.3% more than half and less than flush filling.

#### 5. Conclusion

In conclusion, this study showed that the Iodontin syringe is better in avoiding the voids, having adequate radiopacity nature and degree of filling of the canals in obturation process when compared with the Lentulo and Plugger techniques.

#### 6. Source of Funding

None.


#### 7. Conflict of Interest


None.

#### References

1. Hiremath MC, Srivastava P. Comparative evaluation of endodontic pressure syringe, insulin syringe, jiffy tube, and local anesthetic syringe in obturation of primary teeth: An in vitro study. *J Nat Sc Biol Med.* 2016;7(2):130–5.
2. Thomas A, Satish C, Shaleen C, Pandey RK. Elimination of infection in pulpectomized deciduous teeth: A short-term study using iodoform paste. *J Endod.* 1994;20(5):233–5.
3. Mahajan N, Bansal A. Various Obturation methods used in deciduous teeth. *Int J Med and Dent Sci.* 2015;4(1):708–13.
4. Guelmann M, Mceachern M, Turner C. Pulpectomies in primary incisors using three delivery systems: an in vitro study. *J Clin Pediatr Dent.* 2004;28(4):323–6.
5. Nurko C, Ranly DM, Garcia-Godoy F, Lakshmyya KN. Resorption of a calcium hydroxide/iodoform paste (Vitapex®) in root canal therapy for primary teeth: a case report. *Pediatr Dent.* 2000;22(6):517–20.
6. Rifkin AJ. Techniques and materials used in endodontics for primary teeth. *J Dent Assoc S Afr.* 1982;37(6):379–81.
7. Payne RG, Kenny DJ, Johnston DH, Judd PL. Two-year outcome study of zinc-oxide eugenol root canal treatment for vital primary teeth. *J Can Dent Assoc.* 1993;59(6):528–30.
8. Sadrian R, Coll JA. A long-term follow-up on the retention rate of zinc oxide eugenol filler after primary tooth pulpectomy. *Pediatr Dent.* 1993;15(4):249–53.
9. Holan G, Fuks A. A comparison of pulpectomies using ZOE and KRI paste in primary molars: a retrospective study. *Pediatr Dent.* 1993;15(6):403–7.
10. Fuks A, Eidelman E, Pauker N. Root fillings with Endoflas in primary teeth: a retrospective study. *J Clin Pediatr Dent.* 2002;27(1):41–5.
11. Mass E, Zilberman UL. Endodontic treatment of infected primary teeth, using Maisto's paste. *ASDC J Dent Child.* 1989;56(2):117–20.
12. Dandashi MB, Nazif MM, Zullo T, Elliott MA, Schneider LG, Czonstkowsky M. An in vitro comparison of three endodontic techniques for primary incisors. *Pediatr Dent.* 1993;15(4):254–6.
13. Memarpour M, Shahidi S, Meshki R. Comparison of different obturation techniques for primary molars by digital radiography. *Pediatr Dent.* 2013;35(3):236–40.
14. Coll JA, Sadrian R. Predicting pulpectomy success and its relationship to exfoliation and succedaneous dentition. *Pediatr Dent.* 1996;18(1):57–63.
15. Kahn FH, Rosenberg PA, Schertzer L, Korthals G, Nguyen PN. An in-vitro evaluation of sealer placement methods. *Int Endod J.* 1997;30(3):181–6.

#### Author biography

**Rohit R Koppalkar**, Consultant Pedodontist  <https://orcid.org/0000-0002-0289-5237>

**Chandana V**, Consultant Oral Radiologist  <https://orcid.org/0000-0001-8624-0029>

**Cite this article:** Koppalkar RR, Chandana V. Comparing and evaluating the obturation techniques by 3 type of delivery system: An invitro method. *J Oral Med, Oral Surg, Oral Pathol, Oral Radiol* 2023;9(3):134-137.