

Content available at: <https://www.ipinnovative.com/open-access-journals>

Journal of Oral Medicine, Oral Surgery, Oral Pathology and Oral Radiology

Journal homepage: [www.joooo.org](http://www.joooo.org)

## Original Research Article

## Mucin1 utterance in oral squamous cell carcinoma: A cancer maker and target for nanotheranostics

Kootiswaran S<sup>1,\*</sup>, P D Balamurali<sup>1</sup>, V Ramesh<sup>1</sup>, Karthikshree V Prashad<sup>1</sup>, D Mounika<sup>1</sup>, Dhanalakshmi<sup>1</sup><sup>1</sup>Dept. of Oral and Maxillofacial Pathology and Oral Microbiology, Mahatma Gandhi Postgraduate Institute of Dental Sciences, Puducherry, India

## ARTICLE INFO

## Article history:

Received 09-08-2023

Accepted 26-08-2023

Available online 08-09-2023

## Keywords:

Immunohistochemistry

MUC1

Mucins

Oral squamous cell carcinoma

Transmembrane protein

## ABSTRACT

**Background:** Mucins are cell bound high molecular weight glycoproteins which are secreted by epithelial cells. Total 21 mucin variants are identified till date. Mucin1 (MUC1) is a transmembrane glycoprotein, which when reacts with beta-catenin, can able to enter the nucleus to activate T-cell factor/leukocyte enhancing factor 1 transcription factors and gene expression, after which it may inhibit cell-cell and cell-stroma interactions and function as a signal transducer, leading to tumor progression.

**Objective:** To compare and correlate the expression and positive intensity of MUC1 in oral squamous cell carcinoma, oral epithelial dysplasia and normal oral mucosa using Immunohistochemistry.

**Materials and Methods:** This study included a total of 45 cases in which the study groups are oral squamous cell carcinoma (n=15), oral epithelial dysplasia (n=15) and control of normal oral mucosa (n=15), which are analysed for the expression of anti MUC1 rabbit monoclonal antibody using immunohistochemical technique.

**Results:** The mucin1 positive cells in the study groups were as follows, 53.3% cases in OSCC, 13.3% cases in OED and none showed positivity in normal oral mucosa. The results obtained were statistically analysed using Kruskal-Wallis test and there was a statistically significant difference in score between the different tissue groups, Kruskal – Wallis H score = 13.034, p = 0.001.

**Conclusion:** There is progressive increase in the MUC1 expression from oral epithelial dysplasia to OSCC. This utterance might be due to suppression of inhibitory proteins for MUC1 immunorexpression in mature atypical squamous cells as well as proposed to act both as an anti-adhesive and adhesive molecule.

This is an Open Access (OA) journal, and articles are distributed under the terms of the [Creative Commons Attribution-NonCommercial-ShareAlike 4.0 License](https://creativecommons.org/licenses/by-nc-sa/4.0/), which allows others to remix, tweak, and build upon the work non-commercially, as long as appropriate credit is given and the new creations are licensed under the identical terms.

For reprints contact: [reprint@ipinnovative.com](mailto:reprint@ipinnovative.com)

## 1. Introduction

Tumour markers are well known biochemical substances present scantily in body tissues and fluids which may get elevated during malignancy. Therefore, we do a quantitative analysis of biomarkers to make use of them in staging, to assess prognosis and in confirmation of diagnosis, defining the alterations in normal and abnormal cells in lesion transformation.<sup>1</sup>

Oral Squamous Cell Carcinoma (OSCC) reports for around 95% of all oral malignant neoplasms and around 38% of entire malignant head and neck tumours and needs more advanced protocols to contain this major global health problem. Most of the OSCC has undergone a period of premalignant process in which the affected epithelium exhibits histologic evidence of epithelial dysplasia.<sup>2</sup> In epithelial dysplasia, the abnormal cells, sometimes are protected by the immune system of the host within the stratified squamous epithelium. But, sometimes tumour cell invasion through the basement membrane barrier that

\* Corresponding author.

E-mail address: [kootiswaran@gmail.com](mailto:kootiswaran@gmail.com) (Kootiswaran S).

indicates the point of transition from premalignant lesion to OSCC.<sup>2,3</sup> Despite recent advances in treatment modalities, the 5-year survival rate has not improved.<sup>2</sup> Thus, invasion and metastasis is a major problem in successful cancer treatment.<sup>3</sup>

Mucins are cell bound high molecular weight glycoproteins that play a major role in cell differentiation, growth and signalling. The mucins provide more potential for cell proliferation, invasion, survival, metastatic growth and defensive against innate immunity. Mucin gene expressed more in the digestive, respiratory and reproductive systems. An aberrant utterance of Mucin1 (MUC1) in various human cancers has highlighted its role in the pathogenesis of cancer. It has been reported in the literature that mucins protect cancer cells from abnormal growth conditions and to manage the molecular microenvironment in the process of invasion and metastasis.<sup>2</sup>

The MUC – 1 gene makes production of MUC – 1 mucin which facilitates tumour development and secondary metastasis. The cancer cells can express various forms or amounts of mucin due to deregulation of core proteins and the enzymes during the transformation of tumour cells. Crucial function of MUC – 1 in transcriptional regulation of genes are associated with tumour proliferation, invasion, metastasis, angiogenesis, apoptosis and immune regulation. MUC – 1 directly controls the tumour cell survival and growth by more glucose uptake and metabolism by cancer cells.<sup>3</sup> With this brief note the present study has been performed, to study the immunohistochemical utterance of MUC1 in oral squamous cell carcinoma, oral epithelial dysplasia and normal oral mucosa.

## 2. Materials and Methods

The study was conducted on 10% formalin-fixed tissues, ranging from newly confirmed cases to archival retrieved paraffin embedded tissue blocks from our department of less than two years old. A total of 45 cases categorized into three study groups with 15 cases each. Group 1- Oral squamous cell carcinoma, Group 2- Oral epithelial dysplasia and Group 3- Normal oral mucosa.

### 2.1. Inclusion criteria

Clinically normal tissue excised for therapeutic purposes such as crown lengthening, frenectomy, adjoining mucosa of impacted tooth and reported cases of oral epithelial dysplasia and oral squamous cell carcinoma.

### 2.2. Procedure

Serial sections of 3  $\mu$ m thickness were taken from each block/specimen on two slides, the positively charged slide (PathnSitu) and albumin coated slide, for Immunohistochemical and Hematoxylin & Eosin

staining respectively. The slides were stained with MUC-1 rabbit monoclonal antibody using immunohistochemical technique. H&E staining was done for the other slide for confirmation of diagnosis of the lesions and to confirm the presence of satisfactory tissue. The sections were deparaffinized in an incubator for 40 min and cleared in 3 changes of xylene. Tris wash buffer was prepared freshly at a pH of 7.4 to 7.6 (pH was altered using 1N HCl and 4N NaOH solutions). Antigen retrieval of charged slide sections immersed in freshly prepared Tris-EDTA buffer solution at pH of 8.8 to 9.2 at a gradual rise in temperature (140°C) and was done using a pressure cooker method. Bench cooling was done for 40 min. Then, slides were rinsed in the wash buffer and endogenous peroxidases were blocked (PathnSitu) at room temperature for 15 min. Then sections were incubated with primary anti-MUC1 mucin monoclonal antibody (PathnSitu) for 1h. Then a drop of target binder is placed and incubated for 12 min preceded by incubation with a secondary antibody (PathnSitu) for 12 min. Substrate chromogen solution was prepared freshly by taking 1ml of substrate in eppendorf tube and to this added one drop of DAB chromogen (PathnSitu), from this mixture a drop is put over the section and incubated for 5mins. Finally, the sections were counterstained with Mayer's hematoxylin for 15 sec and mounted. Colon carcinoma tissue was used as positive control.

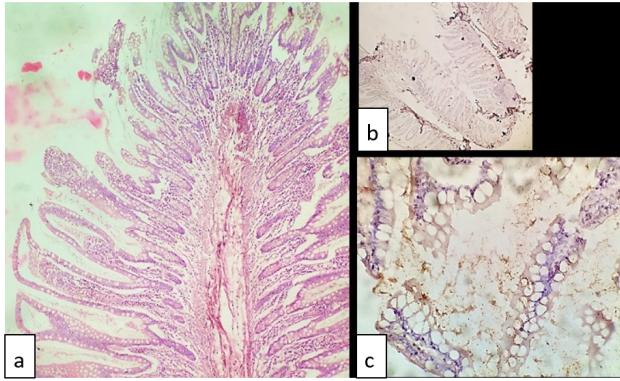
### 2.3. Interpretation of staining

Stained sections mounted on glass slides were examined under light microscope for the presence of MUC1 positive cells in a high power field. The positivity of MUC1 utterance was further compared based on the intensity of positive cells. H & E stained sections were used for comparison. Percentage of positive cells for MUC1 in each case was semi-quantitatively scored as, Score-0: Negative or absence of immunoreactivity; Score-1: Mild, < 25% of cells stained; Score-2: Moderate, 25% to 50% of cells stained; Score-3: Strong, > 50% of cells stained.

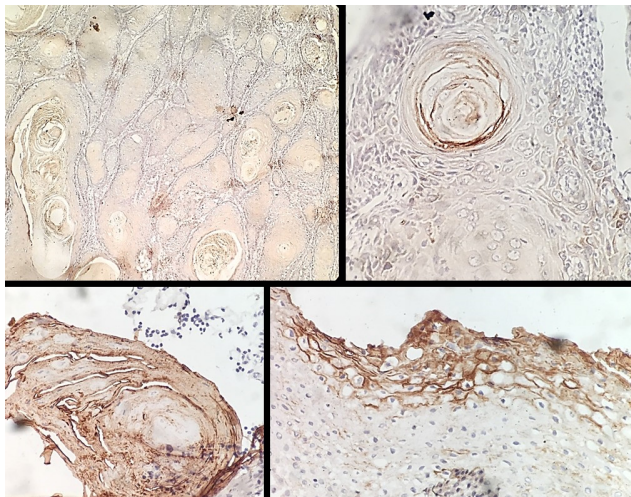
## 3. Results

The following results were drawn from the present study, out of 15 cases of OSCC, 8 (53.3%) cases exhibited positive for MUC1 in the squamous cell membrane and keratin pearl (Figures 1 and 2). Out of 15 cases of oral epithelial dysplasia showed 2 (13.3%) cases positive for MUC1 immunoreactivity in basal, suprabasal & spinous area and focal areas of epithelial cell membrane (Figure 3). None of the normal oral mucosa showed mucin1 positivity.

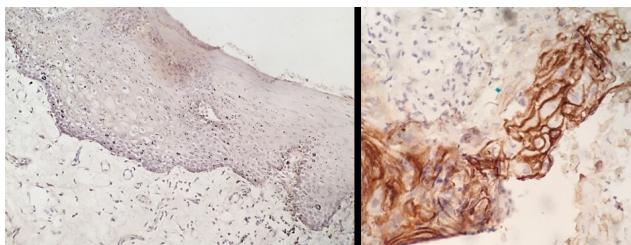
There is significant variation in the Mucin1 expression among normal oral mucosa, oral epithelial dysplasia and oral squamous cell carcinoma (Figure 4). There is a clear increase in mucin1 expression from oral epithelial dysplasia cases to OSCC cases and absent in normal oral mucosa



**Fig. 1:** Mucin1 positive control of colon carcinoma tissue, a): 10x view H&E image showing crypts and clear mucinous cells. b): 4x view IHC stained colon carcinoma, c): 40x view IHC stained shows membrane positivity for mucin1 antibody.

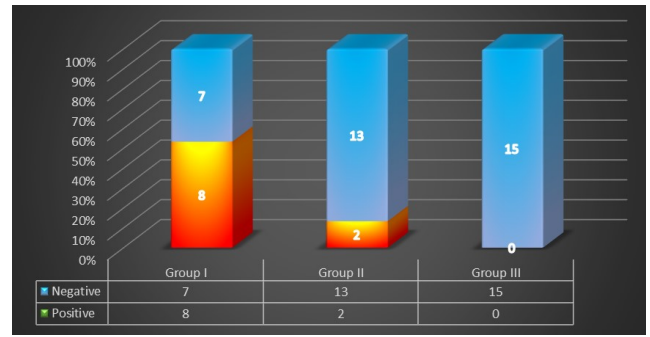


**Fig. 2:** IHC stained image of OSCC shows MUC1 positive immunoreactivity in the keratin pearl and squamous cell membrane. (IHC stain x10 & x40 views)



**Fig. 3:** IHC stained image of oral epithelial dysplasia shows MUC1 positive immunoreactivity in basal, suprabasal and focal areas of epithelial cell membrane. (IHC stain x10 & x40 views)

(Chi-square value = 10.288, p=0.001).



**Fig. 4:** Number of study samples expressing MUC1 positivity among the three groups

The scoring of intensity of staining among different groups were mentioned in Table 1. It shows that Group 3 can be used as a negative control for MUC1 utterance using IHC. Kruskal - Wallis H test exhibited statistically significant difference in intensity between the different study groups (Kruskal – Wallis H score = 13.034, p=0.001).

#### 4. Discussion

Oral Squamous Cell Carcinoma is well-known highly prevalent disease in all countries which is caused by various risk factors and etiopathogenesis, having higher incidence of mortality and morbidity rate.<sup>4</sup> Squamous cell carcinoma is defined as the malignant epithelial neoplasm exhibiting squamous differentiation as characterized by the formation of keratin and/or the presence of epithelial bridges (Pindborg JJ).<sup>5</sup>

Most of the OSCC are preceded by a period of premalignant process. And it is well-accepted that particular architectural and cytological changes related with an more risk of malignant development have been proposed as criteria indicated to establish a diagnosis of oral epithelial dysplasia. Thus, the dispute within the field of oral premalignancy is to determine which of them may transform into carcinomas.<sup>6</sup> Proteolytic cleavage of basement membrane protein is an essential step for transformation of dysplastic epithelium to invasive squamous cell carcinoma and proliferative invasion of local tissue as well as metastasis of malignant epithelial cells. The prognosis of OSCC is related to the proliferative capability of the tumour cells, the amount of differentiation, and the invasive and metastatic ability involving penetration of the basement membrane, changes in cell adhesiveness, tumour cell metastasis and angiogenesis.<sup>7</sup> Immunoexpression of cancer markers has made the important method to early diagnosis, estimating the prognosis, targeted nanotheranostics, vaccination and hence preventing early invasion and metastasis.

**Table 1:** Expression of Mucin 1 intensity in different study groups

		Score				Total	
		0	1	2	3		
Group	1- SCC	Count	7	3	1	4	15
		% within group I	46.70%	20.00%	6.70%	26.70%	100.00%
	2- ED	Count	13	0	2	0	15
		% within group II	86.70%	0.00%	13.30%	0.00%	100.00%
	3- NOM	Count	15	0	0	0	15
		% within group III	100.00%	0.00%	0.00%	0.00%	100.00%
Total	Count	35	3	3	4	45	
	% within groups	77.80%	6.70%	6.70%	8.90%	100.00%	

The growth amount of MUC-1 deficient primary breast tumours are slower and metastasis is lower, suggesting that MUC1 is important for the progression of breast cancer.<sup>8</sup> So, it is very much essential to determine and compare the immunoeexpression of Mucin1 in oral squamous cell carcinoma to evaluate the prognosis and pattern of treatment.

Mucins are cell bound glycoproteins, majority of which are membrane bound because of the presence of a hydrophobic membrane that permits retention in the plasma membrane. Mostly, they are produced as a portion of saliva. Currently there are about 21 different varieties of human mucin genes have been discovered. Out of them, MUC1 is a transmembrane glycoprotein encoded by the MUC1 gene and it has been found in various malignancies, including oral carcinomas.<sup>9</sup> The functional process of mucins in normal and tumour cells are as follows;

**4.1. Normal cells**

1. It prevents proteolytic degradation;
2. It facilitates fatty acid uptake;
3. It acts as protective barrier against microbial toxins;
4. It lubricates epithelial surfaces;
5. Enable carbohydrate receptors for microorganisms;
  - (a) Specific elimination of pathogens;
  - (b) Competition of symbiotic strains with pathogens;
6. Mediate cell growth by mimicking high cell density

**4.2. Tumour cells**

1. Shield cell from lower pH caused by high glycolytic activity
2. Allows attachment of tumour cells to normal cells (T, Tn)
3. Creates an functional domain to shield the cell from cellular aggregation (promote metastasis)
4. Protect the cell against immune system by:
  - (a) Acting as an immune blocking agent when travel into the serum
  - (b) Steric hindrance of cell surface antigens engaged in immune recognition (Inhibition of leukocyte

endothelial cell interaction).

Mucin1 (MUC1) acts as both an adhesive and anti-adhesive molecule. In case of OPMD suggesting a cellular adhesive role, preventing the loss of cellular adhesiveness. Whereas in case of progressive and proliferative carcinomas, MUC1 behaves as an anti-adhesive molecule leading to tumour cell motility, proliferative invasion and metastasis. Up-regulation of MUC1 might provide detachment of tumour cells from the cell matrix and from adjacent cell at the primary tumour site. In the process of blood-borne metastasis, it may cover cancer cells from destruction by natural killer cells, making the cancer cells to potentially reach distant sites intact.<sup>9</sup>

This study consisted of 45 study samples, which comprised formalin fixed tissues, ranging from newly confirmed cases to archival retrieved paraffin embedded tissue blocks from our department of less than two years old. 15 cases each of OSCC, OED and normal oral mucosa were included as study group and Colon carcinoma tissue is used as a positive control for MUC1 (Rabbit Monoclonal Antibody – EP 85). The other tissue samples which can be taken up as positive control for mucin 1 are gastrointestinal carcinoma, salivary ductal tissue, urothelial carcinoma, lung carcinoma,<sup>10</sup> breast carcinoma and salivary gland carcinoma tissues. These are according to studies conducted by Suguru yonezawa et al,<sup>11</sup> Nitti et al,<sup>12</sup> Xialong et al,<sup>13</sup> Zhonghua et al,<sup>14</sup> Farzana Mahomed et al,<sup>15</sup> Sukhwinder et al,<sup>16</sup> Guosheng et al,<sup>17</sup> M. Harishkumar et al,<sup>18</sup> Arush Thakur et al<sup>19</sup> and KC Shobhita et al.<sup>20</sup> The localization of this transmembrane glycoprotein is interpreted as brown coloured cytoplasmic and membranous staining which were regarded positive for MUC1. Similar MUC1 staining pattern was observed in most of the studies done by Nitti et al,<sup>12</sup> Suguru Yonezawa et al,<sup>11</sup> Xialong et al,<sup>13</sup> Zhonghua et al,<sup>14</sup> Farzana Mahomed et al,<sup>15</sup> Sukhwinder et al,<sup>16</sup> Guosheng et al,<sup>17</sup> M. Harishkumar et al,<sup>18</sup> Arush Thakur et al<sup>19</sup> and KC Shobhita et al.<sup>20</sup> Whereas according to Sandra J Gendler et al,<sup>10</sup> the brown coloured cytoplasmic mucin component alone was considered positive for MUC1. The presence or absence of mucin1 positive cells as brown coloured cytoplasmic and membranous staining are considered in high power field. The positivity of mucin1

expression was further compared based on the intensity of staining and scored as Score-0: Negative or absence of immunoreactivity; Score-1: Mild, < 25% of stained cells; Score-2: Moderate, 25% to 50% of stained cells; Score-3: Strong, > 50% of stained cells. As there is no one such standard protocol for scoring of positive cells in IHC, there was a slight difficulty in understanding the overall inference of our study with other studies numerically.

In this study, group 1 comprised 15 cases of OSCC. Out of 15 cases, 8 cases (53.3%) were positive for MUC1 and intensity of staining are scored. 3 cases (20%) were positive with (score 1), 1 case (6.7%) were positive with (score 2) and 4 cases (26.7%) were positive with (score 3). The remaining 7 cases (46.7%) were negative (score 0) for MUC1. The 8 positive slides of OSCC in our study showed both cytoplasmic, membranous and keratin pearls also showed positive expression for MUC1. The positivity was either diffuse or focal. These observations let us know that the carcinoma with an active proliferation were only showing positivity for MUC1. Also, are in similar with the results obtained in the study by Shobitha et al,<sup>20</sup> Kumar MH et al<sup>18</sup> and Nitta et al.<sup>12</sup> The cytoplasmic and membranous staining of MUC1 in the squamous epithelial cells may be associated to its cytoplasmic and transmembrane subunits respectively.

The study group 2 comprised 15 cases of oral epithelial dysplasia. Out of 15 cases, 2 (13.3%) cases were positive for MUC1 and intensity of staining was scored. 13 cases (86.7%) were negative (score 0) and the 2 cases (13.3%) were positive with (score 2).

Our study group 3 comprised 15 cases of normal oral mucosa, all the cases doesn't show expression for MUC1 and were given the intensity score - 0. These observations are similar to the results obtained by Thakur et al<sup>19</sup> and Nitta et al.<sup>12</sup> But, these findings are in dissimilar to that of the studies performed by Harish Kumar et al. (2016) that in 2 out of 20 cases of NOM showed positive MUC1 staining.

The cause for this increase in the MUC1 positivity from normal oral mucosa to OSCC could be related to the incapability of less differentiated squamous epithelial cells to express mucins when compared to normal squamous epithelial cells and well differentiated. This phenomenon might be due to suppression of certain inhibitory proteins for MUC1 immunoexpression in well differentiated mature atypical squamous cells. However, in oral epithelial dysplasia there may be more production of particular intrinsic inhibitory proteins for MUC-1 for some unknown mechanism which might have de-differentiation and altered maturation of cells.

## 5. Conclusion

This research infers there is an up-regulation of MUC-1 immunoexpression in oral epithelial dysplasia to oral squamous cell carcinoma. Therefore, MUC-1 may play a

critical role in the pathogenesis of these lesions and also serve as a potential marker for metastasis, invasion and prognosis of oral squamous cell carcinoma. Hence, MUC-1 mucin can be regarded as a prognostic marker for oral squamous cell carcinoma and oral epithelial dysplasia.

## 6. Source of Funding

None.

## 7. Conflict of Interest

None.

## Acknowledgements

I wish to thank my professors and my family for their constant support and motivation as always.

## References

1. Devine PL, McKenzie IF.
2. Agrawal B, Gendler SJ, Longenecker BM. 1998.
3. Wagner CE, Wheeler KM, Ribbeck K. Mucins and their role in shaping the functions of mucus barriers. *Annual review of cell and Developmental Biology*. 2018;34:189–215.
4. El-Naggar AK, Chan JKC, Takata T, Grandis JR, Slootweg PJ. The fourth edition of the head and neck World Health Organization blue book: editors' perspectives. *Hum Pathol*. 2017;66:10–2.
5. Pindborg JJ. Histological typing of cancer and precancer of the oral mucosa / J.J. Pindborg ... [et al.], in collaboration with L.H. Sobin and pathologists in 9 countries, 2nd ed. World Health Organization. Available from: <https://apps.who.int/iris/handle/10665/43552>.
6. Bouquot JE, Speight PM, Farthing PM. Epithelial dysplasia of the oral mucosa-Diagnostic problems and prognostic features. *Curr Diagn Pathol*. 2006;12(1):11–21.
7. Warnakulasuriya S. Histological grading of oral epithelial dysplasia: revisited. *J Pathol*. 2001;194(3):294–7.
8. Yamamoto M, Bharti A, Li Y, Kufe D. Interaction of the DF3/MUC1 breast carcinoma-associated antigen and beta-catenin in cell adhesion. *J Biol Chem*. 1997;272(19):12492–4.
9. Zrihan-Licht S, Baruch A, Elroy-Stein O, Keydar I, Wreschner DH. Tyrosine phosphorylation of the MUC1 breast cancer membrane proteins. Cytokine receptor-like molecules. *FEBS Lett*. 1994;356(1):130–6.
10. Gendler SJ, Spicer AP, Lalani EN, Duhig T, Peat N, Burchell J, et al. Structure and biology of a carcinoma associated Mucin, MUC1. *Am Rev Respir Dis*. 1991;144(3):42–7.
11. Yonezawa S, Sato E. Expression of mucin antigens in human cancers and its relationship with malignancy potential. *Pathol Int*. 1997;47(12):813–30.
12. Nitta T, Sugihara K, Tsuyama S, Murata F. Immunohistochemical study of MUC1 mucin in premalignant oral lesions and oral squamous cell carcinoma. *Cancer*. 2000;88:245–54.
13. Wei X, Hu H, Kufe D. Human MUC1 oncoprotein regulates p53-responsive gene transcription in the genotoxic stress response. *Cancer Cell*. 2005;7(2):167–78.
14. Gao P, Zhou GY, Zhang QH, Xiang L, Ma C, Yu HP. Expression of mucin 1 and tumor invasiveness in breast carcinoma. *Zhonghua Yi Xue Za Zhi*. 2005;85(6):381–4.
15. Mahomed F. Recent advances in mucin immunohistochemistry in salivary gland tumors and head and neck squamous cell carcinoma. *Oral Oncol*. 2011;47(9):797–803.
16. Kaur S, Momi N, Chakraborty S, Wagner DG, Horn AJ, Lele SM, et al. Altered expression of transmembrane mucins, MUC1 and MUC4, in bladder cancer: pathological implications in diagnosis. *PLoS One*.

- 2014;9(3):e92742. doi:10.1371/journal.pone.0092742.
17. Xu F, Liu F, Zhao H, An G, Feng G. Prognostic significance of mucin antigen MUC1 in various human epithelial cancers: a meta-analysis. *Medicine*. 2015;94(50).
  18. Kumar MH, Sanjai K, Kumarswamy J, Keshavaiah R, Papaiah L, Divya S. Expression of MUC1 mucin in potentially malignant disorders, oral squamous cell carcinoma and normal oral mucosa: An immunohistochemical study. *J Oral Maxillofac Pathol*. 2016;20(2):214–8.
  19. Thakur A, Tupkari JV, Joy T, Kende PP, Siwach P, Ahire MS. Expression of mucin-1 in oral squamous cell carcinoma and normal oral mucosa: An immunohistochemical study. *J Oral Maxillofac Pathol*. 2018;22(2):210–5.
  20. Shobitha KC, Shyam N, Preethi P, Poornima R, Priyanka M, Shravani R. Immunohistochemical expression of MUC1 in different grades of oral squamous cell carcinoma. *Asian Pac J Health Sci*. 2018;5(2):165–9.

**P D Balamurali**, Associate Dean (Research) & Professor

**V Ramesh**, Professor and Head

**Karthikshree V Prashad**, Professor

**D Mounika**, Junior Resident

**Dhanalakshmi**, Junior Resident

**Cite this article:** Kootiswaran S, Balamurali PD, Ramesh V, Prashad KV, Mounika D, Dhanalakshmi. Mucin1 utterance in oral squamous cell carcinoma: A cancer maker and target for nanotheranostics. *J Oral Med, Oral Surg, Oral Pathol, Oral Radiol* 2023;9(3):138-143.

## Author biography

**Kootiswaran S**, Junior Resident  <https://orcid.org/0000-0002-5866-9626>