

Content available at: <https://www.ipinnovative.com/open-access-journals>

Journal of Oral Medicine, Oral Surgery, Oral Pathology and Oral Radiology

Journal homepage: www.joooo.org**Case Report****Hemangiomas of gingiva mimicking pericoronitis: A case report****S Divya Bharathi¹, Shanthi M^{1,*}, Divya V C¹, Ganesh C¹**¹Dept. of Oral Medicine and Radiology, SRM Katankulathur Dental College and Hospital, Kattankulathur, Tamil Nadu, India**ARTICLE INFO***Article history:*

Received 23-01-2023

Accepted 28-07-2023

Available online 08-09-2023

Keywords:

Oral hemangioma

Pericoronitis

Vascular malformations

Vascular tumors

ABSTRACT

Malformations and vascular tumors can occur anywhere on the body. Hemangiomas, or vascular tumors, are rare at birth, develop quickly during the first six months of life, involute over time, and can occasionally be harmful even though they do not always spread. Uneven vascular networks, known as vascular malformations, are identified by a certain blood vessel type. Hemangiomas is of benign origin and behavioral but, Hemangioma in the oral cavity is of clinical importance. It often mimics other lesions clinically and requires appropriate clinical diagnosis and proper management. Accurate diagnosis of the lesion plays an important role in framing the correct protocols and for delivering the correct treatment. Imaging techniques such as Ultrasound with color doppler may be needed in combination to determine the nature of the blood supply to the lesion either arterial, venous or arteriovenous malformation and can also aid with diagnosis and treatment. It is also beneficial in eliminating non vascular lesions. This paper presents one such interesting case.

This is an Open Access (OA) journal, and articles are distributed under the terms of the [Creative Commons Attribution-NonCommercial-ShareAlike 4.0 License](https://creativecommons.org/licenses/by-nc-sa/4.0/), which allows others to remix, tweak, and build upon the work non-commercially, as long as appropriate credit is given and the new creations are licensed under the identical terms.

For reprints contact: reprint@ipinnovative.com**1. Introduction**

Hemangioma is a term that encompasses a heterogeneous group of clinical benign vascular lesions that have similar histologic features.¹ They are structural anomalies in vascular apparatus components that may be clinically noticeable at birth, grow slowly in proportion to the child's growth (marked by hypertrophy), and never involute² and are composed of many small capillaries lined with endothelial cells supported in the connective tissue stroma and show a rapid growth phase followed by gradual involution.^{3–6} Vascular malformations have been classified into many types. Mulliken and Glowacki first introduced a categorization system in 1982, and it is being used today. Hemangioma and vascular malformation are the two basic categories under which these vasoformative tumours are categorized. According to their histological

appearance, hemangiomas can be further subclassified as (1) capillary lesions, (2) cavernous lesions, or (3) mixed lesions.⁷ Periodontally, these lesions generally arise from the interdental gingival papilla and spreads laterally to involve adjacent teeth.⁸

2. Case Report

A 26-year-old female patient reported to the department of oral medicine and radiology with complaint of Painful swelling in the left lower back tooth region for the past 8 months. She was apparently normal, she had difficulty in speech followed by painful swelling after consumption of cold foods. The swelling was small in size initially. Later, it gradually attained its present size. No relevant family history elicited.

On extraoral examination, facial asymmetry was detected. On inspection, a well-defined localized swelling evident on the left lower-third of the face. The swelling

* Corresponding author.

E-mail address: sdivyabharathi2811@gmail.com (Shanthi M).

measured 2.5 x 2.5cm in size extending 2 cm away from the left angle of mouth anteriorly. Posteriorly extending till angle of the mouth. Superiorly, it extended from the ala tragal line and inferiorly involved the lowermost border of the mandible and was clearly elicited on frontal view. On palpation, all the inspeactory findings of site, size, shape and extent are confirmed. The swelling was warm and tender. It was not fixated to any underlying structures.

On intraoral examination, vestibular obliteration of the lower left buccal vestibule extending from the medial aspect of 36 to distal of 38 with inflammation. Infection of pericoronal flap in relation to 38 region was evident. Grade 1 mobility and periodontal pocket associated with the molars 36, 37 and 38. Mouth opening was restricted. Based on the clinical findings, provisional diagnosis were :

1. Pericoronitis in relation to 38
2. Vascular malformation

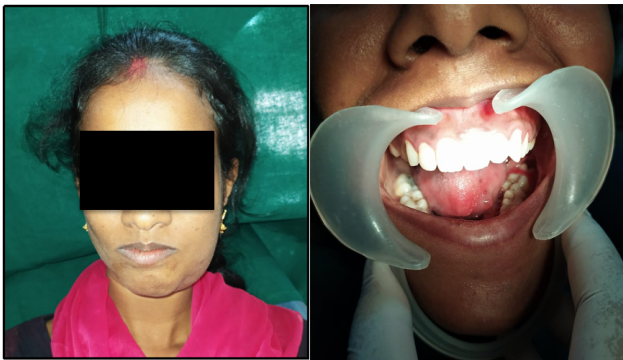

Fig. 1: Swelling evident on left side of the face

2.1. Computed tomography (CT)

Computed tomography (CT) revealed a relatively well-defined soft tissue density lesion measuring 4.2 x 2.9 x 3.1 cm in left submandibular space extending superiorly and anteriorly upto left retromolar trizone. Laterally, lesion extends upto subcutaneous fat in left submandibular space. No evidence of bone erosion was noted. On contrast administration, lesion shows discontinuous nodular peripheral enhancement at early arterial phase.

2.2. Color doppler ultrasound

Color doppler ultrasound revealed an ill-defined hyperechoic lesion measuring 3.8 x 4.1 x 2.8 cm seen in the left submandibular and angle of mandible region. The lesion is seen in close proximity to the left submandibular gland. Internal vascularity seen within the lesion. Few prominent vessels are seen within the lesion. Prominent vein draining the lesion seen. Left Internal Jugular vein appears prominent. Suspicious arterial feeder seen arising

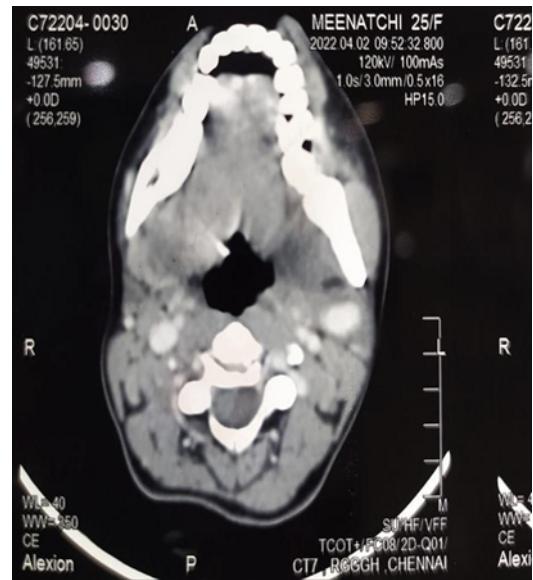


Fig. 2: Radiolucency is seen along the left side of the computed tomography

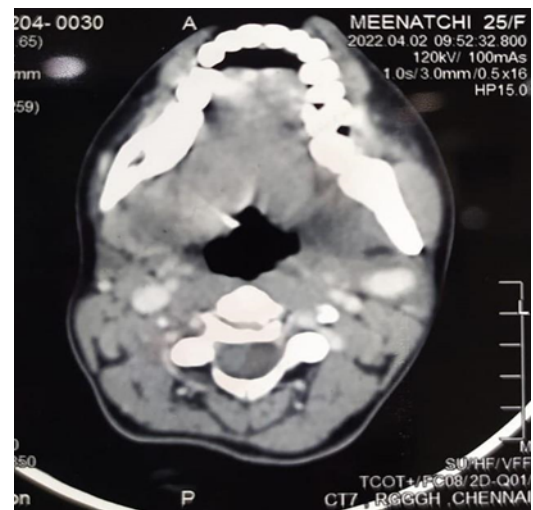


Fig. 3: Swelling is evident on the left side of the computed tomography

from left External Carotid Artery seen supplying the lesion. A cystic focus with 2.2 x 1.0 cm seen in the left parotid gland. Left submandibular gland appears edematous. Few enlarged nodes are seen in the left submandibular region, the largest node measuring 2.1 x 1.0 cm.

Correlating the chief complaint, clinical examination, intra oral examination, investigations the case is finally diagnosed as “vascular tumor/ malformation”.

Patient was not willing for the Histopathological exam hence, it was not performed.

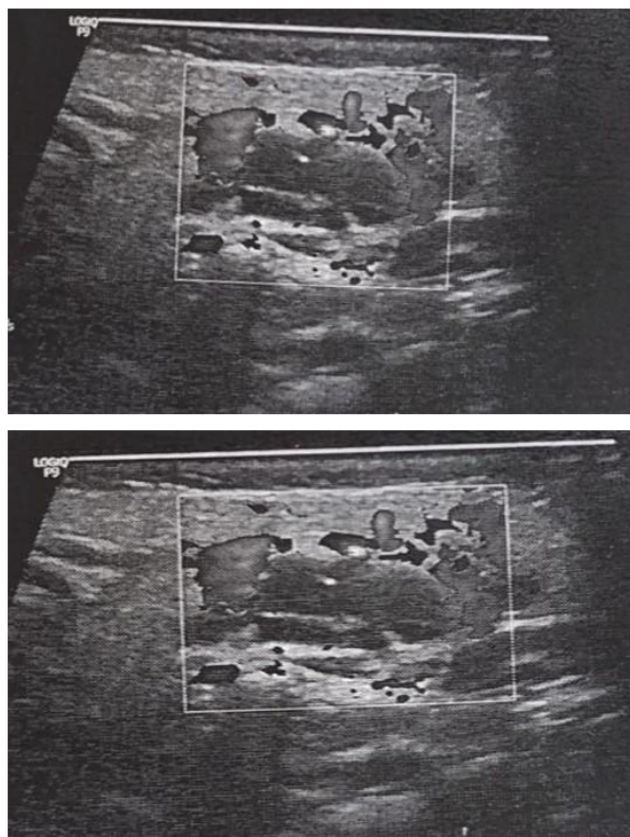


Fig. 4: Lesion in computed tomography

3. Discussion

Malformations and vascular tumours can occur anywhere on the body. Hemangiomas, or vascular tumours, are rare at birth, develop quickly during the first six months of life, involute over time, and can occasionally be harmful even though they do not always spread.⁹ Uneven vascular networks, known as vascular malformations, are identified by a certain blood vessel type.

Vascular malformations are clinically characterized as soft, compressible, nonpulsatile masses of tissue. The overlying skin is usually a bluish tint. The most commonly affected sites are the head and neck (40% of cases), extremities (40%) and trunk (20%). Intraoral Blood vessel malformations can cause bleeding, malocclusion, verbal disorders, and cause upper airway and throat blockage. Associated discomfort Thrombosis (40%) are also commonly seen in Vascular Malformations.

Numerous imaging techniques, including Magnetic Resonance Imaging (MRI), Computed Tomography, Doppler Ultrasound, and Direct Phlebography, can be used to diagnose vascular malformations. To validate the diagnosis of vascular malformations, interventional radiologic techniques also play a crucial role. At Doppler ultrasound, there is no flow or only slow venous flow. MRI helps to assess the boundaries of Vascular Malformations.

On T1-weighted images, these lesions are typically hypointense, and on T2-weighted images, they are clearly hyperintense. Direct phlebography helps to validate the diagnosis and rule out other soft tissue tumors. Because modern sonographic equipment is ideally suited to examining superficial lesions, ultrasound, a noninvasive method is Gold Standard for examining such lesions. Color doppler ultrasound was helpful in the diagnosis of vascular malformations/tumor in this case.¹⁰

4. Conclusion

Proper diagnosis of the lesion plays an important role in framing the correct diagnosis, protocols and for delivering the correct treatment. CT, Ultrasound investigations were effective in classification, detection of early complications and diagnosis of lesions. It is also beneficial in eliminating non vascular lesions. It is important to remember that there are two types of vascular abnormalities in the head and neck: vascular tumours, which are real proliferating neoplasms, and vascular malformations, which are vascular morphogenesis defects.

5. Source of Funding

None.

6. Conflict of Interest

None.

References


1. Doorne L, Maeseneer MD, Stricker C, Vanrensbergen R, Stricker M. Diagnosis and treatment of vascular lesions of the lip. *Br J Oral Maxillofac Surg*. 2002;40(6):497–503.
2. Enzinger FM, Weiss SW. Soft tissue tumors. 3rd ed. St Louis: Mosby; 1995. p. 581–6.
3. Kerr AR, Trochesset DA, Lockhart PB, Challacombe SJ. Benign Lesions of the Oral Cavity and the Jaws. In: Glick M, Greenberg MS, editors. *Burket's Oral Medicine*. United States: Wiley; 2021. doi:10.1002/9781119597797.ch6.
4. Bayrak S, Dalci K, Tansel H. Capillary hemangioma of the palatal mucosa: Report of an unusual case. *SÜ Dishek Fak Derg*. 2010;19:87–9.
5. Chen YK, Lin LM, Huang HC, Lin CC, Yan YH. A retrospective study of oral and maxillofacial biopsy lesions in a pediatric population from southern Taiwan. *Pediatr Dent*. 1998;20(7):404–10.
6. Neville BW, Damm DD, Allen CM, Bouquot JE. *Oral & Maxillofacial Pathology*. 2nd ed. Philadelphia: Saunders; 2002. p. 390–92.
7. Mueller BU, Mulliken JB. The infant with a vascular tumor. *Semin Perinatol*. 1999;23(4):332–40.
8. Carranza FA. *Glickman's Clinical Periodontology*. 1st ed. Philadelphia: WB Saunders Co; 1990. p. 335–51.
9. Richter GT, Friedman AB. Hemangiomas and vascular malformations: current theory and management. *Int J Pediatr*. 2012;2012:645678. doi:10.1155/2012/645678.
10. Mulligan PR, Prajapati HJS, Martin LG, Patel TH. Vascular anomalies: classification, imaging characteristics and implications for interventional radiology treatment approaches. *Br J Radiol*. 2014;87(1035):20130392. doi:10.1259/bjr.20130392.

Author biography

Ganesh C, Senior Lecturer  <https://orcid.org/0000-0002-5286-2775>

S Divya Bharathi, Student

Shanthi M, Assistant Professor  <https://orcid.org/0000-0002-6704-1849>

Divya V C, Associate Professor  <https://orcid.org/0000-0001-7042-6435>

Cite this article: Bharathi SD, Shanthi M, Divya V C, Ganesh C. Hemangiomas of gingiva mimicking pericoronitis: A case report. *J Oral Med, Oral Surg, Oral Pathol, Oral Radiol* 2023;9(3):163-166.