



Content available at: <https://www.ipinnovative.com/open-access-journals>

Journal of Oral Medicine, Oral Surgery, Oral Pathology and Oral Radiology

Journal homepage: [www.joooo.org](http://www.joooo.org)



## Case Report

# Verrucous carcinoma on lateral tongue in association with oral submucous fibrosis: A rare case report

Chandrakanth Beesa<sup>1</sup>, Amith Kumar Padmala<sup>1</sup>, Manasa Tulsham<sup>1</sup>, Rakshana E<sup>1</sup>,  
Vinay Kumar Reddy Kundoor<sup>1</sup>, Kotya Naik Maloth<sup>1</sup>\*

<sup>1</sup>Dept. of Oral Medicine and Radiology, Mamata Dental College and Hospital, Khammam, Telangana, India



## ARTICLE INFO

### Article history:

Received 26-04-2024

Accepted 15-05-2024

Available online 17-06-2024

### Keywords:

Exophytic verrucous hyperplasia

Carcinoma

Oral submucous fibrosis

Proliferative Verrucous leukoplakia

## ABSTRACT

Oral verrucous carcinoma (VC) is a rare tumor, which a clinical variant of well differentiated oral squamous cell carcinoma characterized by exophytic growth or cauliflower like growth in appearance. It establishes in older individuals, who has habit of chronic tobacco chewing and predominance in males. Oral submucous fibrosis (OSMF) is a chronic, insidious, potentially malignant disorder associated with betel nut chewing habit. The development of oral squamous cell carcinoma (OSCC) is seen in one-third of the OSMF patients, but the development of VC is rarely seen in such patients. In the literature a very few cases of OSMF with VC are reported. Here, we present such a rare case in a 25 years old female patient with VC in conjunction with OSMF.

This is an Open Access (OA) journal, and articles are distributed under the terms of the [Creative Commons Attribution-NonCommercial-ShareAlike 4.0 License](https://creativecommons.org/licenses/by-nc-sa/4.0/), which allows others to remix, tweak, and build upon the work non-commercially, as long as appropriate credit is given and the new creations are licensed under the identical terms.

For reprints contact: [reprint@ipinnovative.com](mailto:reprint@ipinnovative.com)

## 1. Introduction

Oral verrucous carcinoma is a rare tumor which is clinically distinct variant of squamous cell carcinoma exhibiting exophytic, fungating, proliferative or cauliflower like growth, which was first described by Lauren V. Ackermann in 1948.<sup>1</sup> The prevalence rate accounts for <1-10%.<sup>2</sup> In the literature this entity was described with various names such as Ackermann's tumor, Buschke-Loewenstein tumor, florid oral papillomatosis, and carcinoma cuniculatum. The tumor is invasive with locally slow growing and unlikely to metastasize. Clinically, appears as asymptomatic thick white plaque resembling cauliflower in appearance.<sup>2</sup> The exact etiology was not established but it is suggested that chronic tobacco chewing or smoking plays a major causative factor for verrucous carcinoma.<sup>3</sup> The most common oral mucosal involvement include buccal mucosa, followed by mandibular alveolar crest, gingiva and tongue

with a mean age of 60-70 years with male predominance.<sup>4</sup> Here we report such a rare case of verrucous carcinoma in association with OSMF in a 35 years old female patient.

## 2. Case Report

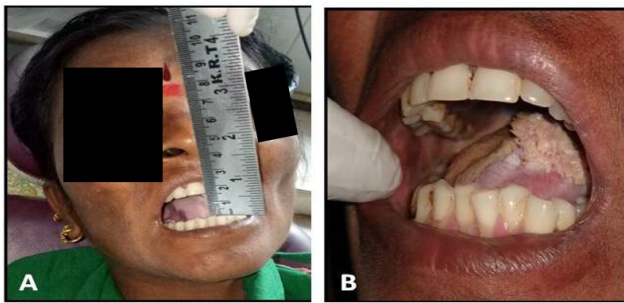A 35 years old female patient reported in the department with a chief complaint of overgrowth involving left dorsal and lateral aspect of tongue with burning sensation in her mouth since 1 year. Patient revealed that she was asymptomatic 1 year back and suddenly noticed a small peanut size growth over the tongue on left side which has overgrown gradually to the present size. The overgrowth was not associated with any pain or discharge. She also reveals reduced mouth opening along with burning sensation of buccal mucosa. Her past dental and medical history, including her family history was non-contributory. Patient revealed she has a habit of tobacco chewing in the last 15 years accompanied with areca nut and chews 4-5 packets per day. On extraoral examination revealed a

\* Corresponding author.

E-mail address: [dr.kotyanaik.maloth@gmail.com](mailto:dr.kotyanaik.maloth@gmail.com) (K. N. Maloth).

solitary palpable left submandibular lymphnode measuring about 1 x 1cm in size, oval in shape which is movable, overlying skin was normal with no local rise of temperature and no discharge, which was non-tender and soft to firm in consistency.

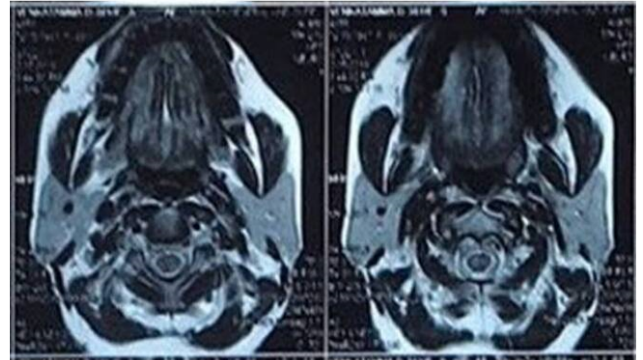
Intraoral examination revealed restricted mouth opening with a maximum interincisal distance of 16 mm. (Figure 1 A) On inspection a whitish papillary growth was seen on left lateral border of tongue measuring about 3 x 3cm in size. Extending antero-posteriorly 3cm away from tip of the tongue extending 3cm posteriorly and medio-laterally from midline on dorsal surface of the tongue to 3cm towards left lateral border of tongue. The tongue was completely bald with proliferative growth on left side with restricted lateral movement. On intraoral examination revealed paleness of buccal mucosa with bilateral palpable tough vertical fibrous bands posteriorly. Exophytic white lesion seen on left lateral border of tongue and dorsal aspect with irregular surface and had finger-like projections.(Figure 1 B) Hard tissue examination revealed presence of full complimentary of teeth with moderate deposits.



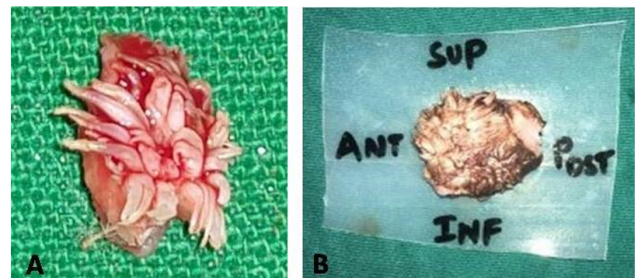
**Figure 1:** Shows restricted mouth opening with a maximum interincisal distance of 16 mm (A), and intraoral examination reveals an exophytic white lesions on dorsal surface and left lateral borders of tongue with irregular surface with finger-like projections.(B)

Base-line haematological Investigations were non-contributory. Radiographical investigations such as Orthopantomography (OPG), Magnetic Resonance Imaging (MRI) were performed. OPG finding were non-contributory. MRI of tongue revealed that the lesion appeared to involve left superior longitudinal and left styloglossus muscle however rest of the visualized muscles like transverse/inferior longitudinal muscles genioglossus and mylohyoid muscles appeared normal. (Figure 2) Based upon the history and clinical examination, verrucous hyperplasia with OSMF was considered as provisional diagnosis along with a differential diagnosis of PVL, Verrucous carcinoma. An incisional biopsy was performed on left lateral border of tongue. (Figure 3) The given H&E-stained soft tissue section showed the presence of hyperkeratotic stratified squamous epithelium with excessive parakeratinization and bulbous rete pegs pushing into the connective tissue. Cleft like spaces were present

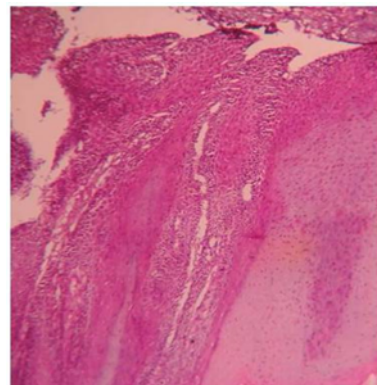
showing parakeratin plugging. No dysplastic features were evident. The underlying connective tissue showed dense chronic inflammatory cell infiltration especially in the sub-epithelial region. Underlying connective tissue was fibrous with dense bundles of collagen fibers with minimal vascularity suggestive of OSMF with VC a final diagnosis was given. (Figure 4)



**Figure 2:** MRI of tongue reveals that the lesion appears to be involving left superior longitudinal and left styloglossus muscle

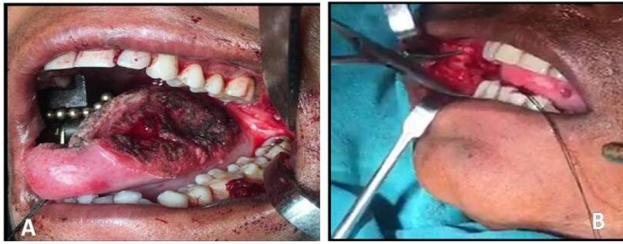


**Figure 3:** An incisional biopsy specimen



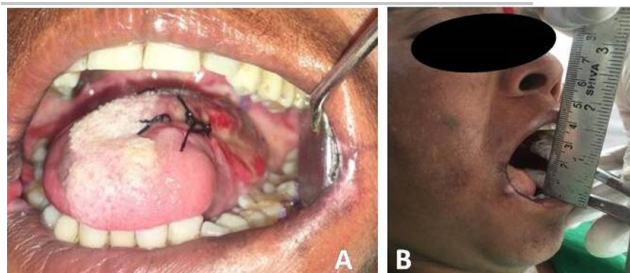
**Figure 4:** Microscopic (4x) H&E-stained soft tissue section showing bulbous rete pegs, parakeratin plugging

Patient was treated surgically, partial glossectomy of dorsal aspect and left lateral border of tongue with surgical



**Figure 5:** Shows surgical management subjected to partial glossectomy on left lateral border of tongue (A), surgical management of oral submucous fibrous bands (B)

release of fibrous bands was done. (Figure 5 A, B) The patient is under regular follow up once in 3 months without any recurrence till date.(Figure 6A, B)



**Figure 6:** Post treatment follow up after one month (A) intraoral and (B) mouth opening with a maximum inter-incisal distance of 36 mm

### 3. Discussion

Verrucous Carcinoma (VC) is a slow growing rare tumor, which spreads horizontally rather than vertical. Clinically, it represents a distinct variant of squamous cell carcinoma exhibiting exophytic, fungating, proliferative or cauliflower like growth, accounts for <1-10%.<sup>2</sup> VC may manifest clinically from the progression of proliferative verrucous leukoplakia (PVL) and progress to carcinoma.<sup>1,5</sup>

The exact etiology of VC is not well established, but based on literature and various authors observation suggested that history of tobacco usage in the form of smoking or smokeless tobacco habits are highly causative agents along with other predisposing factors like poor oral hygiene, oral lichenoid reactions and oral leukoplakia which play a role.<sup>6,7</sup> My case was consistence with literature where patient has habit of tobacco chewing accompanied by areca nut.

In 1980, Shear and Pindborg described a condition termed verrucous hyperplasia (VH). VH has been considered an antecedent stage or early stage of VC because clinically and pathologically VH closely resemble VC. Histopathologically a clear differentiation should be made between VH and VC. Where VH is more superficial

without invasion into deeper epithelial layers than adjacent normal epithelium. VH shows dysplastic cells and can later progress to VC or Squamous cell carcinoma. Whereas, VC extends to more deeply, pulling the adjacent normal epithelium at its margins.<sup>8</sup>

Oral submucous fibrosis (OSMF) is a chronic, insidious, potentially malignant disorder, affecting the oral mucosa associated strongly with chronic areca nut chewing habit. OSMF carries a high-risk of malignant transformation rate in the range of 3% - 19%. One third of the OSMF patients develop OSCC, but the development of VC is rarely seen in such patients.<sup>8,9</sup>

VC may develop de novo or from an existing PVL. But development from existing OSMF patients is rarely seen. In such cases it is more difficult to draw final conclusion to establish VC developed from OSMF due to very few cases reported in the literature.<sup>10</sup> Moreover in the present case, patient has a habit of tobacco chewing associated with areca nut. Hence, it can be extrapolating that OSMF could be the cause for the development of VC.

Most of the VC that develops in older individuals have a history of taking smokeless tobacco habit for several years. Rarely documented in younger individuals. In the literature reported such as Friedell and Rosenthal in 1941 reported eight cases of VC in men over 60 years. Ackerman in 1948 reported 31 cases of VC in old individuals. Sorger in 1960 reported four cases of VC in men above 70 years.<sup>8</sup> The present case reported was 25 years old female patient, which is contradictory to literature except the habit history.

The most common mucosal site involvement includes buccal mucosa followed by mandibular alveolar crest, palate, floor of the mouth and gingiva, tongue involvement is rarely seen.<sup>7</sup> Clinically, it is represented as cauliflower-like exophytic growth, fungating, proliferative or finger-like projections. The present case reported on left lateral border of tongue with a cauliflower-like exophytic growth in a 25 years old female patient.

A definitive diagnosis of VC should be established by differentiating with other verrucous lesions such as PVL, VH through biopsy taken at the margin of the lesions. The concurrence between the clinician's regard of the tumor and the pathologist's identification of microscopic criteria described by Ackermann should be taken into consideration for final diagnosis.<sup>5</sup>

Surgical management stays the primary mode of treatment for Oral VC with good prognosis. Surgical excision and primary grafting with regular long-term follow-up for recurrence can be considered as a feasible option for the treatment of oral VC.<sup>1</sup> The treatment of OSMF has been concentrated on attempts to improve opening of the mouth by medical or surgical management. Surgery has not always been attempted in severe and diffuse cases of OSMF. Thus, surgical excision and skin grafting are applicable where the areas of fibrosis are

localized and access is unrestricted.<sup>3</sup> Surgical excision of VC shows excellent prognosis, and recurrence may occur with incomplete excision of the tumor.<sup>8</sup> In the present case the lesion was surgically excised and patient follow up till date showed no recurrence.

#### 4. Conclusion

In the literature many studies established that VC can develop de novo or from preexisting leukoplakia, but in our case, VC could have developed from preexisting OSMF in a 25 years old female patient on left lateral border of tongue which is rare and unique. Early diagnosis of VC and proper surgical management leads to excellent prognosis.

#### 5. Source of Funding

None.

#### 6. Conflict of Interest

None.

#### References

1. Malhotra S, Raghavan V, Kumar A, Singh AK. Verrucos carcinoma on pre-existing oral submucous fibrosis. *J Indian Acad Oral Med Radiol*. 2015;27:593–7.
2. Greenberg MS, Glick M, Ship JA. *Burket's Oral Medicine*. 11th ed. Hamilton: Decker Inc; 2008. p. 162.
3. Khot K, Deshmukh SB, Deshmukh A. Verrucous Carcinoma with Oral Submucous Fibrosis: A Rare Case with Brief Review. *J Clin Diagn Res*. 2015;9(8):6–8.
4. Shafer WG, Hine MK, Levy BM. Benign and malignant tumors of the oral cavity. In: *A Textbook of Oral Pathology*. Philadelphia: WB: Saunders Company; 1983. p. 127–30.
5. Passi D, Singh G, Gupta C, Patra D. Verrucous carcinoma – A diagnostic dilemma: Case series, differential diagnosis, therapy and literature review. *J Adv Med Dent Sci*. 2014;2:141–6.
6. Asha ML, Vini K, Chatterjee I, Patil P. Verrucous carcinoma of buccal mucosa: A case report. *Int J Adv Health Sci*. 2014;1:19–23.
7. Hazarey VK, Ganvir SM, Bodhade AS. Verrucous hyperplasia: A clinico-pathological study. *J Oral Maxillofac Pathol*. 2011;15:187–91.
8. Pravda C, Srinivasan H, Koteeswaran D, Manohar LA. Verrucous carcinoma in association with oral submucous fibrosis. *Indian J Dent Res*. 2011;22:615.
9. Shah AM, Bansal S, Shirsat PM, Prasad P, Desai RS. Exophytic verrucous hyperplasia in oral submucous fibrosis: A single-center study. *J Oral Maxillofac Pathol*. 2019;23(3):393–9.
10. Oliveira DT, Moraes RVD, Filho JFF, Neto JF, Landman G, Kowalski LP, et al. Oral verrucous carcinoma: A retrospective study in São Paulo Region, Brazil. *Clin Oral Investig*. 2006;10(3):205–9.

#### Author biography

**Chandrakanth Beesa**, Post Graduate

**Amith Kumar Padmala**, Post Graduate

**Manasa Tulsham**, Post Graduate

**Rakshana E**, Post Graduate

**Vinay Kumar Reddy Kundoor**, Professor and Head

**Kotya Naik Maloth**, Senior Lecturer  <https://orcid.org/0000-0001-5822-4814>

**Cite this article:** Beesa C, Padmala AK, Tulsham M, Rakshana E, Kundoor VKR, Maloth KN. Verrucous carcinoma on lateral tongue in association with oral submucous fibrosis: A rare case report. *J Oral Med, Oral Surg, Oral Pathol, Oral Radiol* 2024;10(2):122-125.