

Content available at: <https://www.ipinnovative.com/open-access-journals>

Journal of Oral Medicine, Oral Surgery, Oral Pathology and Oral Radiology

Journal homepage: [www.joooo.org](http://www.joooo.org)

## Case Report

# Impacted mandibular 3<sup>rd</sup> molar- An enigma in diagnosis

Humera Ayesha <sup>1</sup>\*<sup>1</sup>Dept. of Oral Medicine & Radiology, Rajiv Gandhi University of Health Sciences, Bengaluru, Karnataka, India

### ARTICLE INFO

#### Article history:

Received 12-12-2023

Accepted 29-02-2024

Available online 17-06-2024

#### Keywords:

Third molar  
Impaction  
Pericoronitis

### ABSTRACT

The clinical presentation of third molar impaction cases differs from patient to patient. The different clinical aspects of mandibular third molar impactions include pain at the site or radiating pain in the jaw, trismus, cheek bite, difficulty in mastication abscess formation requiring incision and drainage. A significant number of cases are asymptomatic and are detected only on routine radiographic examination. A few cases also show unusual symptoms and clinical presentation. Hence the present case is intended to publish the unusual or the incomplete presentation, creating a diagnostic enigma.

This is an Open Access (OA) journal, and articles are distributed under the terms of the [Creative Commons Attribution-NonCommercial-ShareAlike 4.0 License](https://creativecommons.org/licenses/by-nc-sa/4.0/), which allows others to remix, tweak, and build upon the work non-commercially, as long as appropriate credit is given and the new creations are licensed under the identical terms.

For reprints contact: [reprint@ipinnovative.com](mailto:reprint@ipinnovative.com)

## 1. Introduction

Third molar impactions may manifest or may remain asymptomatic or may be associated with various pathologies such as caries, pericoronitis, cysts, tumors, root resorption of the adjacent tooth.<sup>1</sup> Various studies on impacted third molar are present in the literature which concluded significant correlation between the patients suffering from pain, trismus, and swelling associated with impacted third molar.<sup>2</sup> Significant percentage of impacted third molars remain asymptomatic throughout life.<sup>3</sup> Few cases of impacted third molars also manifest with infection with abscess which need incision and drainage and may even require hospitalization especially in older patients.<sup>4</sup>

## 2. Case Report

A 25-year-old male patient reported to the department with a chief complain of swelling on the left side of the face since past 5 days. History of present illness revealed that the patient developed swelling on the left side of the face which was initially smaller in size and gradually increased

to attain the present size. On further eliciting the history the patient developed on and off on the left side of face every 3 months, which was subsided on medication. Whenever the patient developed swelling, he visited the pharmacy and had a course of antibiotics and analgesic. But for the past 5 days swelling was progressive and did not subside even on taking medication. There was no pain associated with any tooth.

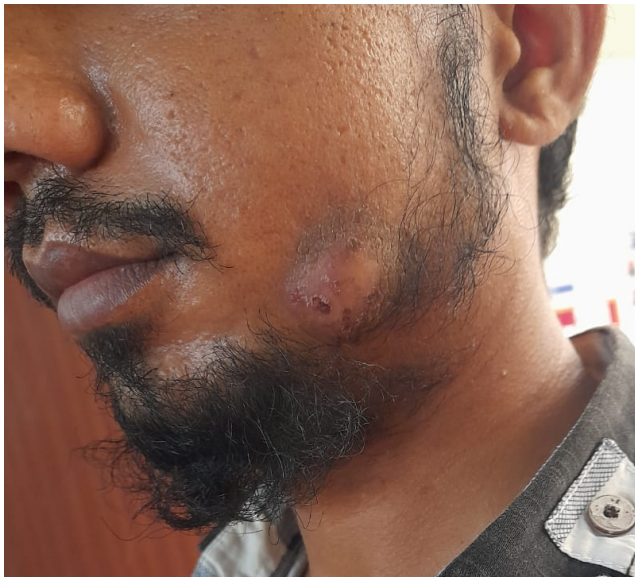On general physical examination, there was no abnormality detected with respect to gait, patient was moderately built, moderately nourished. All the vital signs were within the normal range patient was afebrile.

On extraoral examination, there was marked asymmetry noted due to the presence of diffuse swelling on the left side of face, measuring around 6×5cm. The swelling was extending from 2cm below the lower eyelid to 6cm inferiorly up to the lower border of mandible. Mediolaterally the swelling was extending from the ala of the nose to tragus of the ear. (Figure 1)

A solitary spherical well defined nodular swelling was present on the lower left mental region, measuring around 2×2cm. The skin over the swelling appears to be erythematous. (Figure 1)

\* Corresponding author.

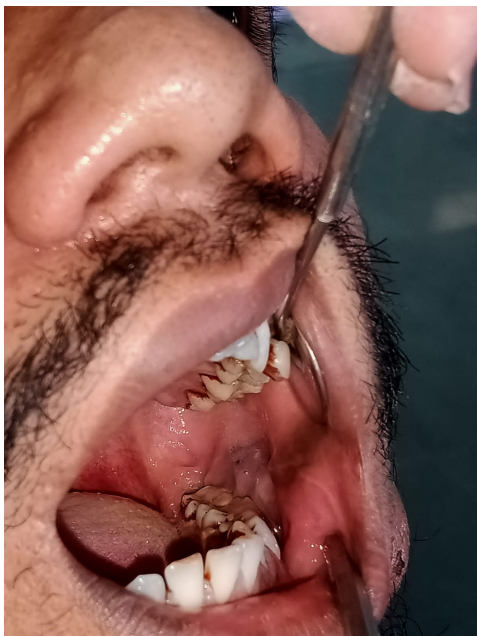E-mail address: [reachaysha85@gmail.com](mailto:reachaysha85@gmail.com) (H. Ayesha).



**Figure 1:** Presence of extraoral swelling on the left middle and lower 1/3<sup>rd</sup> of face

On palpation, the diffuse swelling was tender on palpation, soft in consistency, compressible and non-reducible. The nodular swelling was soft to firm in consistency and tender on palpation.

On intraoral examination, there was partially erupted 38 and vestibular obliteration extending from 34 to 38 which was soft to firm in consistency. (Figure 2)

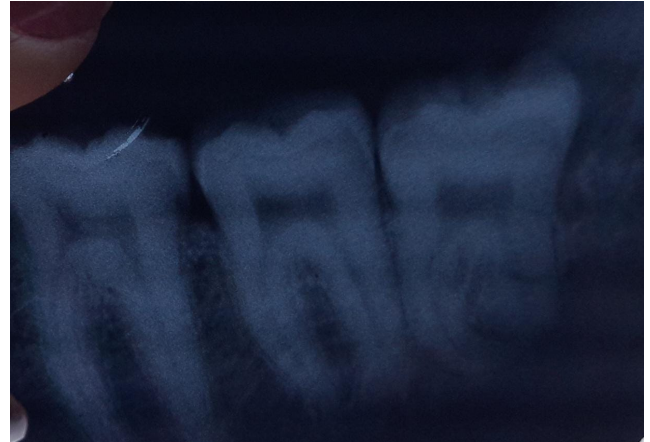


**Figure 2:** Intraoral finding with partially erupted 38

Provisional diagnosis of Impacted 38 with consolidated abscess and cellulitis of left side of face was

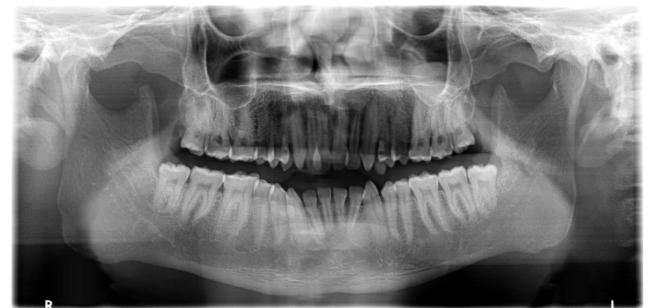given. Differential diagnosis was chronic suppurative osteomyelitis, chronic tuberculous osteomyelitis.

On radiographic examination IOPA showed semilunar radiolucency distal to 38 extending cervically, mesial root dilaceration and distal root resorption with respect to 38. (Figure 3)



**Figure 3:** IOPA

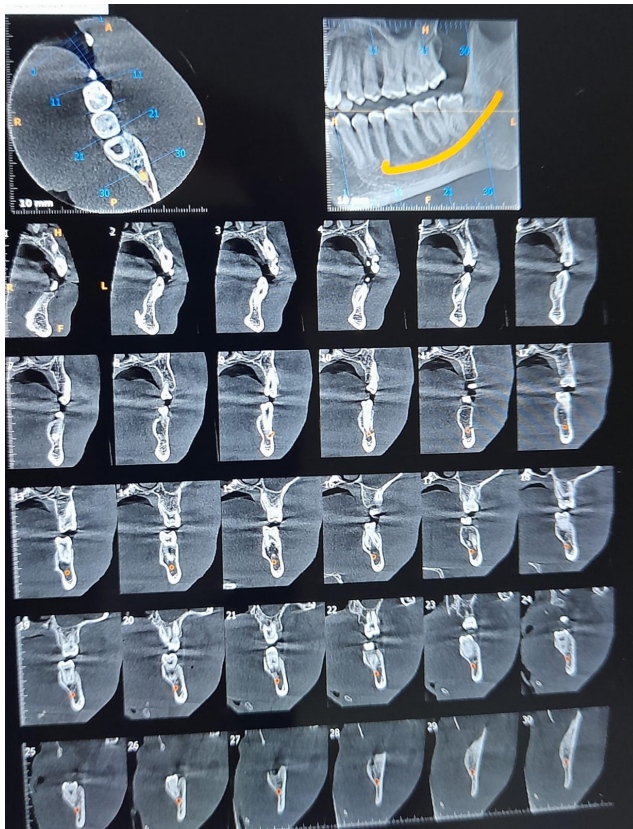
The OPG showed semilunar radiolucency with respect to 38. A soft tissue shadow was seen on the coronal aspect of 35,36,37,38. (Figure 4 )



**Figure 4:** OPG showing semilunar radiolucency with respect to 38. A soft tissue shadow was seen on the coronal aspect of 35, 36, 37, 38

CBCT scan performed with Kavo 3D pro scanner image processing was performed on demand software. The data was provided by 3D dental CT scan. Radiographic findings on CBCT showed there were no signs of bony pathology. 38 was vertically impacted arc shaped bone loss observed distal to 38 suggestive of pericoronitis. Two roots observed deeply situated in alveolar bone close to lingual cortex. Curvature observed with mesial root. The mandibular canal was in close approximation and is apical to roots of 38. There were no signs of cystic change nor resorption. over retained 63 labials to 23,24. (Figure 5)

No signs of periapical pathology. periodontal health was at the normal limit. mucosal thickening with the left



**Figure 5:** CBCT showing vertically impacted 38

maxillary sinus.

Radiographic diagnosis was vertical impaction with pericoronitis with respect to 38.

### 3. Discussion

#### 3.1. Common chief complain

Pain is the most common chief complain in case of impacted third molar which are reported in different populations.<sup>4-7</sup> There is a lack of reliable evidence for the predictability that an unerupted and pathology-free third molar will cause disease.<sup>7,8</sup> The present case did not show the usual symptoms of pain or discomfort in third molar region or trismus. Due to the repeated use of antibiotics and analgesics the infection remained subclinical.

#### 3.2. Periodontal findings

Recently it is reported that more than 4 mm probing depth can be predictive factor for periodontal pathology.<sup>9</sup> Infections originating in the root apices, which are positioned beyond the attached portion of the mylohyoid muscle, directly extend into the submandibular space (SMS). Despite the position of the apices, most infections consequently involve the SMS.<sup>10</sup>

#### 3.3. Path of spread of the infection

The buccinator muscle is attached bucco-lingually to the mandible near the impacted third molar, it probably plays a role in the spread of infection.<sup>11</sup> In the present case the path of drainage was buccal to the buccinator muscle hence the patient developed buccal space infection.

#### 3.4. Evolutionary aspects

Due to the evolutionary process, the human jaw has shrunk, and in this process, there is insufficient. The overall impaction of right mandibular third molar was reported to be less than on the left side, and the ratio of left to right side impaction was 11:10.<sup>12</sup>

#### 3.5. Radiographic aspects

An intraoral image may be sufficient before surgical intervention of mandibular third molars, if the whole tooth and the mandibular canal are displayed in the image. If there is an over projection between the roots of the tooth and the canal, eccentric examinations can be performed and the tube shift technique in the vertical plane [same lingual opposite buccal (SLOB) rule]<sup>3</sup> used to interpret, if the third molar is positioned buccally or lingually to the mandibular canal.<sup>13</sup>

#### 3.6. Microbiology associated with third molars

Predominant bacteria implicated in peri coronal abscess are Streptococcus viridans, fusobacteria spirochetes, and mixed oral flora.<sup>14</sup> Pericoronitis may also be implicated with A. actinomycetemcomitans, Peptostreptococcus micros, Prevotella intermedia, F. nucleam, Capno- cytophaga spp and Veillonella.<sup>15</sup> White et al. in his study concluded that the initiation of periodontitis begins first in the third molar region based on clinical and microbiological findings. The bacteria involved most often exist in complexes, particularly Treponema denticola, Porphyromonas gingivalis, and Bacteroides forsythus.<sup>15</sup>

### 4. Treatment

The treatment for the present case would be surgical extraction of third molar, incision and drainage of abscess under antibiotic coverage. Antibiotics to be given by culture and sensitivity. Multidrug resistance bacteria are usually involved in such cases.

### 5. Conclusion

In the present case, there was no pain associated with the or trismus which usually happens with impacted molars, but there was on and off swelling, and hence there was an enigma in diagnosis. The patient took antibiotics whenever he developed swelling and hence it masked the actual cause and made it difficult to rule out the foci of infection.

## 6. Source of Funding

None.

## 7. Conflict of Interest

None.

## References

1. Santosh P. Impacted Mandibular Third Molars: Review of Literature and a Proposal of a Combined Clinical and Radiological Classification. *Ann Med Health Sci Res.* 2015;5(4):229–34.
2. Azaz B, Shteyer A, Piamenta M. Radiographic and clinical manifestations of the impacted mandibular third molar. *Int J Oral Surg.* 1976;5(4):153–60.
3. Bataineh AB, Albashaireh ZS, Hazza'a AM. The surgical removal of mandibular third molars: a study in decision making. *Quintessence Int.* 2002;33(8):613–7.
4. Kim JY, Jee HG, Song HC, Kim SJ, Kim MR. Clinical and pathologic features related to the impacted third molars in patients of different ages: A retrospective study in the Korean population. *J Dent Sci.* 2017;12(4):354–9.
5. Mettes TD, Ghaemina H, Nienhuijs ME, Perry J, Sanden WJW, Plasschaert A, et al. Surgical removal versus retention for the management of asymptomatic impacted wisdom teeth. *Cochrane Database Syst Rev.* 2012;13(6):CD003879.
6. Chuang SK, Perrott DH, Susarla SM, Dodson SM. Age as a risk factor for third molar surgery complications. *J Oral Maxillofac Surg.* 2007;65(9):1685–92.
7. Mercier P, Precious D. Risks and benefits of removal of impacted third molars. A critical review of the literature. *Int J Oral Maxillofac Surg.* 1992;21(1):17–27.
8. Flick WG. The third molar controversy: framing the controversy as a public health policy issue. *J Oral Maxillofac Surg.* 1999;57(4):438–44.
9. White RP, Phillips C, Hull DJ, Offenbacher S, Blakey GH, Haug RM. Risk markers for periodontal pathology over time in the molar and non-third molar regions in young adults. *J Oral Maxillofac Surg.* 2008;66(4):749–54.
10. Indresano AT, Haug RH, Hoffman MJ. The third molar as a cause of deep space infections. *J Oral Maxillofac Surg.* 1992;50(1):33–5.
11. Ohshima A, Arijji Y, Goto M, Izumi M, Naitoh M, Kurita K, et al. Anatomical considerations for the spread of odontogenic infection originating from the pericoronitis of impacted mandibular third molar: Computed tomographic analyses. *Oral Surg Oral Med Oral Pathol Oral Radiol Endod.* 2004;98(5):589–97.
12. Goyal S, Verma P, Raj S. Radiographic Evaluation of the Status of Third Molars in Sriganagar Population - A Digital Panoramic Study. *Malays J Med Sci.* 2016;23(6):103–12.
13. Clark C. A method of ascertaining the relative position of unerupted teeth by means of film radiographs. *Proc Royal Soc Med.* 1910;3:87–90.
14. Richards AG. A technic for the roentgenographic examination of impacted mandibular third molars. *J Oral Surg (Chic).* 1952;10(2):138–41.
15. Trummel C, Behnia A. Periodontal and pulpal infections. In: Topazian RG, Goldberg MH, Hupp JR, editors. *Oral and Maxillofacial Infections*. Philadelphia, PA: WB Saunders; 2002. p. 142–6.

## Author biography

**Humera Ayesha**, Reader  <https://orcid.org/0000-0002-1637-4926>

**Cite this article:** Ayesha H. Impacted mandibular 3<sup>rd</sup> molar- An enigma in diagnosis. *J Oral Med, Oral Surg, Oral Pathol, Oral Radiol* 2024;10(2):130-133.