

“Medication Related Osteonecrosis of the Jaw (MRONJ)- case report and review of literature”

Umme Amarah^{1,*}, Laxmikanth Chatra², Prashanth Shenai K³, Veena KM⁴, Rachana V Prabhu⁵

¹PG Student, ^{2,3}Senior Professor, ⁴Professor, ⁵Reader, Dept. of Oral Medicine & Radiology, Yenepoya Dental College, Mangalore

***Corresponding Author:**

Email: drummeamarah@yahoo.in

Abstract

Osteonecrosis is considered to be one of the side effects of the bisphosphonate therapy. It occurs due to the over suppression of bone turnover rate. Trauma, tooth extractions, and poor oral hygiene is also considered to be risk factors for MRONJ. Increasing number of patients with oral bisphosphonates will be reporting to dentist for oral health care, it's important for all general dental practitioners to be aware of the potential complications.

Keywords: Bisphosphonates, Bisphosphonate- related osteonecrosis of jaw, Extraction, Osteoporosis, and Osteonecrosis.

| Access this article online | |
|---|---|
| Quick Response Code: | Website: www.innovativepublication.com |
|  | DOI: 10.5958/2395-6194.2016.00027.8 |

Introduction

Medication related osteonecrosis of the jaw (MRONJ) adversely affects the quality of life, producing significant morbidity. The Intravenous (IV) bisphosphonates (BPs), Oral bisphosphonates, RANK ligand inhibitor (denosumab) and Antiangiogenic medications are the leading risk factors for the development of MRONJ. Bisphosphonates (BPs) are used in treatment of osteoporosis, Paget disease of bone, Heterotopic ossification, hypercalcemia, multiple myeloma, and skeletal events associated with metastatic neoplasms¹. Most of the patients having osteoporosis are prescribed bisphosphonates orally as well as intravenously, however mostly as low dose oral therapy. Osteonecrosis of the jaw develops in the patients who are on an average taking oral bisphosphonates for about 4.6 years (and also for a minimum of 3 years)². These drugs are completely resistant to the hydrolytic cleavage, and re the reason why they accumulate in the bone tissue and have a long half-life. The accumulation of bisphosphonates in the bone, in particular in maxillary bones, is not reversible. Their toxic effect on osteoclasts depends on both the dose administered and the duration of therapy. Bisphosphonates bind to osteoclasts and accumulate at sites of high bone turnover. As a result, their concentration is higher in the jaw. There is also some supporting evidence and also some theories suggesting that, the necrosis is caused due to the inhibition of bone remodeling secondary to the suppression of bone

resorption³⁻⁶. In bisphosphonate-related osteonecrosis of jaw (BRONJ) exposure of bone with pain will be present in the mandible and maxilla of patients receiving the bisphosphonates. Previously bisphosphonates induced osteonecrosis was called as BRONJ, bisphosphonate-associated ONJ, bisphosphonate-induced ONJ, drug-induced ONJ osteochemonecrosis, avascular necrosis of the jaws. Now, the special committee of the American Association of Oral and Maxillofacial Surgeons recommends changing the nomenclature of bisphosphonate-related osteonecrosis of the jaw (BRONJ) to medication-related osteonecrosis of the jaw (MRONJ). The estimated range for developing ONJ after tooth extraction exposed to intravenous BPs is 1.6 to 14.8%⁷. The working definition of MRONJ according to the 2014 AAOMS Position Paper, patients may be considered to have MRONJ if all of the following characteristics are present: Current or previous treatment with antiresorptive or antiangiogenic agents; Exposed bone or bone that can be probed through an extra oral or intraoral fistula(e) in the maxillofacial region that has persisted for more than eight weeks; and No history of radiation therapy to the jaws or obvious metastatic disease to the jaws⁸. This article enlightens on etiology and current terminologies of osteonecrosis induced due to bisphosphonates.

Case Report

A 68 yr old female patient reported with a complaint of pain and swelling in the right mandibular area. The swelling was of 4 days duration and associated with severe pain. Patient gives a history of extraction 2 months back of the right mandibular molar.

Pain aggravates on chewing of food and during sleep, associated with tingling sensation in the chin area (mild intensity). Patient gives a history of extraction 2 months back of the right mandibular molar.

Patient does not give history of any considerable changes in the size of the swelling; the size has remained constant since it has occurred. Medical history revealed that patient was under treatment for hypertension and asthma since 12 yr and also for osteoporosis -Ibandronic acid since 6 yr. (tab calinta once daily).

On clinical examination diffuse swelling seen on the right side of the mandible extending anterioposteriorly about 1.5 cm away from the corner of the mouth and 4cm away from the lobule of the ear and extending superoinferiorly about 1 cm above the lower border of the mandible to about 2 cm below the lower border of the mandible. Overlying skin of the swelling appears unstretched, no discoloration of the skin noticed. No pus discharge, draining sinus or surface ulceration seen. Swelling was hard in consistency also associated with severe tenderness present on palpation. Bilateral submandibular lymphnodes were palpable and nontender.

Intraorally, exposed bone covered yellow slough on the edentulous area i.r.t 47 with obliteration of the buccal vestibule, overlying mucosa is erythematous .Severe tenderness on palpation of the right buccal vestibule in the swelling area.

Intraoral clinical examination revealed surface ulceration with alveolar bone exposure on the alveolar ridge bilaterally (Fig. 1A-C).The patient had poor oral hygiene.

Cone beam computed tomography views demonstrated the exact extent of the lesion, in right side of the mandible A saucer shaped ill-defined non corticated radiolucency seen at the molar area extending from 2mm anterior to the anterior border of ramus extends anteriorly about 1.4 cm though the edentulous arch measuring around 14 X 13 mm size, bucco lingual cortical plate expansion also seen with resorption of lingual cortical plate and remnants of trabeculae seen within the radiolucency, which is adjacent to the inferior alveolar nerve. In left side of the mandible Well defined radiolucency intermixed with radiopaque areas seen at the root apex of 34,35,36 extending from mesial aspect of 34 to mesial aspect of 37, measuring around 26X20 mm size, surrounding bone shows increased radiodensity. The lesion is approximating the mandibular canal, and Bucco lingual cortical plate expansion also seen (Fig. 2, 3).

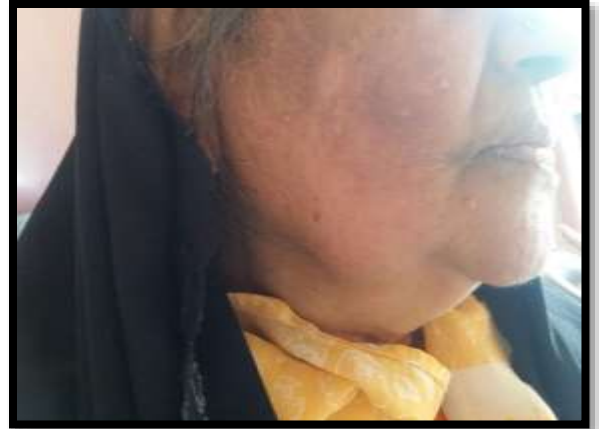

Fig. 1 a: Swelling seen on the right lower jaw

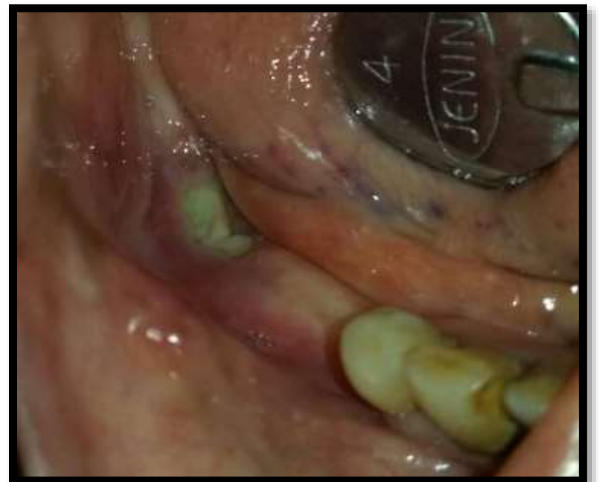

Fig. 1 b: Lesions from bisphosphonate-related osteonecrosis of the jaw at extraction site of lower right 2nd molar (tooth no. 47)

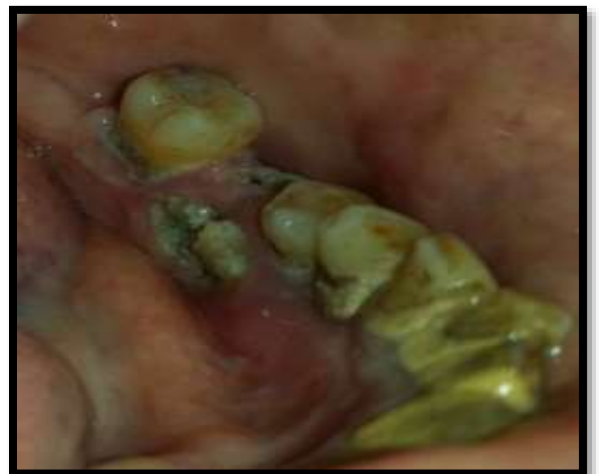

Fig. 1c: Bisphosphonate-related osteonecrosis of the jaw at the site of tooth #36. Necrotic, non-healing exposed bone extends up the tooth no #37

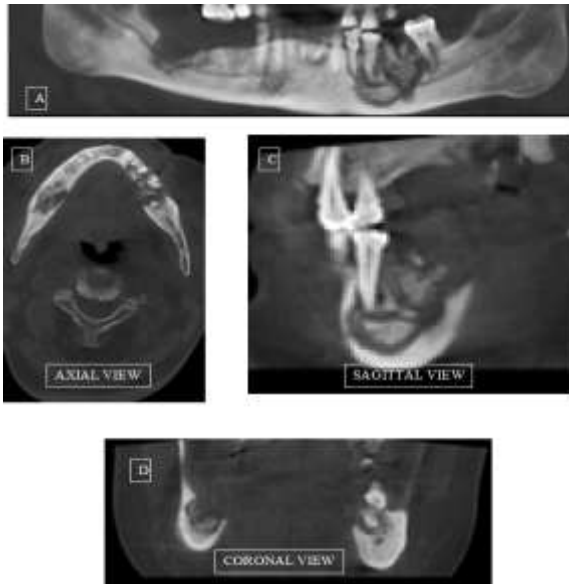


Fig. 2: Axial, Sagittal, and Coronal sections(A-D) of CBCT showing sequestrum and radiolucency

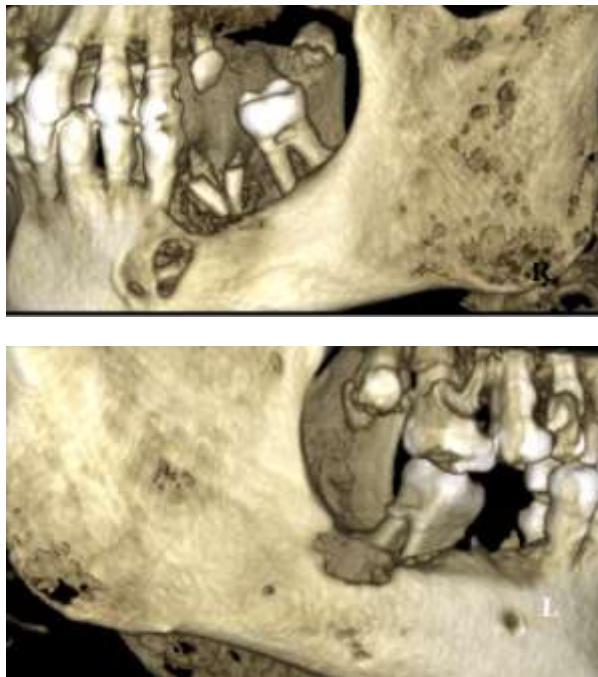


Fig. 3: The 3D reconstruction visualizing the lesion in three dimensions showing sequestrum on right side of mandible & left side of mandible showing lesion involving increased radiodensity, the lesion is approximating the mandibular canal, and Bucco lingual cortical plate expansion also seen

Discussion

Bisphosphonates are potent inhibitors of bone resorption, often prescribed as a first-line therapy for postmenopausal osteoporosis. Bisphosphonates have long-term retention in the bone and the persistence of their effect after cessation of therapy when compared to all the other pharmacological inhibitors of bone

resorption. Half-life of bisphosphonates is more than 10 years¹⁰. Our patient had been taking ibandronic acid 150 mg(CALINTA KIT) therapy for 6 years. The osteoclastic function is part of the cycle of bone turnover. Bisphosphonates inhibit the differentiation of osteoclastic precursors, cause osteoclast apoptosis and stimulate the release of osteoclastic inhibitory factor from osteoblasts¹⁰. Osteoclastic function is severely impaired, hence the dead and dying osteocytes will not be replaced, and the capillary network will not be maintained in the bone, causing avascular necrosis of bone¹¹. For patients receiving oral bisphosphonate therapy to manage osteoporosis, the prevalence of ONJ increases over time from near 0 at baseline to 0.21% after four or more years of BP exposure. The median duration of BP exposure for patients with ONJ and ONJ-like features was 4.4 years. For patients without ONJ, the median exposure to oral BPs was 3.5 years¹²⁻¹³. In a case-control study among cancer patients exposed to zoledronate, tooth extraction was associated with a 16-fold increased risk for ONJ when compared to cancer patients without ONJ (odds ratio[OR] = 16.4; 95% confidence interval [CI], 3.4 – 79.6)¹⁴. Our patient had lesions on right and left side of the mandible, which was also reported by authors as there may be one or more sites of bone exposure¹⁵. The patient had undergone extraction, and developed symptoms preceding to this and also had similar exposure of the bone on the left side which was asymptomatic. The osteonecrotic sites may remain asymptomatic for prolonged periods of time (weeks, months or even years), or clinical signs and symptoms may manifest before clinically detectable ONJ develops. Such signs and symptoms consist of pain, bone and/or gingival swelling, erythema, suppuration, soft tissue ulceration, intra- or extraoral fistular trajectories, tooth mobility, paresthesia and even anesthesia, in the absence of any apparent dental/periodontal cause¹⁶. Majority of patients (69%) had undergone extraction of teeth before the development of osteonecrosis. This seems to confirm the importance of this type of trauma in causing the complication¹⁷, and can be explained by the fact that when local defenses are overwhelmed by infection, trauma or surgery, diverse microorganisms may invade the bone marrow. Additionally, the inhibition of angiogenesis can aggravate this process by compromising the vascular supply through tissue cicatrisation.

Conclusion

In this case report on right side of the mandible the MRONJ followed by extraction of teeth and on left side the MRONJ could have been due to poor oral hygiene status of the patient. Hence it's very important for the patient on bisphosphonate therapy to maintain oral hygiene and also to have a regular follow up with the dentist.

References

1. Woo S-B, Hellstein JW, Kalmar JR. Narrative [corrected] review: bisphosphonates and osteonecrosis of the jaws. *Ann Intern Med.* 2006 May 16;144(10):753–61.
2. Zavras AI. The impact of bisphosphonates on oral health: lessons from the past and opportunities for the future. *Ann N Y Acad Sci.* 2011 Feb;1218:55–61.
3. Marx RE, Sawatari Y, Fortin M, Broumand V. Bisphosphonate-induced exposed bone (osteonecrosis/osteopetrosis) of the jaws: risk factors, recognition, prevention, and treatment. *J Oral Maxillofac Surg.* 2005 Nov;63(11):1567–75.
4. Marx RE, Cillo JE, Ulloa JJ. Oral bisphosphonate-induced osteonecrosis: risk factors, prediction of risk using serum CTX testing, prevention, and treatment. *J Oral Maxillofac Surg.* 2007 Dec;65(12):2397–410.
5. RANK/RANKL/OPG signaling pathways in necrotic jaw bone from bisphosphonate-treated subjects. - PubMed - NCBI [Internet]. [cited 2016 May 8]. Available from: <http://www.ncbi.nlm.nih.gov/pubmed/25820558>.
6. Hellstein JW, Adler RA, Edwards B, et al. Managing the care of patients receiving antiresorptive therapy for prevention and treatment of osteoporosis: recommendations from the American Dental Association Council on Scientific Affairs. https://www.aae.org/uploadedfiles/publications_and_research/endodontics_colleagues_for_excellence_newsletter/bonj_ada_report.pdf. Accessed April 1, 2016.
7. Yamazaki T, Yamori M, Ishizaki T, Asai K, Goto K, Takahashi K, et al. Increased incidence of osteonecrosis of the jaw after tooth extraction in patients treated with bisphosphonates: a cohort study. *Int J Oral Maxillofac Surg.* 2012 Nov;41(11):1397–403.
8. Ruggiero SL, Dodson TB, Fantasia J, Goodday R, Aghaloo T, Mehrotra B, et al. American Association of Oral and Maxillofacial Surgeons position paper on medication-related osteonecrosis of the jaw--2014 update. *J Oral Maxillofac Surg.* 2014 Oct;72(10):1938–56.
9. Black DM, Schwartz AV, Ensrud KE, Cauley JA, Levis S, Quandt SA, et al. Effects of continuing or stopping alendronate after 5 years of treatment: the Fracture Intervention Trial Long-term Extension (FLEX): a randomized trial. *JAMA.* 2006 Dec 27;296(24):2927–38.
10. Rogers MJ, Gordon S, Benford HL, Coxon FP, Luckman SP, Monkkonen J, et al. Cellular and molecular mechanisms of action of bisphosphonates. *Cancer.* 2000 Jun 15;88(12 Suppl):2961–78.
11. Carter G, Goss AN, Doecker C. Bisphosphonates and avascular necrosis of the jaw: a possible association. *Med J Aust.* 2005 Apr 18;182(8):413–5.
12. Background Document for Meeting of Advisory Committee for Reproductive Health Drugs and Drug Safety and Risk Management Advisory Committee. United States. Food and Drug Administration. September 9, 2011; <http://www.fda.gov/downloads/AdvisoryCommittees/CommitteesMeetingMaterials/drugs/DgSafetyandRiskManagementAdvisoryCommittee/ucm270958.pdf> Accessed April 1, 2016.
13. Lo JC, O’Ryan FS, Gordon NP, Yang J, Hui RL, Martin D, et al. Prevalence of osteonecrosis of the jaw in patients with oral bisphosphonate exposure. *J Oral Maxillofac Surg.* 2010 Feb;68(2):243–53.
14. Fehm T, Beck V, Banys M, Lipp HP, Hairass M, Reinert S, et al. Bisphosphonate-induced osteonecrosis of the jaw (ONJ): Incidence and risk factors in patients with breast cancer and gynecological malignancies. *Gynecol Oncol.* 2009 Mar;112(3):605–9.
15. Margaix-Muñoz M, Bagan J, Poveda-Roda R. Intravenous bisphosphonate-related osteonecrosis of the jaws: influence of coadjuvant antineoplastic treatment and study of buccodental condition. *Med Oral Patol Oral Cir Bucal.* 2013 Mar;18(2):e194-200.
16. Gavalda C, Bagán J-V. Concept, diagnosis and classification of bisphosphonate-associated osteonecrosis of the jaws. A review of the literature. *Med Oral Patol Oral Cir Bucal.* 2016;21(3):e260-270.
17. Van den Wyngaert T, Huizing MT, Vermorcken JB. Bisphosphonates and osteonecrosis of the jaw: cause and effect or a post hoc fallacy? *Ann Oncol.* 2006 Aug;17(8):1197–204.
18. Migliorati CA, Schubert MM, Peterson DE, Seneda LM. Bisphosphonate-associated osteonecrosis of mandibular and maxillary bone: an emerging oral complication of supportive cancer therapy. *Cancer.* 2005 Jul 1;104(1):83–93.