

Simple bone cyst- case report with 6 month follow up

Suresh Manshomal Ludhwani¹, Sonal Bhavin Dudhia², Alauki Anil Shah^{3,*}¹Senior Lecturer, ²HOD, ³PG Student, College of Dental Sciences & Research, Bopal, Ahmedabad***Corresponding Author:**

Email: alauki@innovatedental.com

Abstract**Keywords:** Pseudocyst, Traumatic, Hemaorrhage

Access this article online	
Quick Response Code:	Website: www.innovativepublication.com
	DOI: 10.5958/2395-6194.2016.00029.1

Introduction

The simple bone cyst (SBC) is an uncommon benign empty or fluid containing cavity within, bone that is not lined by epithelium.¹ IN 1929, Lucas and Blum for the first time described traumatic bone cyst (TBC) as a separate disease entity.^{2,3,4,5,6} This lesion in the literature is mention under variety of names: solitary bone cyst^{4,5,6,7}, Hemorrhagic bone cyst^{3,4,5,6,8,9}, unicameral⁹, progressive bone cyst⁴ and simple bone cyst^{3,4,5,6,8,9}. Since 1992, WHO proposed the term "solitary bone cyst" for this lesion but simple bone cyst is term most frequently used fir documentation.^{1,3}

The etiopathogenesis of SBC is still unknown.^{5,6,10} Cohen proposed that the cyst develops because of a lack of collateral lymphatic drainage of venous sinusoids. This apparent blockage then result in the entrapment of interstitial fluid causing resorption of the bony trabeculae and cyst development. Mirra et al. proposed that SBCs are synovial cysts, developing as a result of a developmental anomaly whereby synovial tissue is incorporated intraosseously. A predisposing idiosyncratic factor in the pathogenesis of SBC was also suggested, such as a peculiarity of the vessel wall or an abnormal coagulation of the blood.^{5,7}

Other hypothese is proposed for the evolution of SBC include; bone tumor degeneration^{5,6,8}, altered calcium metabolism⁶, low-grade infetion^{2,8}, local alteration in bone growth, increased osteolysis intramedullary bleeding local ischemia⁸ or a combination of such factors. Alternatively, Kuhmichel and Bouloux proposed that SBCs appear to be developmental in nature. However, among the myriad of these proposed hypotheses, there are only 3 that predominate: a degenerative tumoral process, an abnormally of osseous growth and a particular factor triggering hemorrhagic trauma.⁷

Simple bone cysts have been reported in almost all bones of the body, notably long bones such as the humerus and femur. This rare pathology accounts for only 1% of maxillofacial cysts and tumors.⁸ These cysts more frequently affect patient between 10 and 20 years of age. The prevalence of simple bone cysts is higher among men than women, with a male: female ratio of about 3:2. Among the facial bones, involvement of the maxilla is rare with simple bone cysts being more commonly found in the posterior portion (area of the molars) of the mandible. The second most common site is the mandibular symphysis.⁴ There are report of simple bone cysts at unusual sites such as the condylar and coronoid processes and zygomatic arc.^{1,3}

Clinically, the lesion is asymptomatic in the majority of cases and is often accidentally discovered on routine radiological examination. About 20% patient having painless swelling.¹ Pain is the presenting symptom in 10% to 30% of the patients.^{2,5} Other more unusual symptom include tooth sensitivity, paresthesia, fistulas, delayed eruption of permanent teeth, displacement of the inferior dental canal and pathologic fracture of the mandible.^{1,2,5,7} Expansion of the cortical plate of the jaw bone is often noted,^{1,7} usually buccally, resulting in intraoral and extraoral swelling and seldom causing deformity of the face. The adjustments to the lesion teeth are usually vital and there is no mobility, displacement or resorption of their roots.^{4,5}

Radiographically, most lesion appear as a well-defined radiolucent defect.² Simple bone cysts rang in diameter from 1 to 10 cm.⁹ Margins with good definition in contrast to area with less precise limits might be observed in the same lesion. Cysts may become radiopaque over time, an event corresponding to new bone formation. This alteration has not been observed in young individuals since it is a late finding during the healing process of the projection resembling upward bent between the dental roots. This feature is highly suggestive of a simple bone cyst. Although this is not a characteristic of these lesions, simple bone cysts may occasionally appear as a multilocular radiotransparency associated with cortical expansion and tumefaction of slow growth.³

The histopathological evaluation reveals a vascular connective tissue or a thick myxofibromatous proliferation inter-mixed normal bone. There is no

epithelial lining.^{7,9} In some areas erythrocytes, occasional giant cells are evident.¹

The definite diagnosis of SBC is invariably at surgery when an empty bone cavity without epithelial lining is observed. Sometimes, the cavity contains a straw-colored fluid or bright blood. Surgery is the management of choice, particularly as it also leads to confirmation of the diagnosis. Simple curettage of the bone walls is performed and it typically heals in 6 to 12 months. Clinical and radiological follow-up after surgery is thus indicated.²

The present case reports describe the clinical and radiographic characteristics as well as the surgical and histopathological finding of SBC.

Case Presentation

A 13 year old female patient reported to department of Oral medicine and radiology with a chief complaint of malaligned teeth. There was no relevant medical, surgical or dental history. On intraoral examination crowding in lower anteriors was evident with no swelling. Patient was advised panoramic radiograph and lateral cephalogram for soft tissue and osseous analysis as a part of orthodontic treatment. (Fig. 1)

On panoramic radiograph, a single well defined unilocular radiolucent lesion of about 21.4*13.3mm in size was present in relation to 35 to 37 regions with scalloped and non-corticated border. Lesion was extending antero-posteriorly from apical region of 35 till mesial surface of 37 and superior-inferiorly it extends from 3mm below the alveolar crest in interdental region of 35 & 36 till lower border of mandible. Internal structure was completely radiolucent with no residual septas present. The margins were well defined with dome like scalloping between the roots and lower border of mandible. There was no root resorption present in associated teeth. There was slight downward displacement of mandibular canal. Differential diagnosis of simple bone cyst and canal giant cell lesion was considered. Tooth vitality test was carried out and all teeth were vital. Patient was informed about the pathology and its potential complications. As patient was reluctant for further investigation and treatment of lesion, she was referred to department of Orthodontics for treatment of malaligned teeth. (Fig. 2)

Orthodontic treatment was carried under concern of patient. After 8 month patient was again referred to department of Oral medicine and radiology for mid-treatment radiograph. Again on clinical examination, there were no significant findings. On panoramic radiograph, increase in size (21.5*14.1) of the lesion was very well appreciated. There was increase in scalloping at the lower border of mandible and also mandibular canal was displaced more downward. Patient was informed about the progression of the lesion and was again advised further investigations.

(Fig. 3) IOPA of 35, 36 & 37 region was carried out. A single well defined radiolucent lesion was present extending from 35 to 37 regions. Internal structure showed no septas and no root resorption. (Fig. 4) Mandibular cross-sectional occlusal radiograph was advised to determine any bucco-lingual expansion; it showed expansion with radiolucency left side extending from 35 to mesial surface of 37. (Fig. 5)

Sectional CBCT was carried out in 11*5 field of view (FOV) in Giano, NEWTOM CBCT. In CBCT a single lytic lesion was observed extending from distal surface of 35 to mesial 37 anteroposteriorly, from buccal cortical plate to lingual cortical plate bucolingually and from interdental area of 35, 36, & 37 to lower border of mandible supero- inferiorly as seen in multiplanner information images

The maximum dimensions of the lesion was 22.4mm anteroposteriorly, 10.4mm buccolingually and 15.6 superinferiorly as seen in axial and cross sectional images of CBCT.(Fig. 6)

The lesion was irregular and uncorticated but well-defined and showing scalloping between roots of 35, 36 & 37 upto the mid root level. There was thinning of outer and inner cortical plates of mandible with 2-3 perforations in buccal plate were appreciated in body of mandible in 36 region 1.5cm below alveolar crest and 1 cm behind the foramen in 3D reconstructed CBCT image Perforation of buccal cortical plate was also seen in cross section images (Fig. 7)

Considering all the clinical and radiographic feature, diagnosis of simple bone cyst was made. Patient was explained about the expansile nature of lesion and was referred to oral surgery department for treatment. On surgical exploration raising a flap under local anesthesia, complete empty cavity apart from an extremely thin layer of connective tissue in some places was found. (Fig. 8) The cavity was curetted and tissue obtained submitted for histopathological examination. Histological examination revealed extravasated RBCs and inflammatory cells. In some areas loosely arranged connectives tissue and mature bone was found. (Fig. 9) Final diagnosis of traumatic bone cyst was confirmed.

6 month follow up was carried out. Panaromic radiograph was carried out. Hazy radio opacity was seen within the pathology site suggestive of bone formation.(Fig. 10)



Fig. 1: Showing the profile view of patient with no significant findings

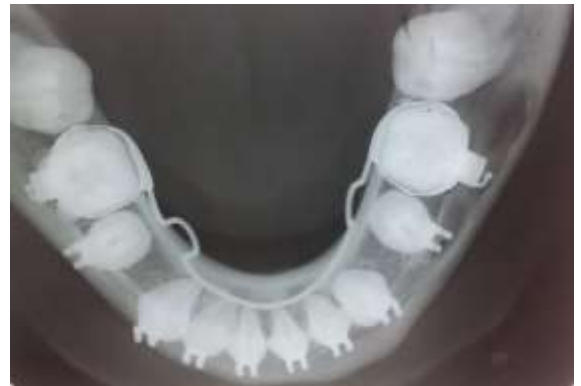

Fig. 5: Shows occlusal radiograph

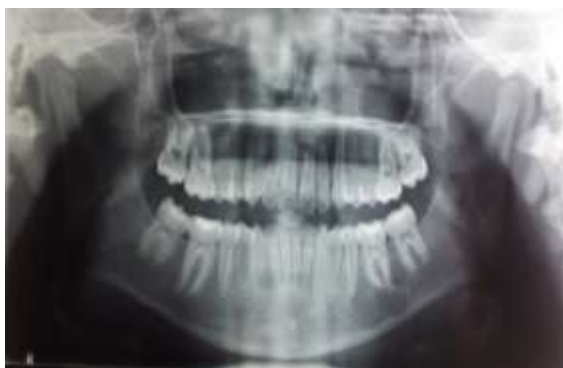

Fig. 2: Shows post-operative OPG with incidental finding

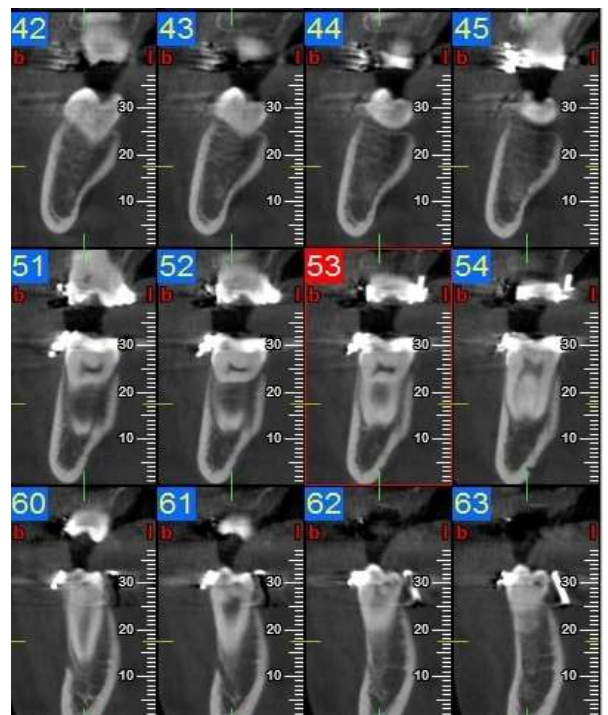


Fig. 6: Showing the bilateral comparison of cbct of left & right side of molar region

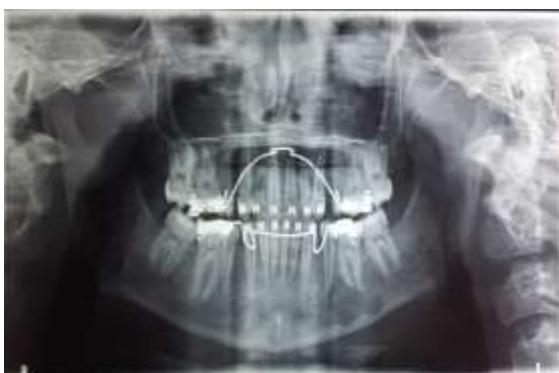

Fig. 3: Shows OPG after 6 months

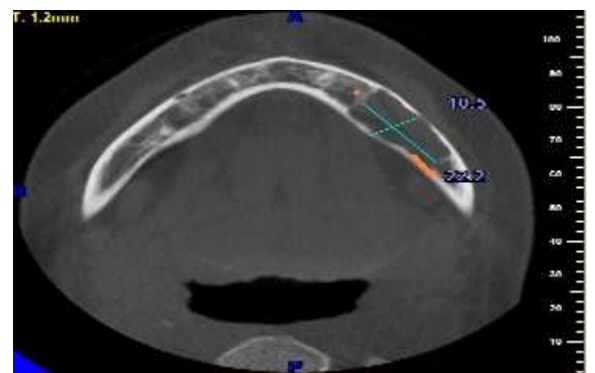


Fig. 7: Shows axial section with well-defined radiolucency approx. 22.2*10.5mm in size with thinning of buccal & lingual wall

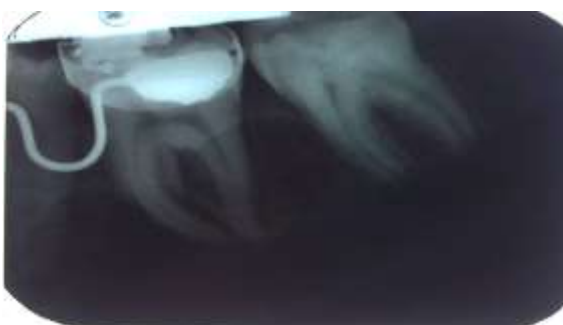

Fig. 4: Shows intra-oral periapical radiograph showing well defined radiolucency extending

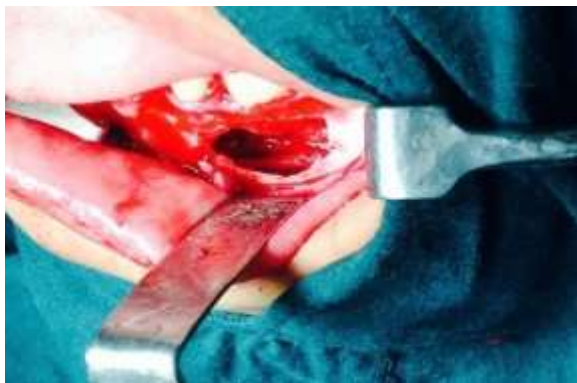

Fig. 8: Show empty cavity after surgical exposure of pathology site

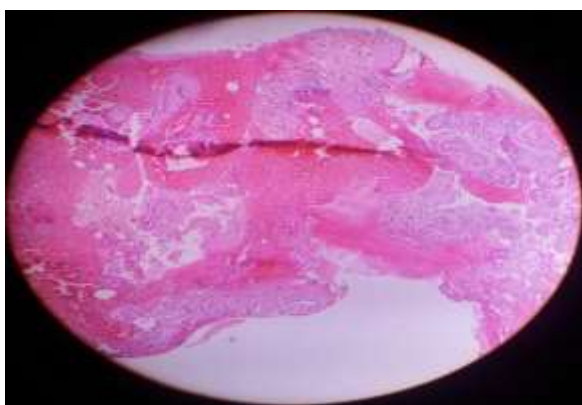

Fig. 9: Show H & E stain (10X)

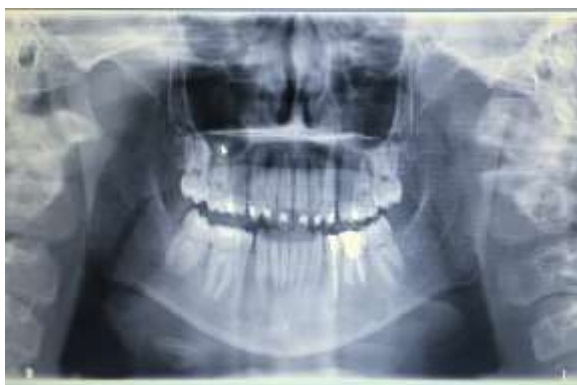

Fig. 10: Shows OPG after 6months follow up post-surgery

Discussion

The SBC was first described by Lucas in 1929. It is classified as an intra-osseous pseudocyst due to lack of an epithelial lining.^{8,10} It is a benign lesion comprising an empty or semi-empty cavity within the bone.¹²

alteration of bone metabolism, low grade infection intraosseous vascular abnormalities and degeneration of bone trumas.⁸ Trauma is the most frequently discussed etiologic factor in the formation of a simple bone cyst.⁴ However, no such association was observed in the preset case.

The age of occurrences is usually the second and third decade of life with slight male preponderance.^{3,5} Though it is more seen in males but few authors suggest it has equal sex distribution. In our case patient was 13 years old female.

As the literature depicts that in most cases, SBC is asymptomatic and found on accidental finding on radiological evaluation.^{2,3} Our case is in coherent with these authors.

Most investigators characterize SBC as apredominantly round or oval well delineated radiolucency with regular or irregular margins but well defined by a delicate corticated layer.³ Maria et al categorized the radiographic morphology of simple bone cyst into 4 categories cone (64%), Oval (16%) and round (4%).¹¹ They concluded that the majority of large lesion (>3cm) were cone shaped, smaller lesion were irregular and avoid shaped. The lesion may extend between the roots of the erupted teeth.^{3,5}

In present case, size of lesion was less than 3 cm and it irregular in shape which was similar to finding of Maria et al. Bony septa may be present in Simple bone cyst, giving the lesion a multi locular appearance on 2-dimensional imaging. Presence of true interlesional septa should be evaluated cautiously, because fin-like extension of wall give the appearance of septa (multilocular appearance), thus leading to erroneous diagnosis.¹³

CBCT is a useful tool for diagnosing & assessing cyst.¹⁰ Three dimensional images provide a detailed representation of cyst in bone tissue and the involvement of surrounding structures such as teeth and nerves. Marcus et al in their study found CBCT was found to be superior to conventional CT in detecting cortical bone involvement and delineating the mandibular canal.¹³ In our case the perforation on buccal plate which is not a common finding of SBC were visualized only with help of CBCT. However, radiological findings are not definitive diagnosis with the need to combine the analysis of clinical feature radiological features, surgical exploration and histological features.

The most commonly recommended treatment of SBC is surgical exploration of lesion followed by curettage of bony walls. The surgical exploration serves as both diagnostic and definitive therapy by producing bleeding in the cavity. This bleeding helps to form a clot which is eventually replaced by bone.² Histopathological findings in SBC are nonspecific and reveal fibrous connective tissue and normal bone with no evidence of any epithelial lining.^{1,2} In our patient, similar findings were observed after surgical exploration and curettage. However SBC heals spontaneously without any intervention. This is probably the reason why they are rarely found in older age group.⁶

Although observed in some cases, recurrence of SBC is highly uncommon and the prognosis is therefore

excellent. In most cases, recurrences is confirmed within 3 years after surgery & follow up at 1-2 years is sufficient in view of the slow growth of recurrent lesion.³

Conclusion

The simple bone cysts (SBC) constitute a causal finding and its aetiology is still unknown. Though simple in their manifestation and extremely good prognosis, SBC is still from a group of lesion which may exhibit challenge in diagnosis. So a definite approach which includes a combine analysis of clinical history, radiological imaging surgical intervention and histopathological results will yield an accurate diagnosis. However never imagining modalities like CBCT explore lesions in all three dimensions and give additional information which is beyond the scope of routine radiographs.

References

1. Mohhammad Abidulla. Traumatic bone cyst: A case report with review of literature. *Unique journal of medical and dental sciences* 2014;2(3):151-153.
2. Sandhiyan P. Joseph TI, Jacob G. Traumatic Bone cyst of the Jaws: A report of Two Cases and Review. *Oral Maxillofacial Pathol J* 2015;6(1):589-593.
3. Sanyura Lopes Dias. Simple Bone cyst: a case report and review of literature. *J health SCI Inst.* 2012;30(3)295-8.
4. Arsinoi A Xanthinaki. Traumatic bone cyst of mandible of possible iatrogenic origin: a Case report and brief review of the literature. *Head & Face Medicine* 2006;2(4):1-5.
5. Birkan Taha. Traumatic bone cyst of the anterior maxilla. *Int J Dent Case Report* 2011;1(1):41-46.
6. Sebstersn Sandev. Traumatic Bone cyst. *Acta Stomatol Croat* 2001;35(30):417-420.
7. Salem AS, Abdelfadil. The Traumatic Etiology Hypothesis of Traumatic Bone Cyst Overview and Report of case. *Oral Hyg Health* 2013;1(1):1-3.
8. Vidya Ajila. Unusual presentation of solitary bone cyst-A case report. *Nuhs* 2014;4(1):135-137.
9. Reji Methew. Unusual cone-bean computerized tomography presentation of traumatic (simple) bone cyst: case report and radiographic analysis. *OOO* 2012;113(3):410-413.
10. Sima Nikneshan. Unusual Aggressive Radiographic appearance of simple bone cyst (A case report and review of literature). *British journal of medicine and medical research* 2015;6(8):833-840.
11. Maria A. Copete. Solitary bone cyst of jaws. *Oral Surg Oral Med Pathol Oral Radio Endod* 1998;85:221-5.
12. I Velez. The relationship between idiopathic bone cavity and orthodontic tooth movement: analysis of 44 cases. *Dentomaxillofacial Radiology* 2010;39:162-166.
13. Marcus Stoetzer. Advance in assessing the volume of odontogenic cysts and tumors in the mandible: A retrospective clinical trial. *Head & Face medicine* 2013;9(14):1-5.
14. Motta. Traumatic bine cyst-report of a case diagnosed after orthodontic treatment. *Rev. Odonto Cienc., Porto Alegre* 2007; 22(58):377-381.