



Content available at: <https://www.ipinnovative.com/open-access-journals>

Journal of Oral Medicine, Oral Surgery, Oral Pathology and Oral Radiology

Journal homepage: www.joooo.org



Review Article

Impact of restorative dental procedures on periodontal health: A comprehensive review

Ena Sharma^{1*}, Ruhee Sangha¹, Simran Thind¹, Radhika Rayat¹, Sreejit², Riddima Sood¹, Harsimar³

¹Rayat Bahra Dental College and Hospital, Mohali, Punjab, India

²Maharishi Markandeshwar College of Dental Sciences and Research, Mullana, Haryana, India

³Dr. HS Judge Dental College and Hospital, Chandigarh, Punjab, India



ARTICLE INFO

Article history:

Received 08-09-2024

Accepted 19-09-2024

Available online 15-10-2024

Keywords:

Restorative dental

Periodontal health

ABSTRACT

Restorative dental procedures play a crucial role in restoring function and aesthetics to damaged teeth, yet their impact on the periodontium—comprising the gingiva, periodontal ligament, cementum, and alveolar bone—cannot be overlooked. This review aims to explore the relationship between restorative dental treatments and periodontal health, emphasizing the potential risks and considerations involved. Factors such as improper crown placement, overhanging restorations, subgingival margin placement, and inadequate proximal contact can lead to periodontal inflammation, tissue damage, and bone loss. The integration of restorative and periodontal care is essential to ensure long-term success and to prevent adverse outcomes such as gingival recession, periodontal pocket formation, and compromised periodontal support. This review highlights the importance of precise clinical techniques, appropriate material selection, and careful case planning to minimize detrimental effects on the periodontium. Additionally, the role of regular periodontal maintenance and patient education in preserving periodontal health following restorative procedures is underscored. Understanding the delicate interplay between restorative interventions and periodontal health is vital for clinicians to achieve optimal treatment outcomes and maintain the integrity of both the teeth and supporting structures.

This is an Open Access (OA) journal, and articles are distributed under the terms of the [Creative Commons Attribution-NonCommercial-ShareAlike 4.0 License](https://creativecommons.org/licenses/by-nc-sa/4.0/), which allows others to remix, tweak, and build upon the work non-commercially, as long as appropriate credit is given and the new creations are licensed under the identical terms.

For reprints contact: reprint@ipinnovative.com

1. Introduction

The marginal periodontium is where the fields of restorative dentistry and periodontics overlap. This interdependence can be understood only when there is agreement upon what constitutes a healthy marginal periodontium and how a pathologic condition can be prevented. Any restorative dental procedure must be executed carefully, especially in dentitions with pre-existing periodontal disease because these patients often have an exaggerated response to slightest tissue insults. Conversely, close attention should be paid to the response of the periodontium to the irritants

arising from careless techniques, which can initiate or add to existing gingival inflammation. In turn, loss of periodontal support and subsequent tooth loss can result if the condition is not recognized and treated in the early stages.

The dentist performing restorative dentistry should have a thorough understanding of the nature and degree of the response to be expected in the periodontal tissues to the procedures carried out. Diseased pulps and missing tooth structure are replaced routinely with inert materials, but at present no material can substitute for a lost periodontium. Therefore, the total environment, internal and external, of the tooth must be considered as one field of operation.

Properly designed and created dental restorations provide functional stimulation, contribute to and support the

* Corresponding author.

E-mail address: dr.sharma_ena@yahoo.co.in (E. Sharma).

periodontium. Conversely, the healthy periodontium is essential to the proper function of the restoration.¹

2. Physiologic Dimensions of Periodontium–Biologic Width

In 1962, Cohen defined the “biologic width” of supracrestal gingival tissue as those junctional epithelial and connective tissue elements of the dentogingival continuum that occupy the space between the base of the gingival crevice and the alveolar crest.² This term was based on the work of Garguilo et al³ 1961, who described the dimensions and relationship of the dentogingival junction in humans. (Figure 1).

Garguilo et al (1961) reported the following mean dimensions:

1. Sulcus depth of 0.69mm
2. An epithelial attachment of 0.97mm
3. Connective tissue attachment of 1.07mm

Interproximal Biologic Width is similar to that of the facial surface but the total dentogingival complex is different. According to Kois and Spear, the dentogingival complex is 3.0mm facially and 4.5 mm to 5.5 mm interproximally.

The height of interdental papilla was explained by increased scalloping of the bone. Spear suggested that additional 1.5 to 2.5 mm of interproximal gingival tissue height is seen only in the presence of adjacent teeth. In the absence of the adjacent tooth, the interproximal gingival tissue is 3.0 mm. Tarnow and colleagues found that the distance from the contact point to alveolar crest should not exceed 5 mm to 5.5 mm for the gingival tissue to completely fill the interdental space. Greater distance resulted in significant loss of alveolar height. Cho et al also found that the number of papillae that filled the interproximal space also decreased as the interproximal distance between the teeth increased.⁴

According to Schroeder and Listgarten, the continuum between the tooth and the gingiva, the dentogingival junction, represents a “sandwich” of heterogeneous yet intimately connected tissues. (Figure 1) These include the enamel or tooth surface, the dental cuticle, the junctional epithelium, the external basement lamina, and the gingival connective tissue. The actual epithelial attachment to the tooth is affected by hemi desmosomes and the internal basement lamina that adhere to the tooth surface. The floor of the crevice is made up of the superior elements of the junctional epithelium, while the crevicular wall is derived from oral epithelium. The adhesion of the junctional epithelium to the tooth is disrupted easily. When this occurs, the cohesion between the epithelial cells and other tissue layers of the dentogingival unit is weakened, and inflammatory change will ensue, setting the stage for periodontal destruction.⁵

Clinically, disruption of the junctional epithelium can be caused by placement of restoration margins too far apically,

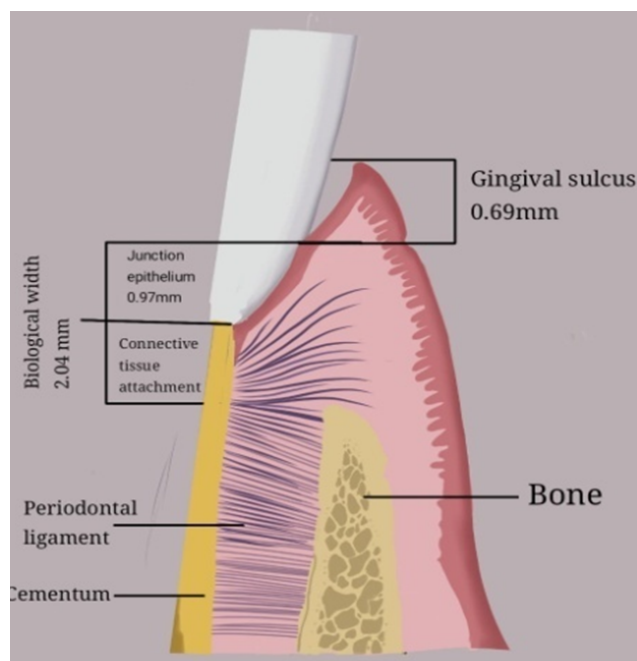


Figure 1: Shows the normal biological width

exaggeration of emergence profiles of restored teeth, and injudicious manipulation of the supracrestal gingival tissue during tooth preparation or the impression making process.⁶

2.1. Application of rubber dam

The rubber dam is used to define the operating field by isolating one or more teeth from the oral environment. It maintains a clear field by managing saliva, controlling muscles, preventing aspiration and infection from caustic agents, thereby saving treatment time.

The rubber dam clamp consists of four prongs and two jaws connected by a bow. The retainer is used to anchor the dam to the most posterior tooth to be isolated. Jaws of the retainer should not extend beyond the mesial and distal line angles or forced subgingivally leading to stripping of the junctional epithelium and gingival connective tissue attachment. If the clamp is placed, either for longer period time or is not punched facial to the arch form in class V lesion, circulation in the interproximal tissue will be diminished causing ischemia, tissue sloughing and subsequent gingival recession.

2.2. Cavity and crown preparation

Preparation instrumentation:

During tooth preparation, the following should be considered in an effort to avoid detrimental effects to the periodontal tissues:

1. Of all the insulting factors resulting from tooth preparation, vibration is the most irritating as it

can lead to laceration, compression, and ischemia of ligament fibres and their blood vessels.

2. Preparation of gingival cavo-surface margins is most effectively and atraumatically accomplished with properly utilized hand instruments. Unfortunately, using rotary instruments in this area will almost invariably result in laceration and bruising of tissue, with healing by secondary intention.
3. Injury to adjacent gingival tissues can usually be avoided if an effort is made to preserve the proximal plate of enamel during gross cavity preparation.
4. Before preparing the proximal portion of any tooth, placement of wedges from the facial and / or lingual, apical to the contact area, will assure protection of the underlying periodontium from the mechanical and physical trauma of instrumentation.

2.2.1. Gingival margin placement

A clinician is presented with three options for margin placement: supragingival, equigingival (even with the tissue), and subgingival. (Figure 2)

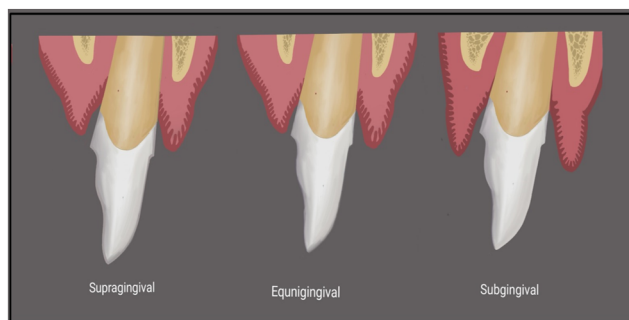


Figure 2: Shows the different type of margins for restorative procedures

2.2.1.1. Supragingival margin. It has the least impact on the periodontium. These margins are easier to clean and to visualize.⁶ Classically, they were used in unaesthetic areas due to traditional restorative materials, but with advent of translucent restorative material, adhesive dentistry and resin cement, these margins can now be used in aesthetic areas

2.2.1.2. Equigingival margins. Traditionally was not desirable because they were thought to retain more plaque than supragingival or subgingival margins and therefore result in greater gingival inflammation. These concerns are not valid today because restorations can be finished easily to provide a smooth, polished interface at the gingival margin.

From a periodontal view point, both supragingival and equigingival margins are well tolerated.

2.2.1.3. Subgingival margins . Black’s theory “extension for prevention” of caries and sensitivity advocates

placing gingival margins subgingivally. He advocated the extension of all smooth surface cavities into the crevicular area, and the facial and lingual margins into the embrasure, where friction of mastication would provide self-cleansing effect. He also stated, “Decay does not occur at margins as long as they are covered by reasonably healthy gum tissue.”⁷ As a result, the recommended position has ranged from just below the gingival crest to halfway into the sulcus, and in some cases, almost to the epithelial attachment.⁷ Now, after more than half a century; this theory has become increasingly regarded as overemphasized. Clinicians believe that extension of the cavity can be a wasteful of healthy tooth structure, and that caries is not prevented by extension. No evidence shows that mastication has effective self-cleansing properties.^{8,9}

Healthy unaltered crevices are quite shallow, especially in the anterior region, which often leads the restorative dentist to encroach into this sub crevicular dimension. To hide the gingival margins, clinicians, often overextend the restorations into the gingival crevice. When restoration margins are placed intracrevicularly, they should be no deeper than 0.5mm and parallel to the gingival margin, in anterior portions of the mouth, it is not uncommon to see the preparation line finish deeper interproximally than it does in the cervical areas. The effects of these injuries may be reversible, but only if tissue is permitted to heal against smooth and acceptable tooth surfaces and not against a restorative material.^{10–12}

2.2.2. Biologic width violation

One possibility is that bone loss of an unpredictable nature along with gingival tissue recession will occur as the body attempts to recreate room between the alveolar bone and the margin to allow space for tissue reattachment. This is more likely to occur in areas where the alveolar bone surrounding the tooth is very thin in width. Trauma from restorative procedures can play a major role in causing this fragile tissue to recede. Orkin et al. (1987) demonstrated that subgingival restorations had a greater chance of bleeding and exhibiting gingival recession than supragingival restorations.¹²

The other response which is the most common finding is persistent chronic inflammation especially in the interproximal areas can be where bone level remains unchanged but gingival inflammation develops and persists. (Figure 3) This would occur when permanent biofilm or a permanent irritant in the junctional epithelium persists and is usually seen in the thick biotype (soft tissue type).

To restore the gingival tissue health, it is necessary to establish space clinically between the alveolar bone and the margin. This can be accomplished either by surgery to alter the bone level or by orthodontic extrusion to move the restorative margin farther away from the bone level.¹³

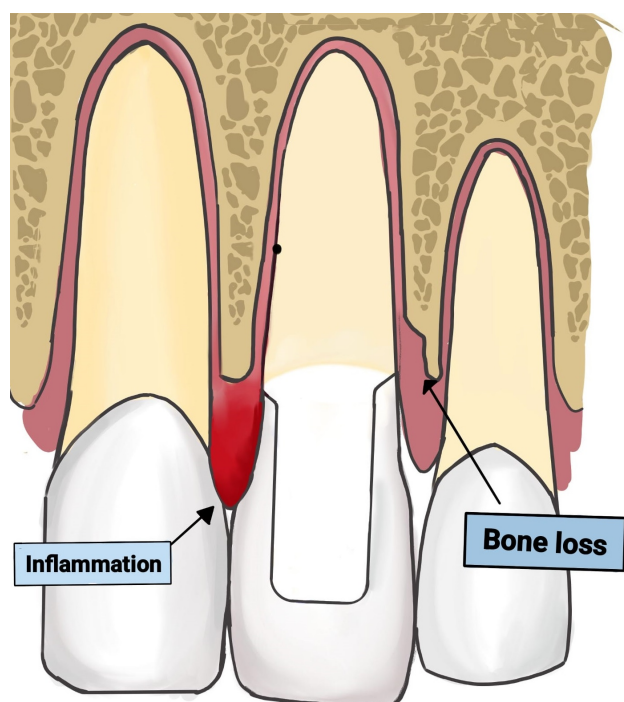


Figure 3: Shows the inflammation and bone loss due to violation of Biological width

2.2.3. Evaluation of biologic width violation

Clinical method: Biologic width violation occurs when margin extends to attachment. It is due to assessment of restoration margin levels with periodontal probe which causes the patient to experience tissue discomfort.

Bone sounding: By probing under local anaesthesia to bone level and subtracting the sulcus depth, biologic width can be identified. If the distance is less than 2mm at more than one location, diagnosis of biologic width violation can be confirmed.

Radiographic evaluation: In the evaluation of biologic width, radiographs are useful, non-invasive tools. Interproximal biologic width violation can be identified by radiographic interpretation. However because of tooth superimposition, radiographs are not diagnostic on mesiolabial and distofacial line angles of teeth. Gouri and Sushama described a new simple, reproducible and innovative method known as parallel profile radiographic (PPR) technique which is used to measure length and thickness of dentogingival unit with accuracy.¹⁴

2.3. Placing the matrix

Matrices for amalgam, direct gold, and direct tooth coloured materials should not only be firm and unyielding, but they must also be biologically acceptable. A matrix band for a typical interproximal cavity preparation is approximately 2mm above the proposed marginal ridge

height and 1mm below the gingival margin. The matrix must be rigid and well contoured both in buccolingual and occlusocervical direction to reproduce proper form and to prevent intracervical overhangs. Improperly contoured interdental restorations like excessively broad contact areas, insufficient or absent interdental contacts, interdental under contour or over contour at the gingival third, and gingival overhangs account for such problems as interdental food impaction and exaggerated accumulation and retention of microbial plaque, which result in recurrent caries and/or periodontal breakdown.

2.4. Gingival retraction^{15–17}

In order to aid in proper cavity preparation, subsequent impression procedures and restoration, soft tissues should be excluded from the operating site. Aim of gingival retraction is to reflect the gingiva and produce enlarged gingival sulcus both in vertical and lateral directions. Lateral displacement of the tissue so that adequate bulk of the impression material can be interfaced with the prepared tooth. Apical/vertical displacement exposes the uncut portion of the tooth apical to the finish line. This ensures best properties of restorative material and longevity of the restoration without adversely affecting the soft tissues.

In 1978, Van der Velden and De Vries¹⁸ studied the forces applied to the sulcus during various dental procedures. They observed a tearing of the epithelial attachment as soon as pressure of 1N/mm² was applied to the marginal gingiva. This attachment was destroyed when the pressure exceeded 2.5N/mm².

Histopathological evaluation of gingival retraction in humans show that gingival retraction with the cord caused destruction of the junctional epithelium, which took about eight days to heal. The disrupted sulcular epithelium and junctional epithelium were sometimes missing. Also the junctional epithelium if present displayed intracellular hydropic degeneration, stripping, and desquamation of epithelium. The average postoperative gingival recession seen with cord retraction was 0.2±0.1 mm.¹⁹

Physico Mechanical Method (such as rubber dam, cotton twills with ZnO cement, copper band impression, temporary acrylic resin copings etc.) acts by physically pushing the gingiva away from finish line.

Trimming and fitting of copper bands must be done with great care because excessive pressure or extension of the band may sever or traumatize the gingival attachment and lead to irreversible gingival recession.

Chemico-mechanical methods chemically impregnated retraction cord comes in different forms; twisted, braided, and knitted and depending on the clinical situation, it may be applied as single- or double-cord technique. A two-cord technique is an effective way of providing gingival retraction. The initial tooth preparation is completed to the

Physio – Mechanical methods		
	Includes	Disadvantage
Copper band	Carry impression material into the gingival crevice. Displace gingival to expose finish line	Injury to the gingival tissue
Retraction Cord	Pack the cord into the gingival sulcus. Made up absorbent material e.g. Cotton	Damage to the tissue.

level of the free gingival margin. These cords impregnated with these agents cause the gingiva to wilt away from the tooth and expose the margin of the preparation. The gingiva ordinarily returns to its proper position, provided it was healthy at the outset and the cord is not permitted to keep the gingiva long enough to permit disease-producing plaque to accumulate in the sulcus. Impregnated cords should not be used on diseased gingiva; pocket walls temporarily retracted from the root return and jeopardize the tooth and restoration. Because the effects of the chemicals cannot be controlled, pressure retraction of the gingiva with chemical free strings or other methods of retraction are preferred.

Retraction Cord: Combines chemical with pressure packing leading to enlargement of gingival sulcus and fluid control from sulcus			
Mechanism of Action	Chemicals used	Ideal Requirements	Contraindications of epinephrine
Vasoconstriction in the gingival tissue	8% racemic epinephrine	Produce gingival displacement and	CVS Disease
Transient shrinkage of gingival tissue	Aluminium chloride Alum	haemostasis. Shouldn't produce irreversible damage to gingiva	Hypertension
	Aluminium sulphate	Not have systemic effects	Diabetes
	Ferric sulphate		Hyperthyroidism
	8% zinc chloride		Known hypersensitivity to epinephrine
	10% tannic acid		
	10% trichloroacetic acid		

2.5. Expasyl

It's consistency is especially formulated to avoid damaging the healthy periodontium, preventing gingival recession and bone resorption. This material depends on the hygroscopic expansion of kaolin that occurs upon contact with the crevicular fluid, combined with the hemostatic activity of aluminium chloride, the resulting gingival displacement occurs in 2–4 min according to the

manufacturer.

Expasyl		
Composition	Advantage	Disadvantage
Kaolin 66.75%	Increases haemostasis	Initial kit cost is expensive 10%
Aluminium chloride 6.54%	Easier to dispense	aluminium chloride is harmful to tissue
15% Water	Saves chair side time	
25.36% Oil of lemon	Decreases incidence of gingival recession	
0.33% Colorant		
1.02%		

Cord (Coltene Whaledent AG, Altstatten, Switzerland) is another material that uses polyvinyl siloxane as an expanding medium in conjunction with the mechanical pressure exerted by Compre-Caps, to achieve gingival retraction. Traxodent Hemodent Paste (Premier Dental Company, Plymouth Meeting, and PA) is also comprised of 15% aluminium chloride topical paste along with cotton caps. In summary, cordless techniques, while causing less discomfort to the patient, are considered less invasive and less time-consuming when compared to conventional retraction cords.

The same is true for the use of the laser for retraction. Diode and ND: YAG laser channels laser through a fiber optic light bundle which incises and cauterizes tissue simultaneously creating haemostasis as well as a retracted field. The present histological findings revealed that with the application of PULSED ND: YAG laser the gingival tissues showed faster healing with less haemorrhage and less inflammatory reaction in comparison with the Ferric sulphate (13.3%).

Therefore, tissue resection has the potential of reducing soft tissue height and causing bone destruction. From a biological point of view, electrosurgical therapy in conjunction with the preparation of abutments before making impressions is not recommended.

A surgical procedure designed to remove tissues in a controlled mode (crown-lengthening procedure) is preferred prior to finalizing the abutment preparation if the height of the clinical crown is not adequate for retention. The gingiva regenerates and is restored to its normal position, provided it was healthy when the preparation was started. If the gingiva is diseased when the tooth is prepared, resection of the gingiva or inadvertent removal of plaque and calculus during tooth preparation results in shrinkage of the pocket wall and leads to exposure of tooth surface beyond the margin of the preparation. The recession is sometimes erroneously attributed to the surgery.²⁰

Whilemsen et al²¹ reported:

1. Cemental destruction with subsequent impaired cementogenesis
2. Lack of epithelial and connective tissue reattachment
3. Significant recession of free gingival margin
4. Apical positioning of sulcular epithelium

Rotary curettage (Gingettage) Portion of the epithelium is removed to expose the finish line

	Disadvantages
Done on healthy gingival	Technique sensitive as poor
Depth of sulcus <3mm	tactile sensitive Potentially
Adequate keratinized gingiva	damaging to periodontium

Electrosurgical retraction (Surgical Diathermy) Surgical reduction of sulcular epithelium using an electrode to produce gingival retraction

Indication	Contraindication	Advantages	Disadvantages
Areas of inflamed gingival	Patients with cardiac pacemakers	Sophisticated technique Used in cases	Technique sensitive Excessive pressure can cause tissue damage
Gingival proliferation around finish lines	Use of topical anaesthetics such as ethyl alcohol and other inflammable aerosols	of gingival inflammation Produce little to no bleeding Quick procedure	Difficult to produce lateral dissipation of heat Cannot be done in a dry field

5. Slight loss of crestal alveolar bone

6. Burn marks on the root surfaces where the electrode contacted of probe forces during simulated periodontal pocket depth measurements.

2.5.1. Impression procedures

In fabricating cast restorations, the periodontium could be affected by impression procedures and materials. Heat from hydrocolloid sols and exothermic polymerizable impression material, catalysts and chemical by products of rubber base elastomeric impression materials causing allergic reactions and mechanical trauma caused by repeated insertion and removal of impression compounds could affect the periodontium. Severe periodontal reactions with subsequent loss of attachment have been reported after the use of elastic impression materials when impression material has accidentally been allowed to remain within the periodontal tissues after the impression was removed. Fortunately, this sort of damage is rare in routine dental practice.²²

3. Discussion

Restorative dental procedures are essential for the treatment and rehabilitation of decayed, damaged, or missing teeth. However, various aspects of these procedures can have detrimental effects on the periodontium, the specialized tissues surrounding and supporting the teeth. This discussion synthesizes findings from several studies on the impact of different restorative techniques and materials, highlighting areas where periodontal health may

be compromised.

3.1. Rubber dam isolation

1. Studies: Cheng Miao et al. (2014), explored the effects of rubber dam isolation during dental procedures.²³
2. Findings: These studies found that while rubber dam isolation is beneficial for maintaining a clean working field, it can lead to gingival inflammation, increased probing depth, and clinical attachment loss. This suggests that care must be taken when placing and removing the dam to avoid trauma to the periodontal tissues.

3.2. Crown preparation

1. Studies: Valderhaug et al. (1997), and Orkin et al. (1987) investigated the impact of crown preparation on the periodontium.^{11,12}
2. Findings: Crown preparation was associated with increased probing depth, gingival recession, and attachment loss. The preparation process can cause mechanical damage to the gingiva and alter the gingival margin, emphasizing the need for precise techniques and careful handling of tissues.

3.3. Subgingival margin placement

1. Studies: Valderhaug et al. (1993), Nevins et al. (1996), and Wagenberg et al. (1996) examined the effects of subgingival margin placement.^{8,9}
2. Findings: Placing restoration margins subgingivally can lead to significant gingival inflammation, increased probing depths, gingival recession, and clinical attachment loss. These findings highlight the importance of maintaining margins supragingivally when possible to preserve periodontal health.

3.4. Impression procedures

1. Studies: Laufer et al. (1996) and Perakis et al. (2004) focused on the effects of impression procedures on periodontal tissues.^{16,17}
2. Findings: Impression procedures, particularly those involving subgingival techniques, were associated with increased gingival inflammation, periodontal pocket depth, and gingival recession. The mechanical pressure and chemical irritation from impression materials can negatively impact the periodontium.

3.5. Retractable cords

1. Studies: Feng et al. (2006) examined the effects of retraction cords on periodontal health.¹⁵
2. Findings: The use of retraction cords was linked to significant gingival inflammation, increased probing depth, and gingival recession. Retraction cords

can cause physical trauma to the gingival tissues, necessitating careful placement and removal to minimize damage.

The discussed studies underscore the potential periodontal risks associated with various restorative dental procedures. Rubber dam isolation, crown preparation, subgingival margin placement, matrix bands and wedges, electrosurgery, impression procedures, and retraction cords all have the potential to negatively impact periodontal health. To mitigate these effects, dental professionals should employ meticulous techniques, opt for minimally invasive approaches, and ensure careful handling of periodontal tissues during restorative procedures. Additionally, maintaining open communication with patients about the importance of periodontal care during and after restorative treatments is crucial for long-term periodontal health.

4. Conclusion

A healthy periodontium is a pre-requisite for any form of dental treatment to be given. Research shows that the periodontal apparatus of teeth are very sensitive to minor changes to their environment and require extreme care and immense scrutinization to maintain periodontal health and prevent any further inadvertent destruction. Clinicians should also bear in mind the consequences of reckless and unplanned treatment because in the process of eliminating one problem there may be birth of another with greater consequences in terms of tooth loss. The etiology of periodontal disease can be iatrogenic in nature. The iatrogenic factors affecting the periodontium can be avoided thus resulting in a good functional outcome. It is a common mistake to compartmentalize treatment of the teeth and surrounding tissues into periodontal, endodontic, restorative and occlusal problems. The overlaps in etiology and treatment necessitate a broad multidisciplinary approach to ensure that the most effective treatment outcomes are achieved for patients.

5. Source of Funding

None.

6. Conflict of Interest

None.

References

- Schluger S, Yuodelis R, Page RC, Johnson RH. Basic procedures in dental therapy that affect the periodontium. In: Periodontal Diseases. Basic Phenomena, Clinical Management, and Occlusal and Restorative Interrelationships. Philadelphia: Lea and Febiger; 1990. p. 579–611.
- Cohen DW. Pathogenesis of periodontal disease and its treatment. Washington DC: Walter Reed Army Medical Center; 1962.
- Gargiulo AW, Wentz FM, Orban B. Dimensions and relations of the dentogingival junction in humans. *J Periodontol.* 1961;32:261–7.

- Tarnow DP, Magner AW, Fletcher P. The effects of the distance from the contact point to the crest of bone on the presence or absence of the interproximal dental papilla. *J Periodontol.* 1992;63:995.
- Felton DA, Kanoy MA, Bayne SC, Wirthman GP. Effect of in vivo crown margin discrepancies on periodontal health. *J Prosthet Dent.* 1991;65:357–64.
- Smulker H, Chaibi M. Periodontal and dental considerations in clinical crown extension: A rational basis for treatment. *Int J Periodont Rest Dent.* 1997;17(5):464–77.
- Shillingburg HT, Jacobi R, Brackett SE. Finish lines and the periodontium. In: Fundamentals of Tooth Preparations for Cast Metal and Porcelain Restorations. London: Quintessence Publishing Co.; p. 45–59.
- Valderhaug J, Ellingsen JE, Jokstad A. Oral hygiene, periodontal conditions and carious lesions in patients treated with dental bridges. A 15-year clinical and radiographic follow-up study. *J Clin Periodontol.* 1993;20(7):482–9.
- Nevins M, Skurow HM. The intracrevicular restorative margin, the biologic width, and the maintenance of the gingival margin. *Int J Periodontics Restorative Dent.* 1996;6(3):30–49.
- Wilson RD, Wilson TG, Korman KS, Newman MG. Advances in Periodontics. In: Restorative Dentistry. London: Quintessence Publishing Co Inc; 1992. p. 226–44.
- Valderhaug J, Ellingsen JE, Jokstad A. Oral hygiene, periodontal conditions and carious lesions in patients treated with dental bridges. A 15-year clinical and radiographic follow-up study. *J Clin Periodontol.* 1997;24(10):712–7.
- Orkin DA, Reddy J, Bradshaw D. The relationship of the position of crown margins to gingival health. *J Prosthet Dent.* 1987;57(4):421–4.
- Harish PV, Joseph SA. Iatrogenic Damage to the Periodontium Caused by Fixed Prosthodontic Treatment Procedures. *Open Dent J.* 2015;9(S1):190–6.
- Aishwarya M, Sivaram G. Biologic width: Concept and violation. *SRM J Res Dent Sci.* 2015;6(4):250–6.
- Feng J, Aboyoussif H, Weiner S, Jandinski J. The effect of gingival retraction procedures on periodontal health. *J Prosthet Dent.* 2006;95(6):476–83.
- Laufer BZ, Baharav H, Langer Y, Cardash HS. The effect of marginal thickness on the distortion of different impression materials. *J Prosthet Dent.* 1996;76(5):466–71.
- Perakis N, Belser UC, Magne P. Final impressions: a review of material properties and techniques. *Int J Periodontics Restorative Dent.* 2004;24(2):109–17.
- Shayeb A, Turner KN, Gillam W, G D. Accuracy and reproducibility of probe forces during simulated periodontal pocket depth measurements. *The Saudi dental journal.* 2014;26(2):50–55.
- Phatale S, Marawar PP. BEffect of retraction materials on gingival health: A histopathological study. *J Indian Soc Periodontol.* 2010;14(1):35–44.
- Parma-Benfenati S, Fugazzoto PA, Ruben MP. The effect of restorative margins on the postsurgical development and nature of the periodontium. Part 1. *Int J Periodont Rest Dent.* 1985;6:31–51.
- Wilhelmsen NR, Ramfjord SP, Blankenship JR. Effects of electrosurgery on the gingival attachment in rhesus monkeys. *J Periodontol.* 1976;47(3).
- Lang NP, Martin W, Wilson TG, Kornman KS. Quintessence Publishing Co Inc. 1992.
- Miao C, Yang X, Wong MCM, Zou J, Zhou X, Li C, et al. Rubber dam isolation for restorative treatment in dental patients. *Cochrane Database Syst Rev.* 201;2021(5):CD009858.

Author biography

Ena Sharma, Reader

Ruheh Sangha, Professor

Simran Thind, Intern

Harsimar, Student

Radhika Rayat, Senior Lecturer

Sreejit, Senior Lecturer

Riddima Sood, Senior Lecturer

Cite this article: Sharma E, Sangha R, Thind S, Rayat R, Sreejit, Sood R, Harsimar. Impact of restorative dental procedures on periodontal health: A comprehensive review. *J Oral Med, Oral Surg, Oral Pathol, Oral Radiol* 2024;10(3):162-169.