

Content available at: <https://www.ipinnovative.com/open-access-journals>

Journal of Oral Medicine, Oral Surgery, Oral Pathology and Oral Radiology

Journal homepage: www.joooo.org

Case Report

Simple bone cyst of the mandible: A case report with review of literature

Virender Gombra^{1*}, Mohammad Faisal¹, Mandeep Kaur², Keya Sircar³

¹Dept. of Oral Medicine and Radiology, Faculty of Dentistry, Jamia Millia Islamia, New Delhi, India

²Dept. of Oral Medicine and Radiology, Faculty of Dentistry, Jamia Millia Islamia, New Delhi, India

³Dept. of Oral Pathology and Microbiology, Faculty of Dentistry, Jamia Millia Islamia, New Delhi, India



ARTICLE INFO

Article history:

Received 02-09-2024

Accepted 17-09-2024

Available online 15-10-2024

Keywords:

Solitary bone cyst

Pseudo cyst

Traumatic bone cyst

ABSTRACT

Background: Simple bone cyst (SBC) was first described by Lucas in 1929. It is an asymptomatic, intraosseous cyst. It falls under pseudocyst category, as it is devoid of an epithelial lining and mostly discovered accidentally on routine radiograph. It commonly affects metaphyses of long bones such as humerus and femur. Other terminologies used for this lesion include Solitary bone cyst, traumatic bone cyst and hemorrhagic bone cyst. The incidence of cyst affecting the jaws is only 1%. About 89% of the lesion occurs in mandible and 11% in maxilla. The purpose of this article is to present rare occurrence of SBC in the mandibular region with review of literature.

Case Report: An 18 year old male patient reported with pain in right lower back teeth region. Clinically 47 was tender. Panoramic radiograph showed a radiolucent unilocular lesion in ascending ramus and mandibular body distal to 47. Diagnosis of apical periodontitis in relation to 47 and simple bone cyst mandible was made by correlating clinical, radiographic and histopathological evaluation. Surgical curettage was performed and follow up after 4 months revealed no evidence of recurrence.

Conclusion: Simple bone cyst is rare incidental lesion of the mandible. Thorough clinical, radiological and histopathologic evaluation is helpful for diagnosis and surgical management of the lesion. Conservative management should be approached to prevent noble structure, with follow up to confirm remission of the lesion.

This is an Open Access (OA) journal, and articles are distributed under the terms of the [Creative Commons Attribution-NonCommercial-ShareAlike 4.0 License](https://creativecommons.org/licenses/by-nc-sa/4.0/), which allows others to remix, tweak, and build upon the work non-commercially, as long as appropriate credit is given and the new creations are licensed under the identical terms.

For reprints contact: reprint@ipinnovative.com

1. Introduction

A simple bone cyst (SBC) was first described by Lucas in 1929 as traumatic bone cyst.¹ The international histological classification adopted by the WHO for odontogenic tumors uses the term “solitary bone cyst.”¹ The 2017 revised WHO classification of odontogenic and non-odontogenic cysts has placed this under the category of pseudocysts and used the term simple bone cyst.² Pseudocysts are defined as pathological cavities without an epithelial lining and with clinical and radiological findings similar to those of true cysts. It is a rare non-neoplastic, non-odontogenic,

intraosseous bone cyst.^{1,3} It has been referred by various names which include solitary bone cyst, traumatic bone cyst, extravasation cyst, unicameral bone cyst, hemorrhagic cyst, and idiopathic bone cyst.^{2,3} It commonly affects the metaphysis of long bones like the femur and humerus. SBC prevalence in maxilla and mandible is less than 1% and incidence is 1% of the jaw cyst. Almost 89% of the cases occur in mandible and 11% occur in maxilla.^{1,3} This article, which reports a rare case of SBC of the mandible, is in accordance with CARE guidelines. A study in brazil showed occurrence of 2.4% cases in all jaw cystic lesions.^{3,4} The aetiology of the cyst is unknown, but various proposed theories includes traumatic

* Corresponding author.

E-mail address: vgombra@jmi.ac.in (V. Gombra).

hemorrhagic theory, infectious theory, lesion degeneration theory, local thrombosis, developmental theory, etc.,⁵ out of which traumatic hemorrhagic theory is widely accepted.^{4,6} According to this theory, trauma leads to intramedullary hemorrhage. Usually, the hemorrhage will form a clot but in SBC, there is failure in the clot formation. Later on, liquefaction of clot occurs and cause bone marrow necrosis. This results in trabecular resorption by osteoclastic activity. The occurrence of lesion in mandible and in young individuals is supported by minor trauma theory which effects hemopoietic marrow.^{1,4,7,8} A simple bone cyst is usually asymptomatic and discovered accidentally on routine radiography. Sometimes, symptoms have been reported which includes swelling, pain, pathologic fracture, etc.^{4,7,9} Radiographically, the cyst appears to be radiolucent and mostly with well-defined borders. Scalloped margins may be seen where they extend between the roots of the involved teeth, which is the characteristic feature of SBC.^{4,8,10} SBC can be solitary or multiple, and they may also be associated with other pathologies like apical periodontitis, cemento-osseous dysplasia or fibrous dysplasia and cementoma.^{5,9,11} Surgical management is the treatment of choice for SBC. Curettage of the bone walls, can lead to healing of the lesion. Recurrences are rare, and may occur within three months of surgery.¹²

2. Case Report

An 18-year-old male patient reported with pain in the right lower back teeth region for 2-3 days. Pain was sudden, throbbing, and intermittent. There was no history of fever, swelling or relevant medical and family history. Provisional diagnosis considered were decayed 47 with apical periodontitis, and pericoronitis associated with 48. Orthopantomograph showed solitary radiolucency periradicular to 48 and 47 region and decay in 46,47 alongwith widening of periodontal ligament space in 47. Rdaialographic findings were suggestive of radicular cyst in relation to 47 and differential diagnosis of benign odontogenic tumor, odontogenic keratocyst and simple bone cyst were considered. (Figure 1) A cone-beam computed tomography (CBCT) scan showed a non expansile solitary hypodensity with defined margin on the right side of the mandible. The lesion extended antero-posteriorly from retromolar region of 48 till the mesial root of 47, and superio- inferiorly from alveolar crest to inferior border of the mandible. The greatest measurement of the lesion was approximately 16.8 mm x 24.63 mm. Scalloped border was visible at the interdental region extending to alveolar crestal bone which is considered as radiographic feature for SBC.(Figure 2) Aspiration was negative. Biopsy was planned. The surgical site was cleaned and sterilised with an antiseptic solution while the patient was placed comfortably in a reclined position. Inferior alveolar, lingual and buccal nerve block was administered with 2% lignocaine and

1: 100000 adrenaline as vasoconstrictor. Prognosis of the 47 appeared poor due to gross destruction of the crown structure as seen in CBCT. Thus, to achieve proper access, flap resection was done followed by extraction of 47 and 48. Lesion was surgically approached through alveolar process. An empty cavity was found with a friable lining which suggested diagnosis of SBC. The lesion was irrigated with a sterile saline solution. Curettage of the cavity was done and fresh bleeding was induced. It was carefully performed to avoid damage to the inferior nerve and vessels. Then the cavity was sutured with 3.0 silk thread reverse cutting, 16 mm needle. Postoperative medication was prescribed for 05 days and included amoxicillin with clavulanic acid 625 mg thrice a day, Diclofenac 50 mg twice a day for analgesia. The histopathological report was suggestive of a non-specific inflammatory reaction. Correlating clinical, radiological and histopathological findings, a diagnosis of SBC was made. To prevent antagonist movement removable prosthesis was advised for the time being and followed by implant placement was planned.(Figure 3) Four month follow up was uneventful and radiograph showed satisfactory bone healing with no recurrence.

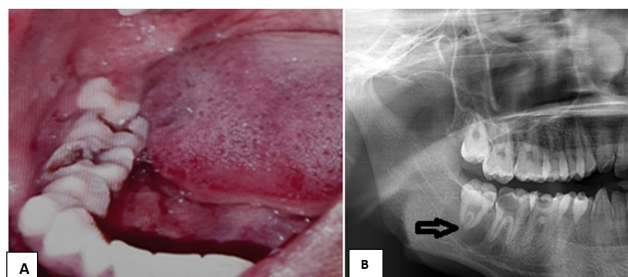


Figure 1: A): Showing 46, 47 decayed and pericoronitis in relation to 48. B): Radiograph with arrow showing periradicular hypodensity around 47, 48 root

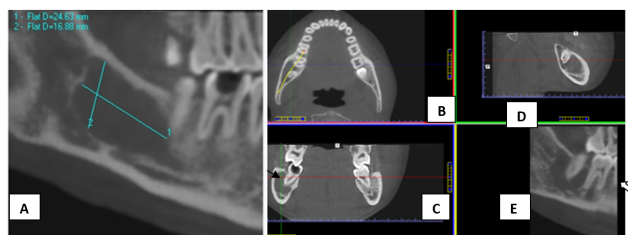

Figure 2: A,B,C,D,E): CBCT scan showing a well defined hypodense lesion in mandibular body (47 and 48 region). Black arrowhead in 2C showing thin buccal wall of decayed 47. White arrowhead in 2E showing scalloped border interdentally

3. Discussion

SBC commonly occurs in the metaphysis of long bones like humerus (65%) and femur (25%).^{6,9} Only 1% of the

Table 1: Summarizes few reported case/case series of solitary bone cyst

Author and year of publication	Age/Sex	Number of patients	Clinical features	Radiographic features	Treatment
Lima LB et al. ⁴ 2020	30 males and 30 females	60 cases	81% asymptomatic 16.6% pain or swelling 1.7% bot pain and swelling	Mostly radiolucent solitary lesions and Multiple lesions in 2 patients. Expansile in 5 cases, displaced mandibular canal in 3 cases,	Most cases treated by surgical exploration and curettage.
Dhopte A et al. ¹³ 2022	20yrs/M	01	Incidental finding on panoramic view.	Unilocular cyst like lesion of mandible in panoramic view and CT scan.	Curettage and bone graft placement.
Pérez-Iglesias B et al., ³ 2021	16yrs/M	01	Incidental finding on Panoramic radiograph.	Mandibular angle and ascending ramus. Unilocular radiolucent, size 3x2.5cm with cortical expansion.	Empty cavity, curettage performed.
Kojima I et al., ¹⁴ 2020	39 yrs/F	01	Incidental finding on Panoramic radiograph.	CT scan Unilocular, scalloped hypodense lesion of mandible Hyperintense signal on fat suppressed T2 MRI images.	Surgical management. Cemento-osseous dysplasia with small bone cyst.
Musu D et al., ⁵ 2020	27 yrs/M	01	Incidental finding on panoramic radiograph.	CBCT showed unilocular lesion with mild lingual expansion.	Serum /blood fluid evacuated followed by curettage.
Bindra S et al., ¹ 2019	25yrs/F	01	Incidental finding on radiograph.	03 SBC lesion in mandible -2 unilocular and 01 multilocular. Displaced IAC.	Empty cavity with scarce amount of soft tissue.
Brunet Lobet L et al., ⁹ 2019	15yrs/F	01	Incidental finding on a panoramic radiograph.	Unilocular lesion with thinning of lingual cortical bone.	Serohematic fluid drained by Cannulation.
Matsuda et al., ⁶ 2019	13yrs/M	01	Painless swelling with facial asymmetry from 1.5 years.	CT and OPG: Unilocular expansile radiolucent lesion, premolar to mandibular ramus, 70x30 mm. The mandibular canal could not be confirmed. MRI demonstrated high signal intensity including linear low signal area, which was considered an inferior alveolar nerve on the T2‑weighted image	Serous fluid with floating neurovascular bundle confirmed with endoscopy.
Patil SP et al., ⁷ 2019	15 yrs/F	01	Incidental finding on CBCT scan planned for implant placement.	OPG and CBCT findings: Unilocular lesion of right posterior maxilla with scalloped margin.	Thin red color aspirate. Incisional biopsy showed scanty fibrous tissue.
Martins Filoh PRS et al., ¹⁵ 2012	17 male and 9 female	26	Most patients were asymptomatic	Radiographically 19 cases were unilocular and 07 cases were multilocular.	70% cases were filled with air and rest with serous fluid with blood or only blood.

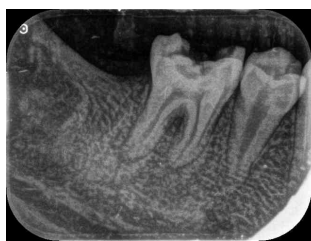

Figure 3: Radiographic evaluation of operative site after 04 months shows decrease in hypodensity with trabecular bone

lesion occurs in the orofacial region. In orofacial region, it commonly occurs in the mandible; in the premolar- molar region, followed by the ramus and midline of mandible.^{1,9} The maxillary lesion is rare and may occur in anterior maxilla or posterior maxilla.^{1,7} This lesion is more prevalent in younger age group, usually in the second decade of life, as seen in our case. Male to female ratio is slightly higher or an equal ratio to male ratio.⁷ It is a solitary lesion which is usually asymptomatic and less than 3cm in size but can also be multiple. Multiple cystic lesions are common in older females and in the maxillary region. Coexistence of other pathologies with SBC has been reported in some cases which include cementosseous dysplasia, apical periodontitis, and cementoma. Radiographically it is mostly unilocular and rarely multilocular with well defined borders; scalloped margins may extend among dental roots and usually. Uncommonly few cases have shown cortical expansion, thinning of cortical lining, root resorption or tooth displacement.^{4,7,12}

Long lasting lesions may report with complaint of pain (10-30%) and buccal expansion (18-50%).¹⁰ Lesion is usually present above the mandibular canal, but in some cases, displacement of the canal may be seen.⁶ Surgical exploration may show either empty cavity, serous bloody fluid, serous fluid, shreds of necrotic blood; without an epithelial lining.^{12,16} The analysis of the fluid content of the cyst shows high cholesterol and low protein content.^{1,3,16} Curettage is considered as treatment of choice for SBC, which induces bleeding and facilitates osteogenesis in the cavity. Protein rich- plasma protein and autologous bone grafting can also used for bone regeneration.^{3,6}

The recurrence rate of SBC is low and it usually occurs within three months of surgery. High recurrence rate were seen in cases of 71% cases of multiple cysts and 75% of cases with florid cemento-osseous dysplasia.¹² Swei et al. suggested an association between recurrence with radiographic features of absent lamina dura, scalloped margins, bone expansion, radiopaque mass, and multiple cavities.⁶ SBC should be treated early as a large cystic cavity may cause pathologic fractures and usually simple curettage is sufficient to promote osteogenesis. Floating mandibular nerve has been reported in one SBC case report lesion which was confirmed by endoscopic examination.

In our case, the margins of the mandibular canal were indistinct within the lesion, on CBCT which could be one of the radiographic presentations for freely placed mandibular nerve within the canal. As a precaution, the surgeons should consider the possibility of finding floating nerve bundles within the cavity and should not damage the nerve.^{6,12} Follow up of 14 cases showed no relapse after conservative surgical treatment. Thus, as a precaution aggressive treatment must be avoided to preserve noble structures like nerves in affected areas.⁴

4. Conclusion

Solitary bone cyst is an uncommon occurrence in jaws. Majority of these lesions may not be reported by patients because of its asymptomatic nature and usually diagnosed incidentally. To ensure correct diagnosis and treatment, adequate knowledge about the clinical, radiological and histopathological nature of the lesion should be known to the clinician. Radiographic presentation of scalloped, unilocular or multilocular lesion should include solitary bone cyst as differential diagnosis. Post operative follow up of the lesion is recommended to rule out recurrence of the lesion. Simple bone cyst usually has a much fairer prognosis and responds well with surgical management.

5. Source of Funding

None.

6. Conflict of Interest

None.

References

1. Bindra S, Jadaun G, Jois HS, Sen P. Traumatic bone cyst of mandible: a case report of rare entity and review of literature. *Contemp Clin Dent.* 2019;10(1):3.
2. Barrios-Garay K, Agudelo-Sánchez LF, Aguirre-Urizar JM, Gay-Escoda C. Critical assessment of the latest classification of jaw cysts proposed by the World Health Organization (2017). *J Clin Exp Dent.* 2017;13(11):1147–53.
3. Pérez-Iglesias B, Sandoval-Gutiérrez J, García-Freire C, Sánchez-Torres A, Gay-Escoda C. Simple bone cyst: A case report. *J Clin Exp Dent.* 2021;13(2):e207.
4. Lima LB, Filho SAF, DePaulo LF, Servato JP, Rosa RR, DeFaria PR. Simple bone cyst: description of 60 cases seen at a Brazilian School of Dentistry and review of international literature. *Med Oral Patol Oral Cir Bucal.* 2020;25(5):616–25.
5. Musu D, Bardini G, Shemesh H, Dettori C, Cotti E. Multimodular Assessment of a Traumatic Bone Cyst Overlapped with Apical Periodontitis. *Case Rep Dent.* 2020;2020:8829305.
6. Matsuda S, Yoshimura H, Sano K. A floating inferior alveolar neurovascular bundle in a simple bone cyst: A case report. *Exp Ther Med.* 2019;17(6):4677–80.
7. Patil SP, Sodhi SJ, Mishra SS, Farha SS. Solitary bone cyst of posterior maxilla: A rare presentation. *Contemp Clin Dent.* 2019;10(1):166–9.
8. Harnet JC, Lombardi T, Klewansky P, Rieger J, Tempe MH, Clavert JM, et al. Solitary bone cyst of the jaws: a review of the etiopathogenic hypotheses. *J Oral Maxillofac Surg.* 2008;66(11):2345–8.

9. Brunet-Llobet L, Lahor-Soler E, Mashala EI, Miranda-Rius J. Continuous surgical decompression for solitary bone cyst of the jaw in a teenage patient. *Case Rep Dent*. 2019;2019:9137507.
10. Mortazavi H, Baharvand M, Safi Y. Scalloped border as a possible diagnostic aid for differentiating jaw lesions: A pictorial essay. *Imaging Sci Dent*. 2022;52(3):309–17.
11. Aburas S, Bandura P, Al-Ibraheem A, Berger S, Meier M, Turhani D. A large maxillary cemento-ossifying fibroma superimposed with solitary bone cyst documented over 18 years: A case report. *Int J Surg Case Rep*. 2020;68:257–62.
12. Martins-Filho PRS, Santos TDS, Araújo V, Santos JS, Andrade E, Silva L. Traumatic bone cyst of the mandible: a review of 26 cases. *Braz J Otorhinolaryngol*. 2012;78(2):16–21.
13. Dhopte A, Tandon P, Shenoy M, Mustilwar R, Abdul NS, Bagde H, et al. Traumatic Bone Cyst of the Anterior Mandibular Region: A Case Report. *Cureus*. 2022;14(11):e31315.
14. Kojima I, Nishioka T, Sakamoto M, Sai Y, Ezoe Y, Iikubo M, et al. Florid Cemento-Osseous Dysplasia-Associated Simple Bone Cyst Showing Marked Irregular Border and High Apparent Diffusion Coefficient Value. *Case Rep Dent*. 2020;2020(1):8854428.
15. Martins-Filho PRS, Santos TDS, Araújo V, Santos JS, Andrade E, Silva L. Traumatic bone cyst of the mandible: a review of 26 cases. *Braz J Otorhinolaryngol*. 2012;78:16–21.
16. Choi SY, Boboeva O, Ham JY, An CH, Lee ST, Kim JW, et al. Analysis of the fluid contents of simple bone cyst in the mandible. *Sci Rep*. 2022;12(1):10083.

Author biography

Virender Gombra, Professor

Mohammad Faisal, Professor

Mandeep Kaur, Professor

Keya Sircar, Dean and Professor

Cite this article: Gombra V, Faisal M, Kaur M, Sircar K. Simple bone cyst of the mandible: A case report with review of literature. *J Oral Med, Oral Surg, Oral Pathol, Oral Radiol* 2024;10(3):217-221.