

Clinical and histological evaluation of toluidine blue positive and negative stained oral mucosal lesions

Parul Khare Sinha¹, Madhika Patidar^{2,*}, Vineet Raj³, Shaleen Chandra⁴, Nitin Agarwal⁵

¹Assistant Professor, Dept. of Oral Pathology, College of Stomatology, Ninth Peoples Hospital Shanghai, China, ²Reader, Pacific Dental College & Hospital, Rajasthan, ³Professor & Head, Chandra Dental College & Hospital, Barabanki, Uttar Pradesh, ⁴Professor & Head, Dept. of Oral Pathology & Microbiology, Faculty of Dental Sciences, King George's Medical University, Lucknow, Uttar Pradesh, ⁵Professor & Head, Dept. of Oral Medicine & Radiology, Chandra Dental College & Hospital, Barabanki, Uttar Pradesh

***Corresponding Author:**

Email: madhvikapatidar@yahoo.com

Abstract

Introduction: Screening of suspicious oral precancerous lesions can aid in early detection of oral cancer thus reducing the mortality and morbidity associated with this condition. Incisional biopsy remains a gold standard for diagnosis of oral potentially malignant disorders. Toluidine blue is a basic metachromatic stain that demonstrates affinity for DNA and RNA. It offers a potentially simple, inexpensive, and sensitive chair-side solution for screening of early oral squamous cell carcinoma and high-grade dysplasias. The aim of this study was to assess the reliability of toluidine blue stain as clinical screening test, for presence of epithelial dysplasia in oral mucosal lesions. In this study, biopsy was done in patients with oral pre-malignant lesions to relate their toluidine blue status to outcome as well as to conventional histopathologic features.

Method: Study Group consisted of 51 patients with potentially malignant oral mucosal lesions like homogenous leukoplakia (20), non-homogenous leukoplakia (16), erythroplakia (6), oral submucous fibrosis (5) and tobacco pouch keratosis (4). Patients were subjected to toluidine blue vital stain and were observed for positive and negative staining. Biopsy was taken from both toluidine blue positive as well as negative lesions and graded for epithelial dysplasia to analyze the role of toluidine blue staining in selecting lesions requiring biopsy.

Results: Out of 51 lesions 46 cases stained positive with toluidine blue vital stain. The overall sensitivity and specificity of toluidine blue staining in identifying dysplastic lesions was found to be 97.6% and 50% respectively.

Conclusion: Staining with toluidine blue was demonstrated to be highly reliable in the detection of dysplasia since false-negative results for the lesions did not occur. Toluidine blue staining can be an adjunct to clinical judgment and not a substitute for either judgment or biopsy.

Keywords: Epithelial dysplasia, potentially malignant disorders, Pre-malignant lesions, Oral mucosal lesions, Toluidine blue

Access this article online
Website: www.innovativepublication.com
DOI: 10.5958/2395-6194.2016.00031.X

Introduction

Detection of oral pre-malignant lesions (PML) at an early stage is fundamental to improve the chances of cure and lesser treatment associated morbidities. At many instance, clinicians have difficulty in recognizing patients at high risk of developing oral cancer. The major problem is when and from which site the biopsy should be taken from suspected lesions. It depends on the clinician's ability to differentiate PML from reactive and inflammatory diseases.¹ There is a pressing need for development of visual aids that will help in detection of these lesions with high-risk of progression.²

Previous literature on toluidine blue showed that it is a practical, inexpensive, rapid and effective adjunct diagnostic tool for early recognition of oral PMLs.³

Toluidine blue (TB) (tolonium chloride) is a member of thiazine group of metachromatic dyes. Its staining may appear as a dark royal blue suggesting positive stain or a pale royal blue color suggesting doubtful or no stain.^{4,5}

The aim of this study was to assess the reliability of TB stain as clinical screening test, for presence of epithelial dysplasia in oral mucosal lesions. In this study, biopsy was done in patients with primary OPLs to relate their TB status to outcome as well as to conventional histopathologic features.

Materials & Method

This prospective study was conducted in Department of Oral Pathology and Department of Oral Medicine, Saraswati Dental College & Hospital, Lucknow. The study group consisted of 51 patients with potentially malignant oral mucosal lesions like homogenous leukoplakia (20), non-homogenous leukoplakia (16), erythroplakia (6), oral submucous fibrosis (5) and tobacco pouch keratosis (4). The exclusion criteria included patients with systemic disorders, patients not willing for biopsy, patients with lesions at sites where application of toluidine blue or

biopsy was not possible and oral submucous fibrosis patients with severe fibrosis or trismus. Traumatic lesions and oral inflammatory changes were also excluded from the study to avoid false positive results. Subjects were selected from both genders and all age groups. Informed consent was taken from patients before application of TB vital stain and biopsy.

As described by Mashberg, toluidine blue solution consists of 1 gm of TB powder, 10 ml of 1% acetic acid, 4ml of absolute alcohol and 86ml of distilled water to make up 100 ml of 1% solution of TB. The solution is adjusted to 4.5 pH.⁶

Mucosal surfaces were stained preoperatively. Initially the patient was asked to rinse his mouth twice with water for 20 seconds to remove debris. Next 1% acetic acid was applied using cotton swab for 20 seconds to remove any rosey saliva and remaining organic debris. 1% TB solution is then applied for 20 seconds by means of cotton swab. This was followed by application of 1% acetic acid once again on mucosa attained by TB to remove nonspecific mechanically retained stain from the lesion. Finally patient was asked to rinse mouth with water and subsequently TB staining was assessed. The clinical uptake of stain was evaluated by same examiner and the cases were divided into two groups: TB positive lesions – those which stain strongly with the vital dye (Fig. 1), and TB negative lesions – those which stain weakly or those which did not stain with the vital dye.

Biopsies were performed from both TB positive as well as TB negative lesions. All specimens were subjected to formalin fixation, tissue processing followed by hematoxylin & eosin staining. The pathologist examining all the biopsies was not clued-up regarding the clinical or TB staining evaluation of each sample. For the statistical analysis, we used histopathologic assessment as the gold standard with which we compared clinical examination and TB staining of the lesions. The biopsy results were correlated with clinical findings and the true positive, true negative, false positive, false negative data were derived. This data was used to calculate sensitivity and specificity. Sensitivity and specificity were determined from true positive and true negative results. Positive predictive value was calculated as true positive/true positive + false positive and negative predictive value as true negative/false negative + true negative.

Results

The study group consists of 51 patients having oral lesions suspicious of premalignancy. These included patients with homogenous leukoplakia (20), nonhomogeneous leukoplakia (16), erythroplakia (6), oral submucous fibrosis (4) and tobacco pouch keratosis (5). Most of the patients were in the age group of 30 - 60 years with a mean age of 45 years. In our study a male preponderance was seen and majority of patients had more than one risk factor predisposing

for oral cancer, which included smoking, alcohol, quid/tobacco chewing, and spicy food. Buccal mucosa was the most common site of lesion with 41 cases (80.3%) followed by vestibule in 8 cases (16.6%) and commissure of lip 2 cases (4.1%).

Overall 46 cases stained positive with TB vital stain. These cases when subjected to biopsy, 41 (89.1%) were positive for dysplasia (Fig. 2) and 5 (10.9%) were nondysplastic histologically (Table 1). These 5 cases (10.9%) which stained TB positive but were negative for dysplasia on biopsy, constituting false positives, included 3 cases of tobacco pouch keratosis, and 1 each of homogeneous leukoplakia and oral submucous fibrosis (Table 2).

5 cases which did not take up TB stain clinically included two cases of oral submucous fibrosis and one each of homogeneous leukoplakia, nonhomogeneous leukoplakia, and erythroplakia. Out of these 5 TB negative cases, both oral submucous fibrosis cases were found negative for dysplasia on histopathological examination (true negative,) while remaining showed epithelial dysplasia (false negative). The overall sensitivity and specificity of TB staining in identifying dysplastic lesions was found to be 97.6% and 50% respectively.

Of 20 cases of homogeneous leukoplakia 19 stained positive with TB out of which 18 cases were found to be dysplastic on histopathological examination and 1 case was non-dysplastic thus giving a sensitivity of 94.7% (Table 3). One case which did not clinically take up the stain was found to be histologically dysplastic while there was no true negative case in this group. Because of lack of true negative cases in this group we could not comment on the specificity of this technique for these cases.

For non-homogenous leukoplakia our study group consisted 16 cases. Out of which 15 stained TB positive. All these 15 cases were found dysplastic on histopathological evaluation, while one case which did not take up stain clinically was also found to be dysplastic giving 93.75% sensitivity (Table 3). Since there were no true negative cases we could not comment on specificity.

Next group in our study included 6 cases of erythroplakia. Out of which 5 cases were stained positively by TB and were found to be dysplastic on histological evaluation. One case which did not stain by TB was dysplastic on histological examination. This group gave sensitivity of 83.3% and specificity cannot be commented as there were no true negative cases (Table 3).

There were 4 cases of oral submucous fibrosis, out of which 2 cases stained with TB and 2 cases did not stain clinically. When histopathology was analyzed, it was found that only 1 case was dysplastic and rest 3 cases were non-dysplastic giving sensitivity of this group as 100% and specificity as 66.7% (Table 3).

Last group of our study consisted 5 cases of tobacco pouch keratosis. All the cases were positively stained with TB clinically. On histopathological examination it was found that 2 out of 5 cases were

dysplastic and 3 cases were non dysplastic. So sensitivity for this group was 100% (Table 3). Since there were no cases of true negative so we cannot comment on specificity of this technique in this group.

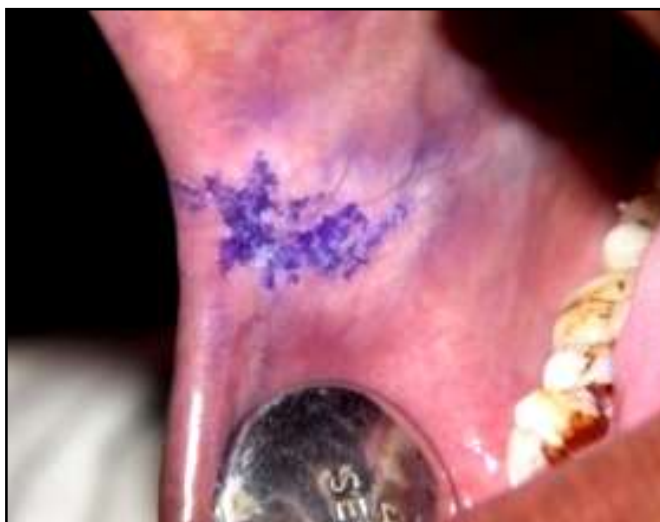

Fig. 1: Lesion with Toluidine blue positive stain

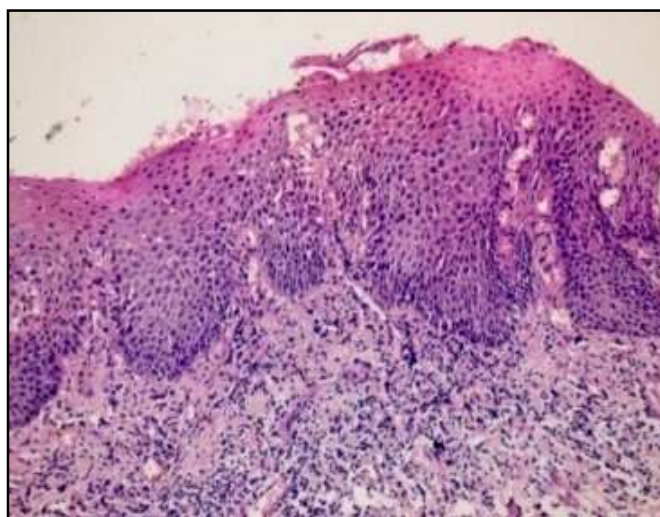


Fig. 2: Haematoxiline and Eosine stained section showing Dysplastic Epithelium

Table 1: Toluidine blue positive and negative lesions and their histopathological evaluation

Type of lesion	Number of cases (n= 51)	Clinical		Histology	
		Toluidine Blue Positive (46)	Toluidine Blue Negative (5)	Dysplastic (44)	Non Dysplastic (7)
Homogenous Leukoplakia	20	19	1	19	1
Non Homogenous Leukoplakia	16	15	1	16	0
Erythroplakia	6	5	1	6	0
Oral Submucous Fibrosis	4	2	2	1	3
Tobacco Pouch Keratosis	5	5	0	2	3

Table 2: The results of individual lesions

Lesions	N	True Positive	True Negative	False Positive	False Negative
Homogenous Leukoplakia	20	18	-	1	1
Non Homogenous Leukoplakia	16	15	-	-	1
Erythroplakia	6	5	-	-	1
Oral sub mucous fibrosis	4	1	2	1	-
Tobacco pouch keratosis	5	2	-	3	-
Total	51	41	2	5	3

Table 3: Sensitivity and specificity of lesions

Lesions	Sensitivity	Specificity
Homogenous leukoplakia	94.7%	0
Non homogenous leukoplakia	93.75%	0
Erythroplakia	83.3%	0
Oral sub mucous fibrosis	100%	66.7%
Tobacco pouch keratosis	100%	0

Discussion

Several adjuncts to visual examination, specifically application of TB and exfoliative cell collection, may lead to advances in recognition of lesions and may guide selection of biopsy sites. TB staining is considered to be a sensitive adjunct tool for identifying early oral squamous cell carcinoma and high-grade dysplasias.² TB was first used by Riechart in 1963 to stain uterine cervical carcinoma in Situ. Its use in vivo is based on the fact that dysplastic and anaplastic cells contain quantitatively more nucleic acids than normal tissues. In addition, malignant epithelium may contain intracellular canals that are wider than normal epithelium; this is a factor that enhances penetration of dye.^{7,8} Further proposals for uptake of TB stain in dysplasias and carcinomas include presence of high density of nuclear material, loss of cell cohesion, and increased mitotic activity.⁵

The results of our study showed that, TB when used as a vital stain is highly sensitive in identifying oral lesions with dysplastic epithelium. Out of 44 lesions which were diagnosed positive for presence of dysplasia on histological examination, 41 cases (Table 1) stained positively with TB, thus giving a sensitivity of 97.6% and positive predictive value of 89.1%. These findings are in concordance with many previous studies.^{6,9,10,11,12} Even though the sensitivity of toluidine blue staining was found to be high in our study the specificity was only 50% and negative predictive value was 40%. 5 lesions which stained positive were found to be histologically negative. Out of these cases, 3 were tobacco pouch keratosis, and 1 each of homogenous leukoplakia and oral submucous fibrosis. It has been proposed that in certain lesions the premalignant changes might have started at molecular level but may not have been expressed at light microscopic levels yet. In fact Guo have shown that a group of lesions showing false positivity with toluidine blue have shown allelic losses and loss of heterozygosity.¹³ Hence it may be

assumed that some of the false positive lesions may represent lesions which are actually positive at molecular level. For this reason, molecular study of these lesions may help us in resolving the nature of these false positive lesions. Another suggestion for reducing the false positive cases have been given by M. Eslami et al who stated that false positive lesions should be reviewed after 7 to 14 days by second staining, thus allowing time for healing of traumatic or inflammatory lesions as these lesions have shown tendency to take up the stain.¹⁴ The reasons for false negative staining are not very well understood. In cases of leukoplakia and other lesions with hyperkeratotic epithelium,^{14,15} it could be possible that thick, impermeable layer of keratin may prevent penetration of the dye to deeper layers which usually show nucleic acid changes hence causing false negative staining. An additional reason which has been suggested is that there may be variability in assessing the staining by different observers,¹⁶ leading to different definition of false negative staining. Even though this might be a limitation, in our study we found that the rate of false negative was quite low hence may not be considered as a limitation in utility of the stain.

Conclusion

Early detection and timely intervention is the essence of any pre-cancer and cancer treatment protocol. Supravital staining with toluidine blue is useful in the early detection of malignancies.

We felt that it is an appropriate adjunct to visual examination, especially for patients with suspicious lesions. Further studies with larger cohort of patients are needed to better understand the potentiality of the different ancillary methods employed in the early detection and prevention of oral precancerous lesions.

References

1. Allegra E, Lombardo N, Puzzo L, Garozzo A. The usefulness of toluidine staining as a diagnostic tool for precancerous and cancerous oropharyngeal and oral cavity lesions. *Acta Otorhinolaryngol Ital.* 2009 Aug;29(4):187-90.
2. Zhang L, Williams M, Poh CF, Laronde D, Epstein JB, Durham S, Nakamura H, Berean K, Hovan A, Le ND, Hislop G, Priddy R, Hay J, Lam WL, Rosin MP. Toluidine blue staining identifies high-risk primary oral premalignant lesions with poor outcome. *Cancer Res.* 2005 Sep 1;65(17):8017-21.
3. Pallagatti S, Sheikh S, Aggarwal A, Gupta D, Singh R, Handa R, Kaur S, Mago J. Toluidine blue staining as an adjunctive tool for early diagnosis of dysplastic changes in the oral mucosa. *J Clin Exp Dent.* 2013;5(4):e187-91.
4. Gandolfo S, Pentenero M, Broccoletti R, Pagano M, Carozzo M, Scully C. Toluidine blue uptake in potentially malignant oral lesions in vivo: clinical and histological assessment. *Oral Oncol.* 2006 Jan;42(1):89-95. Epub 2005 Oct 25.
5. Sridharan G, Shankar A A. Toluidine blue: A review of its chemistry and clinical utility. *J Oral Maxillofac Pathol.* 2012 May;16(2):251-5.
6. Mashberg A. Reevaluation of Toluidine Blue Application as a Diagnostic Adjunct in the Detection of Asymptomatic Oral Squamous Carcinoma: A Continuing Prospective Study of Oral Cancer III. *Cancer* 1980;46:758-63.
7. Martin IC, Kerawala CJ, Reed M. The application of toluidine blue as a diagnostic adjunct in the detection of epithelial dysplasia. *Oral Surg Oral Med Oral Pathol Oral Radiol Endod.* 1998 Apr;85(4):444-6.
8. Giovannacci I, Vescovi P, Manfredi M, Meleti M. Non-invasive visual tools for diagnosis of oral cancer and dysplasia: A systematic review. *Med Oral Patol Oral Cir Bucal.* 2016 May 1;21 (3):e305-15.
9. Chandra Hegde MC, M. Kamath PM, Shreedharan S, Dannana NK, Raju RM. Supravital Staining: It's Role In Detecting Early Malignancies. *Indian J Otolaryngol Head Neck Surg* 2006;58(1):31-4.
10. Warnakulsuriya, Johnson NW. Sensitivity and specificity of OraScan toluidine blue mouth rinse in the detection of oral cancer and precancer. *J Oral Pathol Med* 1996;25:97-103.
11. Epstein JB, Scully C, Spinelli JJ. Toluidine blue and Lugol's iodine application in the assessment of oral malignant disease and lesions at risk of malignancy. *J Oral Pathol Med* 1992;22:160-3.
12. Vashisht N, Ravikiran A, Samatha Y, Rao PC, Naik R, Vashisht D. Chemiluminescence and Toluidine Blue as Diagnostic Tools for Detecting Early Stages of Oral Cancer: An in vivo Study. *J Clin Diagn Res.* 2014 Apr;8(4):ZC35-8.
13. Guo Z, Yamaguchi K, Sanchez-Cespedes M, Westra WH, Koch WM, Sidransky D. Allelic Losses in OraTest-directed Biopsies of Patients with Prior Upper Aerodigestive Tract Malignancy. *Clin Cancer Res.* 2001 Jul;7(7):1963-8.
14. Eslami M, Keyhani A, Motahary P, Agha-Hosseini F, Sharifzadeh N. Comparison and Evaluation of the Reliability of Oratest and Generic Toluidine Blue in the Detection of Oral Malignancy and Premalignancy. *J Dent (Tehran)* 2005. 2(3):101-8.
15. Mirbod SM, Ahing S. Tobacco-Associated Lesions of the Oral Cavity: Part I. Nonmalignant Lesions. *J Can Dent Assoc.* 2000 May;66(5):252-6.
16. Patton LL, Epstein JB, Kerr AR. Adjunctive techniques for oral cancer examination and lesion diagnosis: a systematic review of the literature. *J Am Dent Assoc.* 2008 Jul;139(7):896-905; quiz 993-4.