

Endodontic retreatment with a regenerative approach: a case report

Abhinav Misra¹, Gauri Mishra^{2,*}, Shreya Kapoor³, Chakit Maheshwari⁴

^{1,2}Associate Professor, ^{3,4}Student, Govt. Medical College, Uttar Pradesh

***Corresponding Author:**

Email: gaurimishra12@gmail.com

Abstract

Revisional Endodontics (RE) is a challenging procedure especially when the tooth has a concomitant Lesion of Endodontic Origin (LEO) and other procedural mishaps all at the same time. This case report presents the management of such a case using Regenerative approach and bioceramic materials to achieve healing.

Keywords: Regenerative, Bioceramic, Retreatment

Access this article online

Website:

www.innovativepublication.com

DOI:

10.5958/2395-6194.2016.00041.2

Case Report

A 20 year old male patient reported with a complaint of pain in lower tooth and pus discharge from the adjacent gingiva after undergoing RCT elsewhere. The treating doctor had attempted Re treatment on the same tooth but the problem persisted. So the patient decided to seek a second opinion.

The medical history was non contributory and the patient was in an apparently healthy condition.

Extra oral examination did not reveal any abnormal findings. Upon intraoral examination, Mandibular Left First Molar [36] was the tooth in complaint. 36 had evidence of access opening done with a large sinus in the adjacent buccal mucosa (Fig. 1). There was a large perforation evident on the lingual wall of the crown (Fig. 2).

IOPA X ray was taken and the following anomalies were observed: (Fig. 3)

1. There was a large overextension of GP beyond the apex of the distal root.
2. Obturation in the Mesio buccal canal was short of the apex.
3. Mesio lingual canal was not explored at all.
4. There was large perforation in the furcation area with GP extending through it accompanied with a radiolucent area distal to the mesial root signifying extensive bone loss.

Thus revisional endodontics in this case was complicated by the following factors:

1. Over extended GP in the distal root
2. Short obturation in MB canal with possible ledge formation.
3. Unexplored canal(s).
4. Perforation in the crown as well as root.

5. Large area of bone loss.

All this was explained to the patient and was given the option of extraction and replacement of the tooth. However the patient opted for retreatment and thus the tooth was retreated as follows.

All the GP was removed from the canals however the over extended GP from the distal root could not be retrieved (Fig. 4). The missed canal was located and all the canals were prepared and Triple Antibiotic Mix was placed in the canals for one month and patient was advised warm saline rinses 4-5 times per day. Systemic antibiotics were not given but analgesics were prescribed SOS. Patient was instructed not to bite hard from that site and report any discomfort.

After one month the tooth was obturated as the patient was asymptomatic and sinus had healed. The coronal and furcal perforations were repaired using White MTA (Pro Root, Dentsply) (Fig. 5). After this a full thickness mucoperiosteal flap was raised and the furcal area was curetted (Fig. 6) and PRF prepared from the patient's blood was placed in the defect (Fig. 7) and immediate post op IOPA was taken (Fig. 8). After one month the tooth was restored with a PFM crown (Fig. 9) and IOPA x ray showed complete healing of the lesion (Fig. 10). Since then the patient has been on regular follow up and has not reported any recurrence of the symptoms.

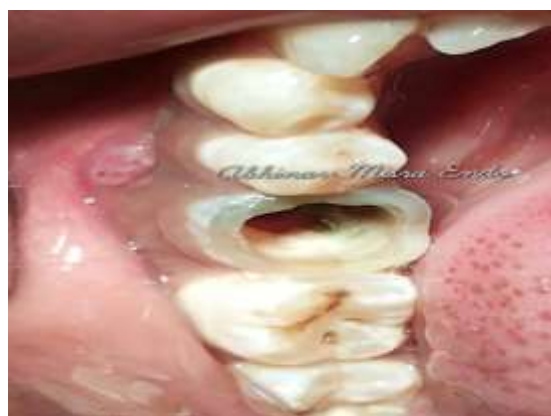

Fig. 1

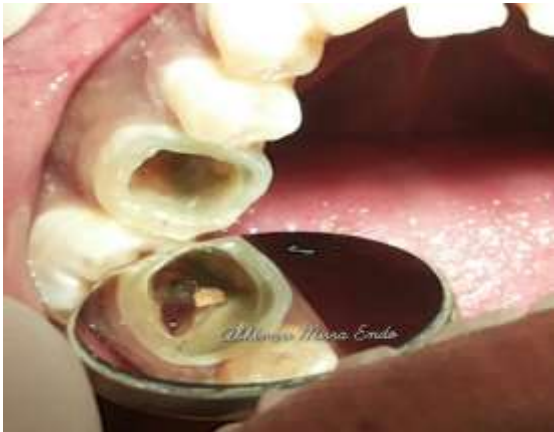

Fig. 2

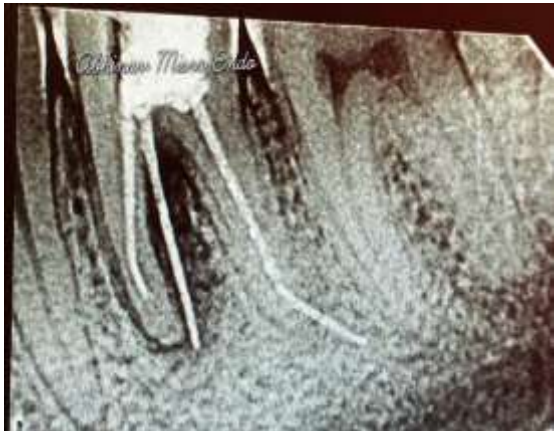

Fig. 3

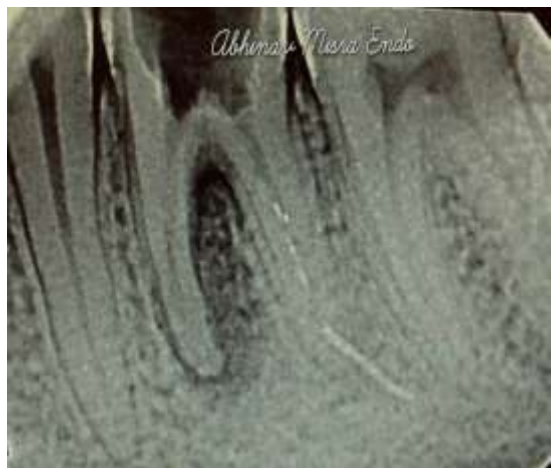

Fig. 4

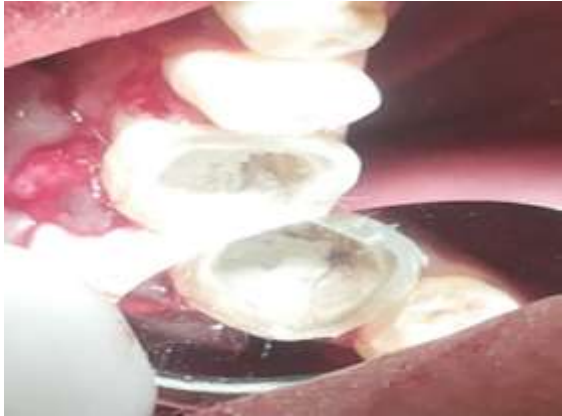

Fig. 5

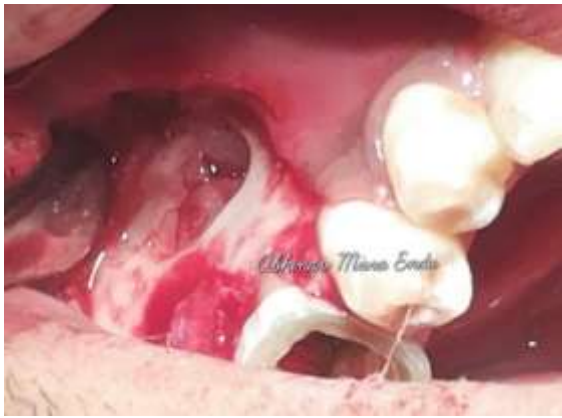

Fig. 6



Fig. 7

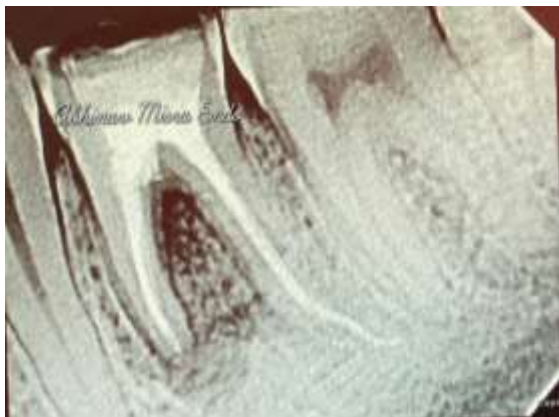


Fig. 8

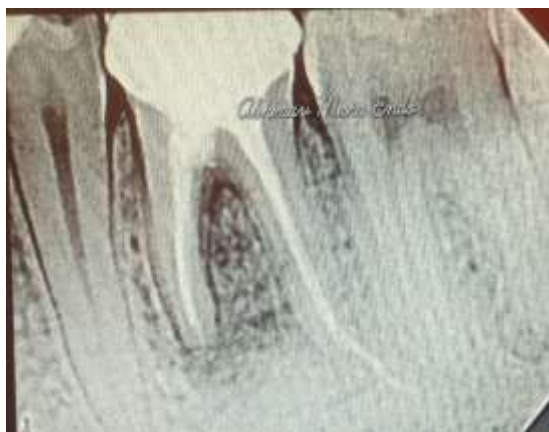

Fig. 9

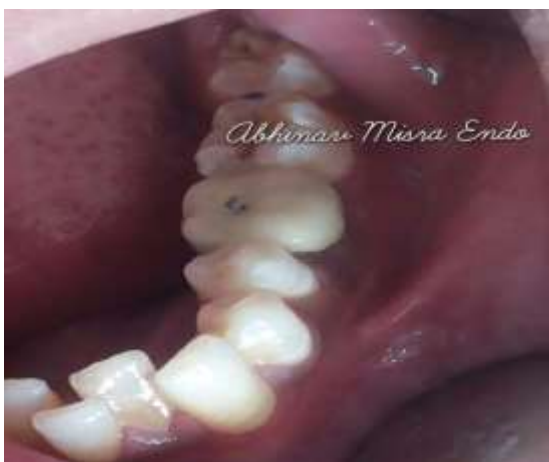

Fig. 10

Discussion

Revisional Endodontics (RE) conventionally known as Re Treatment is carried out when the earlier attempt at endodontic therapy does not lead to healing or relief in the symptoms.⁽¹⁾ Persistence of symptoms is the major cause due to which a patient seeks retreatment as other indications like non observed healing on x ray, separated instruments, missed canals, short or over obturations etc. are objective in nature and not within the jurisdiction of the patient.⁽²⁾ Revisional

endodontics may be non surgical or surgical in nature and depends upon various factors like the cause of failure of earlier treatment, location of the tooth, patient's aspiration and skill of the dentist along with the armamentarium available.⁽³⁾

Current literature and opinion strongly favours non-surgical retreatment as the mainstay in RE as most of the failures can be attributed to few major categories like missed canals, abnormal anatomy, improper bio mechanical preparation and obturation etc.⁽⁴⁾ Procedural mishaps like separated instruments and perforations can also be managed by a non surgical approach in most of the cases with the help of magnification and use of bio ceramic materials. Lesions of Endodontic Origin (LEO) are those defects in the periodontium that originate due to some pulpal (endodontic) cause. LEOs are usually apical or lateral to the canals and the treatment is non surgical endodontic therapy (NSRCT).⁽⁵⁾ The main cause is failure to properly clean and shape the canal and provision of a fluid tight seal which leads to percolation of fluids and microbes. The literature is abundant with reports of even large sized LEOs responding to NSRCT in a favourable manner.

However in cases if the lesion is not responding to NSRCT, persisting symptoms, presence of true cyst or patient related factors like lack of time etc surgical option can be exercised. Use of Regenerative concepts along with surgical approach greatly improves the healing response.

The goal of regenerative dentistry is to induce biologic regeneration of dental tissues and their supporting structures. The potential for regenerative dentistry is largely in part due to the advancements in biologic therapies that apply growth and differentiation factors which in turn hasten or induce natural biologic regeneration. Many of these concepts have emerged from the burgeoning field of tissue engineering, which emphasizes the spatial assembly of distinct stem cells, growth factors/morphogens, PRF and scaffolds to form a functional tissue.⁽¹¹⁾

The rationale for its use is largely dependent on its functional components which are:

1. Growth Factors: (Anabolic Effect)
2. Inflammatory Mediators: (Anti-inflammatory Effect)
3. Fibrinogen: (Scaffolding Effect)

PRF It is a volume of autologous plasma that has a platelet concentration above baseline. Normal platelet counts in blood ranges between 150,000/ μ L and 350,000/ μ L, averaging around 200,000/ μ L. Hence 100,000 platelets / μ L in a 5ml volume of plasma is the working definition of PRF today. Platelet-rich fibrin (PRF), developed in France by Choukroun et al (2001), is a **second generation platelet concentrate** widely used to accelerate soft and hard tissue healing. Its advantages over the better known platelet-rich plasma (PRP) include ease of preparation/application, minimal

expense and lack of biochemical modification i.e. no bovine thrombin or anticoagulant is required.

PRF can be considered as an autologous healing biomaterial, incorporating leucocytes, platelets and a wide range of key healing proteins within a dense fibrin matrix. With its strong fibrin architecture and slow release of growth factors and glycoprotein over several days, this natural bioactive membrane can enhance soft tissue healing while protecting both the surgical sites as well as the grafted material (s) from external aggressions. Though platelets and leukocyte cytokines play an important part in the biology of this biomaterial, the fibrin matrix supporting them certainly constitutes the determining element responsible for the real therapeutic potential of PRF. Cytokines are quickly used up and destroyed in a healing wound. The synergy between cytokines and their supporting fibrin matrix has much more importance than any other parameter. Aphysiologic fibrin matrix (such as PRF) will have very different effects than a fibrin glue enriched with cytokines (such as PRP), which will have a massively uncontrollable and short-term effect.^[2]

MTA is composed of tricalcium silicate, tricalcium aluminate, tricalcium oxide, silicate oxide, mineraloxide and bismuth oxide. The powder consists of fine hydrophilic particles that harden in the presence of water. Hydration of the powder leads to the formation of a colloidal gel, which then solidifies to a hard structure in approximately 4 h.⁽⁶⁾

MTA has the capacity to promote hard tissue formation. In an animal study, Tziapas et al. showed that pulp capping with MTA induces cytological and functional changes in pulpal cells, which result in the formation of fibrodentin and reparative dentin at the surface of mechanically-exposed dental pulp.⁽⁷⁾

Torabinejad et al. also showed that MTA was covered with a cementum layer when used as a root-end filling material in dogs and monkeys.⁽⁸⁾ Then dog study showed that cementum was present on MTA in all of their 10 samples. Pitt Ford et al. reported continuous hard tissue formation around excess MTA material when it was used to repair a perforation.⁽⁹⁾

Conclusion

Thus it can be concluded that the use of regenerative principles and bioceramic materials in cases of revisional endodontics can greatly enhance the healing of tissues especially if the tooth is challenged by a multitude of problems. Optimal healing was achieved within a short span of time with the use of regenerative materials.

References

1. A review of bioceramic technology in endodontics Ken Koch, Dennis Brave, Allen Ali Nasseh. *Roots*;4:12.
2. Evaluation of the *In Vitro* Bioactivity of Bioceramics. Chengtie Wu, Yin Xiao. *Bone and Tissue Regeneration Insights* 2009;2:25–29.

3. Ten Tips for Using Bioceramics in Endodontics. Kenneth Koch, Dennis Brave. dentaltown.com.
4. Bioceramics: From Concept to Clinic. Larry L. Hench. *Journal of the American Ceramic Society*;74:7.
5. Consequences of and strategies to deal with residual post-treatment root canal infection. M.-K. Wu, P. M. H. Dummer, P. R. Wesselink. *International Endodontic Journal*, 39,343–356,2006.
6. Nonsurgical Endodontic Retreatment: Issues Influencing Treatment. Clifford J. Ruddle. *Dentistry Today*:1998(2).
7. Treatment choices for negative outcomes with non-surgical root canal treatment: non-surgical retreatment vs. surgical retreatment vs. implants. STEVEN A. COHN *ENDODONTIC TOPICS* 2005:1601-1538.
8. Effectiveness of different techniques for removing gutta-percha during retreatment. A. V. Masiero, F. B. Barletta. *International Endodontic Journal*,38,2–7,2005.
9. Contemporary Endodontic Retreatments: An Analysis based on Clinical Treatment Findings. Michael M. Hoen, Frank E. Pink, J. Endodod. VOL. 28, NO. 12, DECEMBER 2002.
10. Efficacy, cleaning ability and safety of different rotary NiTi instruments in root canal retreatment. M. Hu' lsmann V. Bluhm *International Endodontic Journal*, 37,468–476,2004.
11. PRF An Overview. Marco del Corso et al. *JACD VOL1 NO 9*; DEC-JAN 2010.