

## A non-syndromic hereditary oligodontia- a rare case report

Raj Rathore<sup>1</sup>, Deepshikha Rathore<sup>2,\*</sup>, Piyush Arora<sup>3</sup>, Don Varghese<sup>4</sup>, Sumita Kaswan<sup>5</sup>

<sup>1</sup>Senior Lecturer, Vyas Dental College, Jodhpur, <sup>5</sup>Vice-Principal, Professor & HOD, Dept. of Conservative Dentistry & Endodontics, <sup>2</sup>Senior Lecturer, <sup>3</sup>Reader, Dept. of Oral Pathology, <sup>4</sup>Reader, Dept. of Oral & Maxillofacial Surgery, Jodhpur Dental College, Jodhpur, Rajasthan

**\*Corresponding Author:**

Email: deepshikhadeora@gmail.com

### Abstract

Tooth agenesis is a condition where teeth are missing due to developmental failure. It is often seen in one-quarter of general population making it the most common of human developmental anomalies and it may or may not be associated with syndromes. Oligodontia is a rare hereditary or developmental anomaly showing absence of 6 or more teeth with the incidence varying from 0.08% to 0.16%. The genes expressed in embryonic tissues associated with non-syndromic tooth agenesis are found to be MSX1 and PAX9 genes. These genes play a key role in tooth development, where PAX9 and MSX1 are responsible for odontogenesis in multicuspid and incisors respectively.

This case report describes a rare familial presentation of non-syndromic hereditary oligodontia in a 20-year-old female, showing absence of ten teeth involving first and second molars in all four quadrants and mandibular second premolar in third and fourth quadrant. Subject's father showed missing second molars in all four quadrants along with missing right mandibular first molar. Her sister had missing first and second molars in all quadrants while her brother had missing first and second molars, mandibular incisors and second premolars.

The consequences of missing teeth are numerous as causing inconvenience in mastication, speech, etc. Considering the level of complexity in the management of oligodontia patients, treatment should begin with early diagnosis to prevent future functional and esthetic problems.

**Keywords:** Agenesis, Non-syndromic, Hereditary, Oligodontia.

### Access this article online

**Website:**

www.innovativepublication.com

**DOI:**

10.5958/2395-6194.2016.00042.4

for odontogenesis in multicuspid and incisors respectively.<sup>2,3,4</sup>

### Case Report

A 20 yr old female reported with the complaint of difficulty in chewing due to missing posterior teeth and wanted replacement of teeth. Clinical examination revealed generalized missing molars in both arches with missing second premolars in lower arch. Deciduous second molars in lower arch were retained. Orthopantomograph confirmed the agenesis of mandibular second premolars and all molars in the subject. (Fig. 1)

Proband's otherwise healthy father showed missing second and third molars in all quadrants with missing right lower first molar also. (Fig. 2) Subject's sibling sister also reported with generalized missing of all molars. (Fig. 3) Careful case study of pedigree chart revealed that diseased paternal grandmother reportedly had missing molars (Fig. 4). The trait was then seen in three paternal uncles including father, and aunt showing generalized missing of molars. Only one in 5 paternal siblings was found to have normal dentition. One male sibling from paternal uncle showed severe oligodontia with missing multiple anterior teeth in both arches and all molars. (Fig. 5)

### Introduction

Agenesis of teeth in humans is a common congenital anomaly.<sup>1</sup> Anodontia is complete absence of teeth. Hypodontia is absence of 1 to 6 teeth and oligodontia involves absence of more than 6 teeth. Oligodontia shows female predilection with ratio of 3:2 with the incidence varying from 0.08% to 0.16%. Most commonly missing teeth are third molars followed by mandibular second premolars, maxillary lateral incisors, maxillary second premolars and mandibular incisors.<sup>1,2</sup>

Oligodontia has genetic origin but may or may not be associated with a syndrome. Syndromes commonly associated are anhidrotic ectodermal dysplasia, Vander Woude syndrome, Down's syndrome, Pierre Robin syndrome and Ehler Danlos syndrome. The genes expressed in embryonic tissues associated with non-syndromic tooth agenesis are found to be MSX1 and PAX9 genes. These genes play a key role in tooth development, where PAX9 and MSX1 are responsible

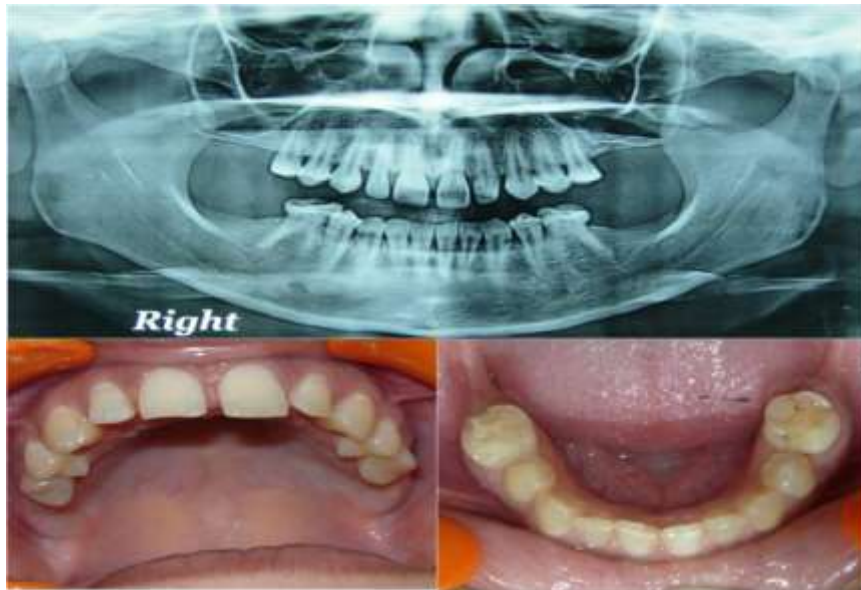

Fig. 1: OPG and clinical pictures show missing permanent molars

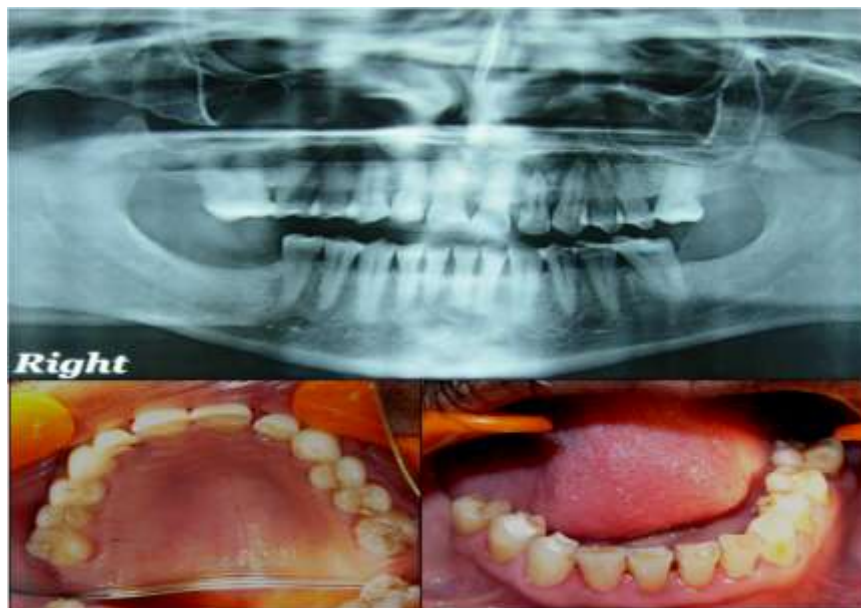

Fig. 2: OPG and clinical pictures show missing molar except 26

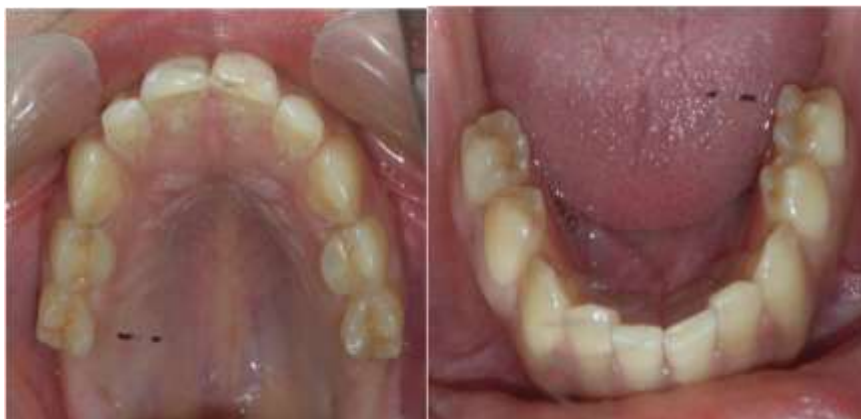

Fig. 3: Clinical pictures show missing molars

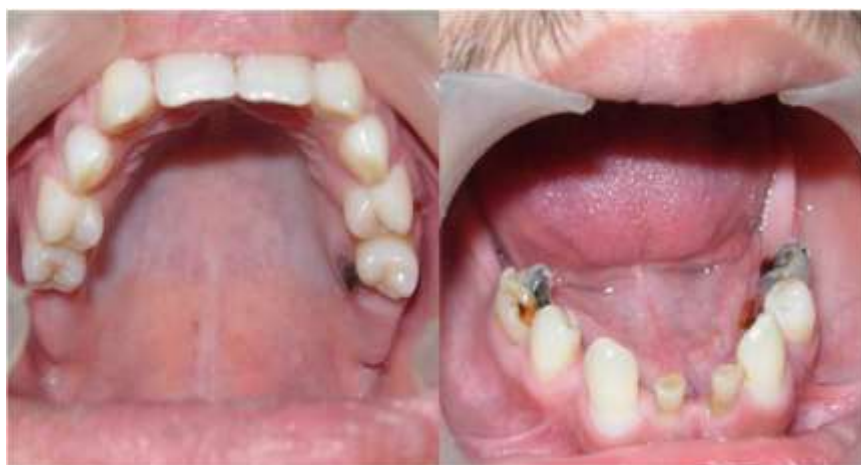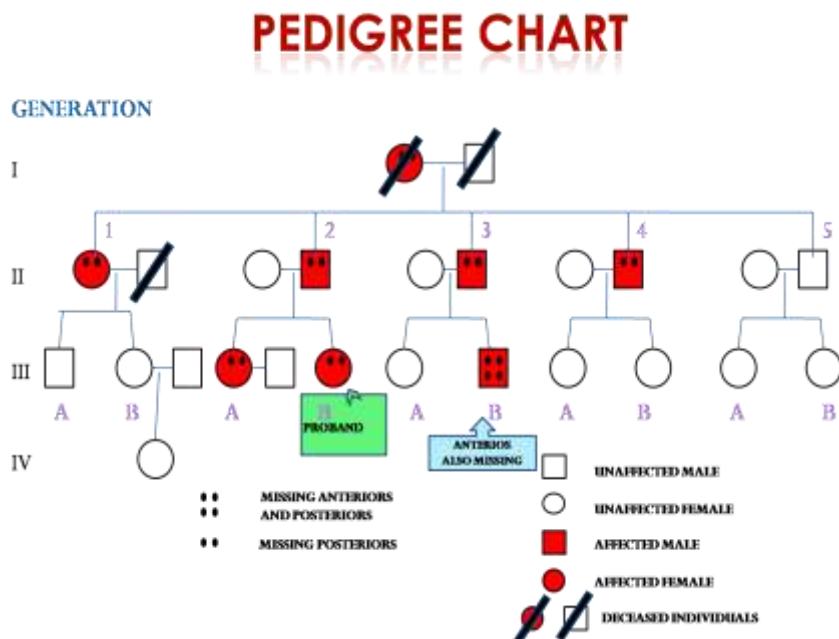


Fig. 5: Clinical pictures show missing posteriors and lower anteriors

### Discussion

Tooth agenesis is a common developmental anomaly. Anodontia, hypodontia and oligodontia are the variants of tooth agenesis.<sup>5</sup> Numerous theories have been proposed in support of congenital tooth agenesis like butler's field theory, Kjaer's neuroosteological developmental fields in the jaws and Svinhufvud's anatomical model. All the above mentioned theories support the fact that the permanent first molars are the most stable teeth in jaws. Only in cases of severe oligodontia or anodontia complete set of molars are found missing.<sup>1,3</sup> Congenital absence of six or more teeth is termed oligodontia. Oligodontia may be seen arising with other syndromes. Isolated oligodontia may be familial or may manifest de-novo.<sup>1,5,6</sup>

Sporadic anomaly may sometimes be seen due to environmental factors like localized infection, trauma,

radiotherapy, chemotherapy or injudicious use of certain drugs.<sup>7</sup>

Genetic mutation in MSX1 and PAX9 gene are associated with missing anterior and posterior teeth respectively. Recently nonsense mutation in the b-catenin binding protein AXIN2 and mutation in EDA gene have also been reported to cause familial oligodontia.<sup>1,4,6</sup> Familial oligodontia can result from single dominant gene defect, Xlinked or recessive.<sup>7</sup> Grahen suggested that agenesis is transmitted through autosomal dominant trait. Penetrance of the trait was higher in the case as they had more than 6 missing teeth.<sup>8</sup>

Same as our case, several studies report bilateral agenesis more common than unilateral agenesis of teeth. Recent studies report maxillary oligodontia more common than mandible. Studies done by Kirzioglu<sup>9</sup>

reported agenesis common in mandible. In our case report both arches have missing teeth. In these cases complete clinical history was recorded with medical and radiological investigations to rule out any syndrome. It is important to make an early and careful diagnosis in the cases with esthetic concern and to avoid dentofacial abnormalities which can lead to psychological or functional discomfort. Multidisciplinary teamwork is required to treat such cases.

### Conclusion

This case reports the rare occurrence of nonsyndromic hereditary oligodontia. Complete case history with detailed medical history and relevant radiographic investigations are required to eliminate association with any syndrome. Correct diagnosis and proper treatment planning helps in rehabilitation of esthetics and function.

### References

1. P Pannu, V Galhotra, P Ahluwaliai, et al. Non-syndromic oligodontia in permanent dentition: A case report. *Ghana Medical Journal* 2014;48:173-176.
2. P Tangade, M Batra. Non syndromic oligodontia: case report. *Ethopia Journal of health Sciences* 2012;22:219-221.
3. M Gupta, S Panda, FA Mutawwam, et al. Diagnosis and management of a patient with congenitally missing maxillary first permanent molars: A rare case report. *Case Reports in Dentistry* 2016;1-3.
4. S Basoya, S Koduri, I Gupta, et al. *Journal of Indian Academy of Oral Medical and Radiology* 2016;22:437-440.
5. P Poornima, AS Shruthi, NB Nagaveni, et al. A case report: Nonsyndromic familial Oligodontia. *International journal of information research and review* 2015;2:853-855.
6. Punithavathy, JB John, Geetha Priya, et al. Familial nonsyndromic oligodontia. *Contemp Clin Dent* 2012;3(2):s188-s190.
7. H Vastardis. The genetics of human tooth agenesis: New discoveries for understanding dental anomalies. *Am J Orthod Dentofacial Orthop* 2000;117:650-656.
8. H Grahnen. Hypodontia in the permanent dentition: a clinical and genetical investigation. *Odont Revy* 1956;7:1-100.
9. Z Kirzioglu, ST Koleser, EMS Ozay, et al. Clinical features of hypodontia and associated dental anomalies: A retrospective study. *Oral Dis* 2005;11:399-404.