

Radicular cyst: case report

Ishank Singhal¹, Pradkshana Vijay^{2,*}, Nilesh Pardhe³, Manas Bajpai⁴

¹Associate Consultant, Dept. of Oral & Maxillofacial Surgery, Indraprastha Apollo Hospital, New Delhi, ²Senior Resident, Faculty of Dental Sciences, KGMU Lucknow, ³Professor & Head, ⁴Senior Lecturer, Dept. of Oral Pathology & Microbiology, NIMS Dental College, Jaipur,

***Corresponding Author:**
Email: vijaydhar38@yahoo.in

Abstract

Radicular cyst of jaws is odontogenic in origin. It is a chronic inflammatory response to the epithelial rest of malassez which occurs in the periodontium of affected teeth. Chronic irritation like chronic trauma, microbial infections or chemical injury can predispose to radicular cyst. We present a case of radicular cyst in 28 years old male patient, with brief review of literature and treatment.

Keywords: Non-vital tooth, Root canal treatment, Enucleation

Access this article online
Website: www.innovativepublication.com
DOI: 10.5958/2395-6194.2016.00045.X

Introduction

A cyst is a pathological cavity usually lined by epithelium, filled with fluid or semifluid material but not pus.^[1] Cysts are classified as developmental or odontogenic. Radicular cysts are odontogenic in origin. Chronic trauma or injuries to teeth irritate the pulp of involved teeth which lead to necrosis and furthermore chronic apical periodontitis which causes cells to proliferate and initiate cystic degeneration.^[2] Among the cysts affecting the jaws, about 65-70% are radicular cysts at the apex of the involved teeth.^[3] Small size cysts are mostly treated conservatively while large size can be treated surgically by enucleation. When the involved tooth is hopeless, enucleation of the cyst followed by extraction of involved tooth is recommended.^[4] The cystic wall must be totally enucleated to remove all epithelial remnants to prevent recurrence of the lesion. We report a case of radicular cyst involving mandibular anterior region in 28 years old male patient.

Case Report

A 28 years old male patient reported with a chief complaint of swelling in the mandibular anterior region of the jaw since 1 month. On further questionnaire, patient confirmed history of trauma 3 years back. Inspectory findings revealed swelling of lower incisors, discoloration of four mandibular incisors. Palpation showed grade I mobility of the lower incisors. Intraoral periapical radiograph revealed a well-defined radiolucency involving periapical region irt 31, 32 and

41, 42. A well-defined sclerotic border was present around the radiolucency irt 31,32,41,42. Routine blood examinations reports were normal. Based upon clinical and radiographic findings a provisional diagnosis of periapical cyst irt 31,32,41,42 was made. Surgical enucleation of cyst with curettage was done followed by endodontic treatment irt 31,32,41,42. Following this, histopathological evaluation was done which revealed nonkeratinized stratified squamous epithelium with arcading pattern. The underlying connective tissue was dense fibrocollagenous and consisted of severe inflammatory cell infiltrate chiefly lymphocytes and plasma cells. At few areas globular, eosinophilic structures suggestive of Russell bodies were also noted. Correlating the overall features, a final diagnosis of Radicular cyst was made.

Patient was under 6 months follow up and no recurrence or complications were noted.

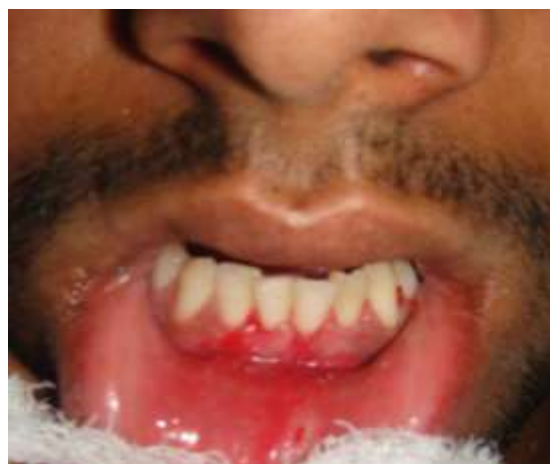

Fig. 1: Intraoral examination showing erythematous area with inflamed gingiva irt 31, 41, 42

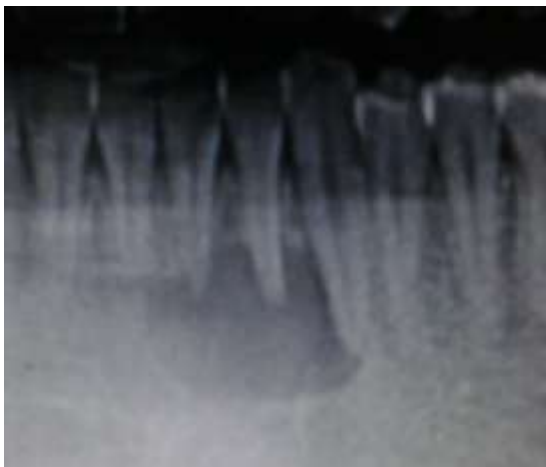

Fig. 2: Intraoral periapical radiograph showing well defined radiolucency with sclerotic border irt 31, 32, 41, 42

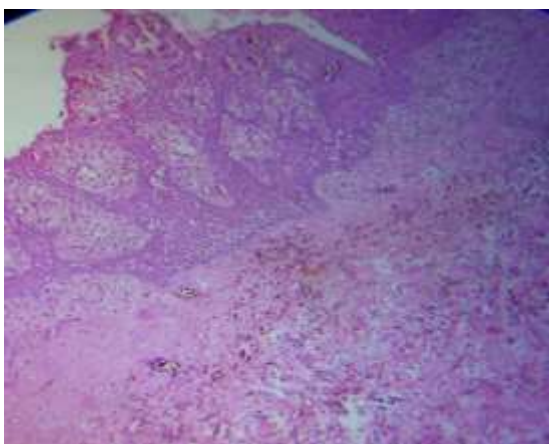


Fig. 3: Photomicrograph showing nonkeratinized stratified squamous epithelium with arcading pattern. Underlying connective tissue stroma shows severe chronic inflammatory cell infiltrate

Discussion

Radicular cyst also known as periapical cyst, root end cyst or dental cyst, originates from epithelial cell rests of malassez in periodontal ligament because of inflammation due to trauma or pulp necrosis which was in concurrence with the present case that reported history of trauma.^[2] Occurs more commonly between third and fifth decades in males and more frequently found in the anterior maxilla.^[3] In the present case, radicular cyst was involving the mandibular anterior in contradiction to reported cases involving anterior maxilla. Pathogenesis of radicular cysts has been described as consisting of three distinct phases: the phase of initiation, the phase of formation and the phase of enlargement.^[4] Radicular cysts are generally asymptomatic and are detected by radiography but long standing cases may show an acute exacerbation of the cystic lesion and develop signs and symptoms like swelling, tooth mobility and displacement of unerupted

tooth.^[5] Present case also showed swelling, pain and mobility of lower anteriors. Associated teeth are non-vital and show discoloration.^[6] Radiographically radicular cyst appears as round radiolucent lesion in the periapical region.^[7,8] The choice of treatment depends on extension of the lesion, relation with noble structures, clinical characteristics of the lesion, and systemic condition of the patient. Treatment options for radicular cysts may be conventional, nonsurgical RCT when lesion is confined to a small area or surgical treatment like enucleation, marsupialization or decompression in case of larger lesions^[9]. This case report presents surgical enucleation of large radicular cyst alongwith root canal treatment.

Histologically, radicular cysts are lined by nonkeratinized stratified squamous epithelium. The lining may be discontinuous ranging in thickness from 1-50 cell layers. In the early stages, epithelium lining may be proliferative and shows arcading with intense chronic inflammatory infiltrate. As the cyst enlarges, the lining becomes quiescent with a certain degree of differentiation and resembles simple stratified squamous epithelium. Inflammatory cell infiltrate in the proliferating epithelium consists chiefly of PMN's.^[10,11]

Conclusion

Various treatment options have been recommended depending on the size and location of cyst. Large lesions endodontic treatment is followed by surgical enucleation however some authors propose nonsurgical management of small lesions. This case presents surgical management of a large radicular cyst with endodontic treatment.

References

1. Aslan M, Şimşek G. Large residual dental cyst (A case report). *The Journal of the Dental Faculty of Ataturk University*. 2002;12(3):45-49.
2. Lim AA, Peck RH. Bilateral mandibular cyst: Lateral mandibular cyst, paradental cyst, or mandibular infected buccal cyst? Report of a case. *J Oral maxillofac Surg*. 2002;60(7):825-27.
3. Shafer's textbook of oral pathology, 6th ed, 487-490.
4. Shear M. *Cysts of the Oral Regions*. 2nd ed. Bristol: John Wright and Sons, 1983.
5. Joshi. N, Sujan S, Rachappa M. An unusual case report of bilateral mandibular radicular cysts. *Contemporary Clinical Dentistry* 2011;2(1):59-62.
6. Jansson L, Ehnevid H, Lindskog S, Blomlöf L. Development of periapical lesions. *Swedish Dental Journal* 1993;17(3):85-93.
7. Mass E, Kaplan I, Hirshberg A. A clinical and histopathological study of radicular cysts associated with primary molars. *J Oral Pathol Med* 1995;24:458-61.
8. Lustmann J, Shear M. Radicular cysts arising from deciduous teeth: Review of the literature and report of 23 cases. *International Journal of Oral Surgery* 1985;14(2):153-61.
9. Shear M. *Cysts of the oral regions*. 3rd ed. Boston: Wright, 1992,136-70.

10. Cawson RA, Odell EW, Porter S. Cawson`s essentials of oral pathology and oral Medicine. 7th Ed, Churchill Livingstone, Edn, 2002,102-21.
11. Natkin E, Oswald RJ, Carnes LI. The relationship of lesion size to diagnosis, incidence and treatment of periapical cysts and granulomas. Oral Surgery, Oral Medicine, Oral Pathology 1984;57(1):82-94.