

## The HPV connection – correlation of oral papillomas in husband and wife

Juhi Hussain<sup>1\*</sup>, Mohammad Iqbal<sup>2</sup>, Mohd. Abu Khan<sup>3</sup>, Satya Prakash Gupta<sup>4</sup>

<sup>1,2</sup>Senior Lecturer, <sup>3,4</sup>PG Student, <sup>1</sup>Dept. of Oral Medicine & Radiology, <sup>2,3</sup>Dept. of Conservative Dentistry & Endodontics, Rama Dental College Hospital & Research Centre, Kanpur, <sup>4</sup>Dept. of Oral & Maxillofacial Surgery, Chandra Dental College, Lucknow

**\*Corresponding Author:**

Email: juhihussain@yahoo.com

### Abstract

Literature analysis confirms the link between Human Papilloma Virus (HPV) and benign lesions of the oral cavity such as papillomas, condilomas and oral warts. Factors that contribute to increased HPV prevalence in the oral cavity are – reduction in host immune response for the virus, having more than one sexual partner and practice of oral sex. HPV diagnosis in the oral mucosa may be done by clinical examination of the lesion, family history, cytology and biopsy, however molecular biology allows detection of HPV DNA in cell, Polymerase Chain Reaction (PCR) being the most sensitive method for detection.

We report two cases of HPV linked squamous papilloma in husband and wife on the same unusual site in the oral cavity (hard palate), contemplating saliva to be a possible mode of transmission as the patients had no genital lesions with emphasis on diagnostic methods, treatment, recurrence and complications of such lesions.

**Keywords:** Human Papilloma Virus, Squamous Papilloma, Hard Palate, Polymerase Chain Reaction.

### Introduction

Papillomatous and verrucous skin and genital lesions described since ancient Greece and Rome. In 1842, Italian physician Rigoni-Stern noted a high frequency of cervical cancer in married women, widows and prostitutes, but their rare occurrence in virgins and nuns. In 1983 & 1984, the first HPV types (HPV 16 and 18) were isolated from cancer biopsies of the cervix and were cloned.<sup>(1)</sup> Papilloma viruses are epitheliotropic viruses of which several types have been discovered so far.

They are members of the Papillomavirus family and together with Polyomaviruses form the species Papovaviridae.<sup>(2)</sup>

These types have been divided into two categories according to those causing mucosal/ genital lesions (40 types) and those causing non mucosal cutaneous lesions (60 types). The first category is further subdivided into high risk types- type 16, 18, 31 and 45 mainly causing anogenital cancers and its precursors and low risk types –type 6 and 11 mainly, causing benign genital and oral warts.

Transmission occurs from the following routes- Skin-to-skin contact with an infected individual, from vaginal, oral, or anal sexual contact, and can occur whether or not warts or other symptoms are present, vertical transmission, nonsexual routes.<sup>(3)</sup>

Squamous papilloma is an exophytic growth of the oral cavity commonly occurring between age 30 and 50 years. It is divided into two types: Isolated-solitary and multiple-recurring, the former being confined to an adult's oral cavity. Although tongue is the most prone area, it can also occur on the palate, buccal mucosa, gums, lips, tonsils and uvula.<sup>(4)</sup> It is mainly caused by HPV types 6 and 11.<sup>(5)</sup>

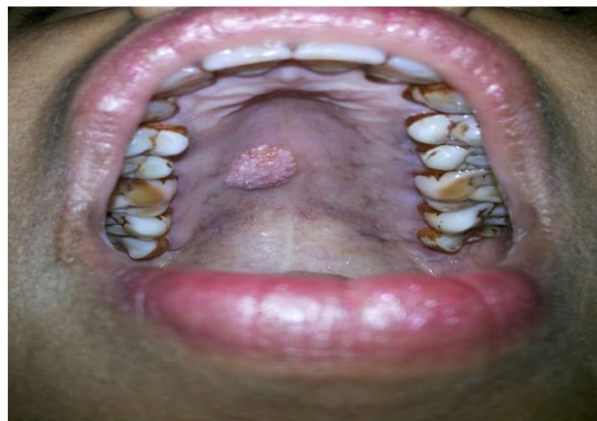The following case reports are of a couple who had identical growths on their hard palate provisionally diagnosed as Squamous Papilloma.

### Case Reports

#### Case 1

A 32 year old female reported with the chief complaint of a growth in the palate region since 6 months. The growth had been gradually increasing in size and caused discomfort during eating. She gave a history that her husband also had a similar growth on his palate.

On intra-oral examination, a solitary growth was present on the posterior hard palate, towards the right of the midline. Growth was roughly ovoid in shape, approximately 2 cm in diameter, pink in color with a lobulated surface giving a cauliflower like appearance. On palpation, it was pedunculated in nature, soft and firm in consistency and non tender to touch. (Fig. 1)



**Fig. 1: Intraoral Clinical Appearance (Case 1)**

**Case 2**

Patient's husband was called on subsequent visit. He was 38 years old and a driver by profession. He gave a history of a growth being present on the palate since 4 years which was painless. He was also a chronic smoker.

Intra oral examination revealed a similar growth on the posterior hard palate, right to the midline. Clinical appearance of the growth was almost the same as in the previous case. (Fig. 2)

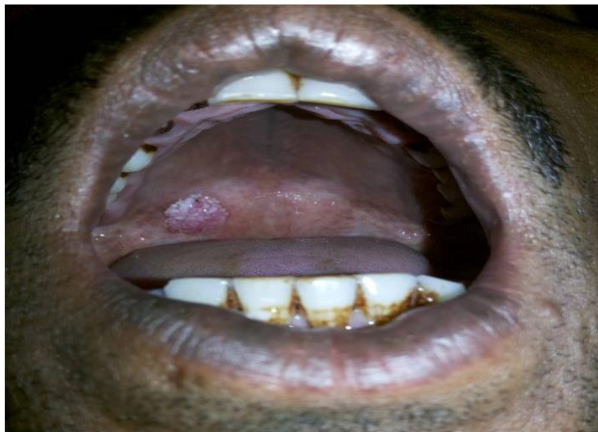Both patients had no genital lesions on examination.

Both the cases were provisionally diagnosed as Squamous papilloma. Surgical excision under Local Anesthesia was performed (Fig. 3 & 4) after routine laboratory blood investigation reports were found within normal limits in both cases.

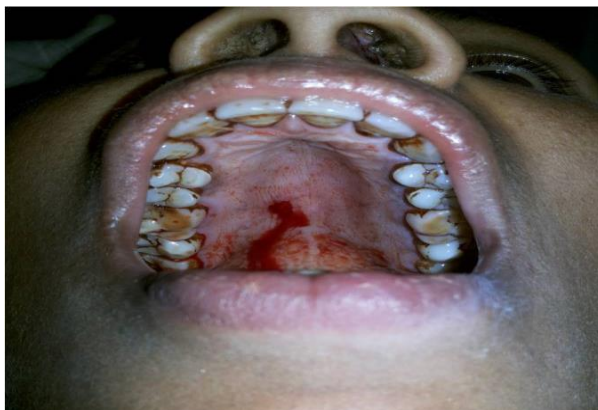Specimens obtained were sent for histopathological and microbiological examination (Fig. 5 & 6). Reports were confirmatory of squamous papilloma. Hematoxylin and Eosin stained sections revealed squamous epithelium in an arrangement of finger like projections, hyperparakeratosis in epithelium and koilocytosis and pyknosis. (Fig. 7 & 8)

DNA extraction using Polymerase Chain Reaction showed HPV type 11 to be present in both specimens.

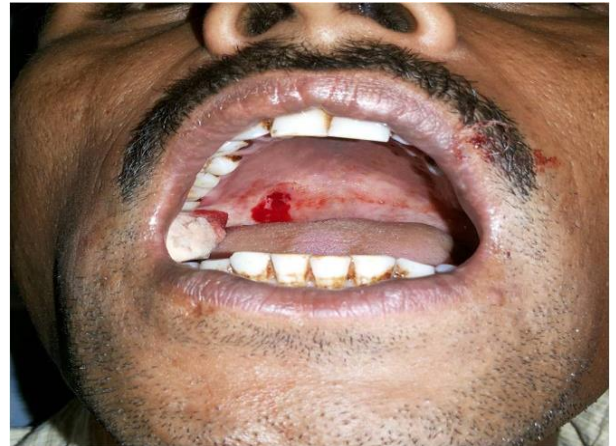Patients were on follow up with us for 1 year and there was no recurrence till then.



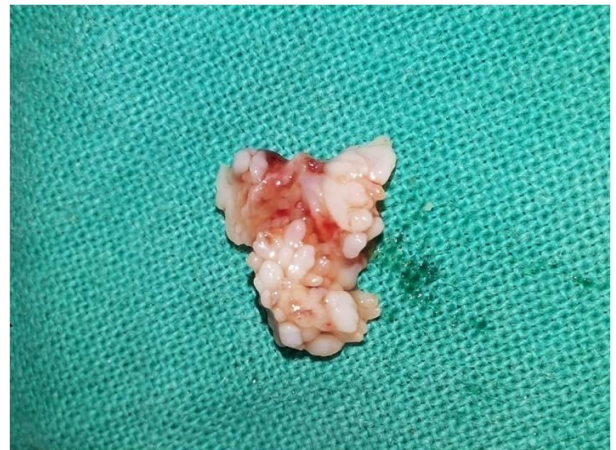**Fig. 2: Intraoral Clinical Appearance (Case 2)**



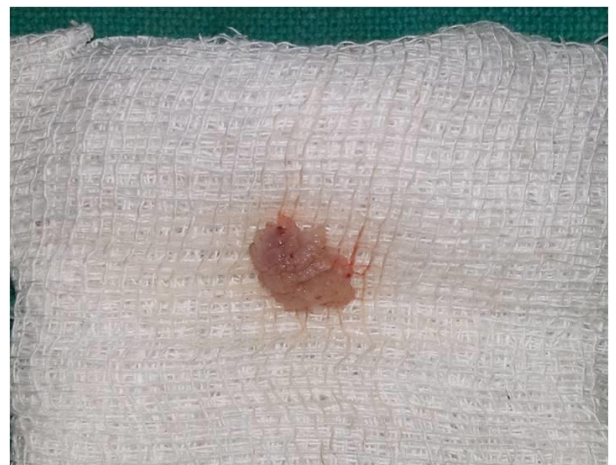**Fig. 3: After surgical excision (Case 1)**



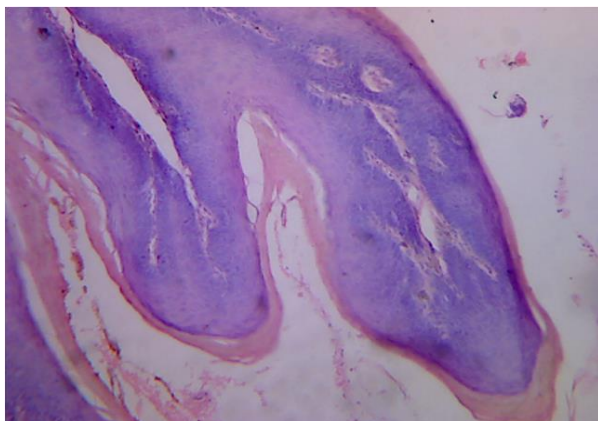
**Fig. 4: After surgical excision (Case 2)**



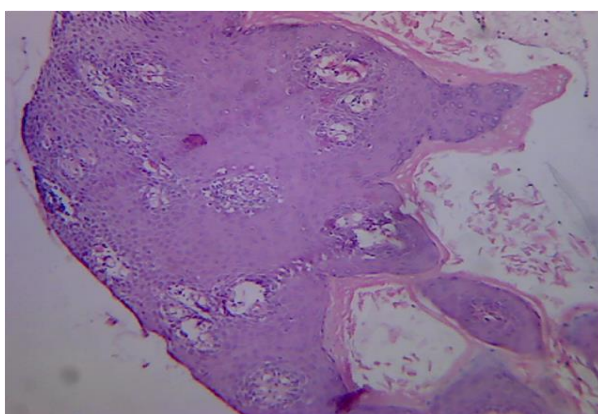
**Fig. 5: Gross specimen (Case 1)**



**Fig. 6: Gross specimen (Case 2)**



**Fig. 7: Histopathological appearance (Case 1)**



**Fig. 8: Histopathological appearance (Case 2)**

## Discussion

HPV is a major cause of concern as the causative factor for cervical cancers around the world among the medical fraternity. However, dentists may encounter mostly oral lesions caused by HPV in day to day practice. HPV in the oral cavity may manifest as the following: Squamous Papilloma, Condyloma Acuminatum, Verruca Vulgaris, and Focal Epithelial Hyperplasia/ Hecks Disease.<sup>(5)</sup> These are benign in nature.

Condyloma acuminatum/ venereal wart is generally regarded as a sexually transmitted disease affecting the skin and mucous membranes of the anogenital tract. Oral condylomas are rare and associated most often with the low-risk HPV types 6 and 11, and less commonly with the high-risk types 16, 18, 31, 33, and 35.<sup>(5)</sup>

Verruca vulgaris or common wart is the most prevalent HPV lesion of the skin, but is also found in oral mucosa. They appear as firm, whitish, sessile circumscribed exophytic lesions. The most common HPV type found in oral warts is HPV 2 followed by HPV 57.<sup>(5)</sup>

Focal Epithelial Hyperplasia presents clinically as multiple, isolated, pink, dome shaped nodules separated by normal oral mucosa. HPV types 13 and 32 have been detected in most of these lesions.

Diagnosis in the oral mucosa may be done by clinical examination of the lesion, family history, cytology and biopsy; however molecular biology allows detection of HPV DNA in cell, Polymerase Chain Reaction (PCR) by target amplification being the most sensitive method.<sup>(5)</sup>

The importance of patient history and clinical examination is clearly highlighted in our cases as diagnosis in one patient led to diagnosis and subsequent treatment of patient's husband too.

Other methods include Probe Amplification, Signal Amplification and Southern and Dot Blot Hybridization.<sup>(5)</sup>

Surgical removal is the treatment of choice, either by surgical or electrocautery excision, cryosurgery, intralesional injections of interferon or laser ablation. Other treatment options include clinical application of chemical agents such as Imiquimod (Aldara), Trichloroacetic acid 40-90%, Podophyline 25% and 5 – fluoracil.<sup>(6)</sup>

The recurrence rate is very low for the solitary type. Squamous cell Carcinoma and Verrucous Carcinomas are the rare complications of such lesions.<sup>(5)</sup>

As a common saying goes - Prevention is better than cure, Vaccines have been developed for protection from the several HPV types.<sup>(7)</sup> The first HPV vaccine was approved by US FDA in 2006. CERVARIX is a bivalent recombinant vaccine providing protection against HPV types 16 and 18, GARDASIL is quadrivalent recombinant vaccine providing protection against HPV types 6, 11, 16 and 18 and GARDASIL 9 is a ninevalent recombinant vaccine which provides protection against HPV types 6, 11, 16, 18, 31, 33, 45, 52, 58. For Cervarix catch up vaccination is permitted upto 26 years in female population at 0, 1 and 6 months whereas for Gardasil, routine vaccination is done in adolescent girls upto 12 years at 0, 2 and 6 months.<sup>(7)</sup>

## Conclusion

Presence of oral squamous papilloma in husband & wife in the oral cavity at the same site was an astonishing clinical presentation as both the patients had no genital lesions. Further research is required on saliva as the mode of transmission of HPV. Also, early diagnosis of oral lesions can prevent further complications in such cases. In addition, vaccination against HPV needs to be promoted at large levels across the country.

## References

1. Harald zur Hausen. Papilloma viruses in the causation of human cancers- a brief historical account. *Virology* 384(2009)260-265.
2. Saraswati Naik, Madhumati Nidoni. Oral squamous papilloma of the palate- A case report. *International Journal Of Dental Sciences and Research*, 2014;2(6):17-18.
3. Helena Lucia B. dos Reis, Priscila C. Rabelo, Maria Rúbia F. de Santana, Dennis Carvalho Ferreira, Antônio C. Filho. Oral squamous papilloma and condyloma acuminatum as

- manifestations of buccal-genital infection by human papillomavirus. *Indian J Sex Transm Dis.* 2009 Jan-Jun; 30(1):40–42.
4. Prashant Babaji, Vikram Singh, Vishwajit Rampratap Chaurasia, Vinay Kumar, S Masamati, Akanksha Manmohan Sharma. Squamous papilloma of hard palate. *Indian J Dent.* 2014 Oct-Dec; 5(4):211-213.
  5. H Singh, P Kumar, A Kumar. Possible role of Human Papilloma Virus in oral diseases-An Update. *The Journal of Infectious Diseases*, 2010;9(2).
  6. Helena Lucia B dos Reis, Priscila C Rabelo, Maria Rubia F de Santara, Dennis Carvalho Ferreira and Antonia C Filho. Oral squamous papilloma and condyloma acuminatum as manifestations of buccal-genital infection by Human Papilloma Virus. *Indian J Sex Transm Dis.* 2009 JAN-Jun; 30(1):40-42.
  7. Aruna Nigam, Pikee Saxena, Anita S. Acharya, Archana Mishra, Swaraj Batra. HPV Vaccination in India: Critical Appraisal. *Obstetrics and Gynecology.* 2014, Article ID 394595,5.