

Peripheral cementifying fibroma of the maxilla: Report of 2 cases with review of literature

Ruchika Khanna^{1,*}, Nisha Dua², Varun Chopra³, Gurinderbir Singh⁴

^{1,4}Senior Lecturer, ^{2,3}Reader, ^{1,2}Dept. of Oral Medicine & Radiology, ^{3,4}Dept. of Oral Maxillofacial Surgery, Sri Sukhmani Dental college and Hospital, Derabassi, Punjab

***Corresponding Author:**

Email: mini_coolsm124@yahoo.com

Abstract

Peripheral Cementifying fibroma being a reactive lesion affects women more commonly and is found in the anterior maxillary and mandibular region. The two cases discussed here were asymptomatic clinically and on surgical excision showed fibrous cellular connective tissue stroma with calcified osseous cementum like calcifications. Two cases of young male adults with peripheral cementifying fibroma are reported here with the review of literature.

Introduction

Peripheral cementifying fibroma is a common growth on the gingiva that is considered to be reactive. It is also known as peripheral odontogenic fibroma, calcifying or ossifying fibroid epulis. It is also considered to be a solitary growth on the gingiva that is thought to arise from periodontal ligament at the region of interdental papilla.⁽¹⁾ Peripheral ossifying fibroma was coined by Eversole and Ravin in the year 1972.⁽²⁾ There are two types of ossifying fibroma: central type which arises from the endosteum or periodontal ligament adjacent to the root and peripheral type that occurs on the soft tissue covering tooth bearing areas of the jaw.⁽³⁾ It accounts for 3.1% of all the tumors and 9.6% of all the gingival lesions.⁽⁴⁾ Some peripheral ossifying fibroma are believed to develop from pyogenic granuloma that undergo fibrous maturation followed by calcification. Local irritating factors like calculus, ill fitting denture appliance and faulty restoration are known to precipitate the lesions. The calcification occurs from periosteal cells or from periodontal ligament.⁽⁵⁾ It usually appears as a nodular mass which is either pedunculated or sessile. The colour of the lesion usually varies from pink to red and the overlying surface is ulcerated at times. The predilection for the site of occurrence is the maxillary arch (60%) and the incisor-cuspid region (50%) but is also seen in the mandibular region. On reviewing literature it is seen to affect both the genders with a slighter higher predilection for the females. Peak incidence of occurrence is around second to third decade of life.⁽⁶⁾

roughly oval in shape, present on the gingiva irt 14, 15, reddish pink in colour buccally as well as on the palatal mucosa, measuring 2X2 cm in size approx. Sessile in nature, surrounding mucosa appeared normal. On palpation the growth was firm in consistency, smooth in texture, non-tender. The teeth were non tender on percussion. A provisional diagnosis of Peripheral ossifying fibroma was made with a differential diagnosis of irritational fibroma, pyogenic granuloma, peripheral giant cell granuloma. IOPA revealed erosion of the alveolar crest interproximally irt 14, 15, 16. Maxillary crosssectional view did not show any significant finding. Complete heamogram was advised which showed all the blood counts within normal limits. After acquiring patient's informed consent an excisional biopsy was performed both on the buccal as well as the palatal side. The healing was uneventful and the excised tissue was sent for histopathological analysis. Histopathological examination revealed under low magnification epithelium overlying cellular connective tissue stroma with ossifications and under higher magnification keratinized stratified squamous epithelium. Connective tissue stroma showed large number of plump proliferating fibroblasts & few inflammatory cells. Stroma also shows bony spicules & calcifications. A final diagnosis of Peripheral Cementifying fibroma was given.

Case Report

Case 1: A 17 year old male patient visited the department of Oral Medicine and Radiology with a chief complaint of presence of a growth in the right upper back tooth region since 1 month. The growth was gradual in onset and had reached the present size. There was no relevant past dental and medical history. Extra oral examination revealed no significant findings. On intraoral examination a solitary, well defined growth,

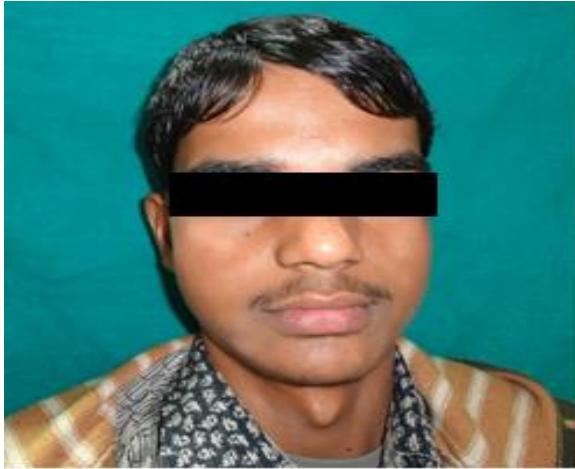

Fig. 1: Profile photo of the patient

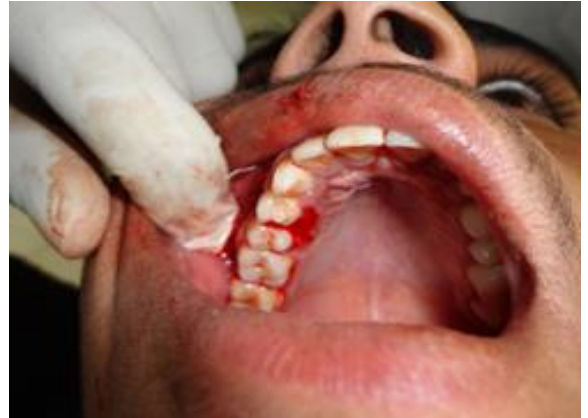

Fig. 4: Surgical excision of the growth

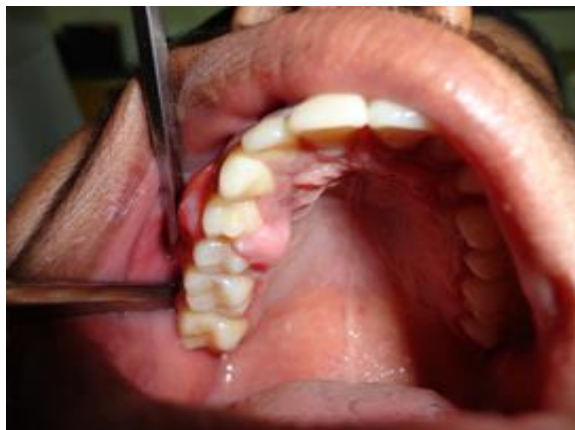

Fig. 2: Growth on the gingiva palatally and buccally irt 14, 15

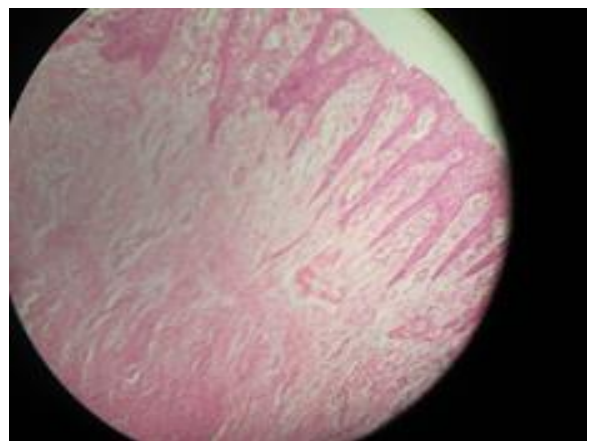


Fig. 5: Photomicrograph showing connective tissue with inflammatory cells and stroma with ossification

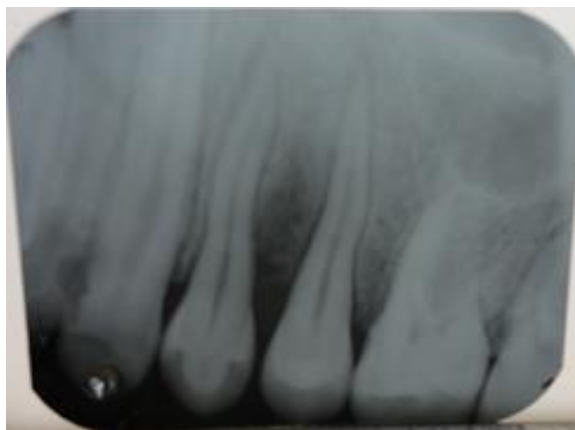


Fig. 3: IOPA showing erosion of the alveolar crest irt 14, 15 interproximally

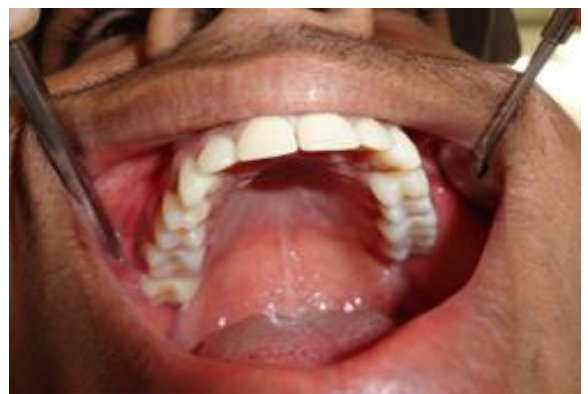

Fig. 6: Post-surgical follow up after a month

Case 2: A 23 old male patient reported to the Department of Oral medicine and radiology with a chief complaint of presence of a growth in the upper front tooth region past 1 month. The growth present was gradual in onset which had reached the present size. No relevant dental or medical history was present. No significant finding was present extra orally. Intraorally a well-defined, solitary, pedunculated roughly oval in shape present on the gingiva irt 21, 22, 23 palatally measuring approximately 2X3 cms in size palatally, haemorrhagic. Overlying

surface is rough. Surrounding mucosa appears normal. On palpation growth was found to be soft in consistency and non tender. Grade I mobility was present irt 22. A provisional diagnosis of Pyogenic granuloma was made with a differential diagnosis of fibroma, peripheral giant cell was given. IOPA revealed erosion of the alveolar crest irt 22 and 23 interproximally. Complete haemogram showed all blood counts under normal limits. After patient's consent an excisional biopsy was done and tissue was sent for histopathological investigation. The healing was uneventful. Histopathology report revealed parakeratotic stratified squamous epithelium overlying fibrous connective stroma. The stroma exhibits abundance of ossifications, few endothelial lined blood vessels, inflammatory cells, predominantly lymphocytes. Suggestive of Peripheral Cementifying fibroma was given.

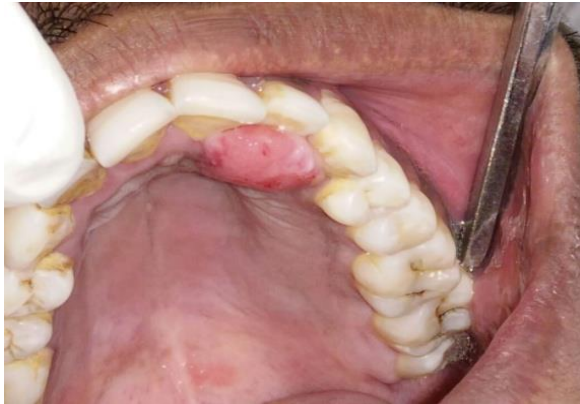

Fig. 1: Growth on the gingiva palatally irt 21, 22, 23

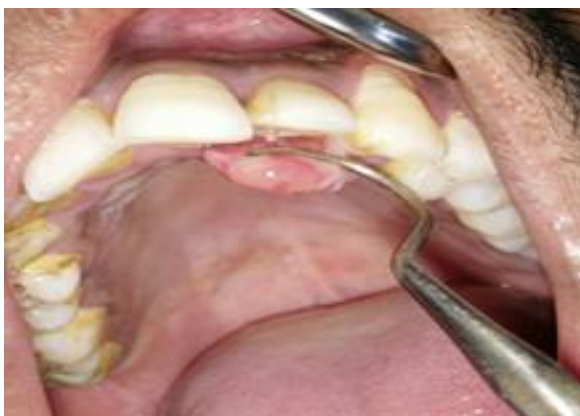

Fig. 2: Pedunculated growth palatally irt 21, 22, 23

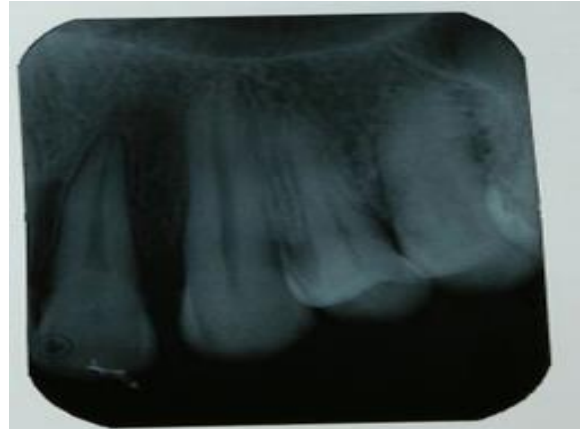

Fig. 3: IOPA showing erosion of the alveolar crest irt 22, 23 interproximally

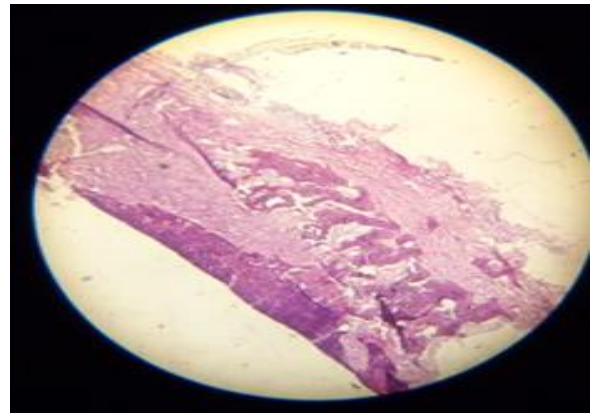


Fig. 4: Photomicrograph exhibiting stroma with abundance of ossifications, few endothelial lined blood vessels

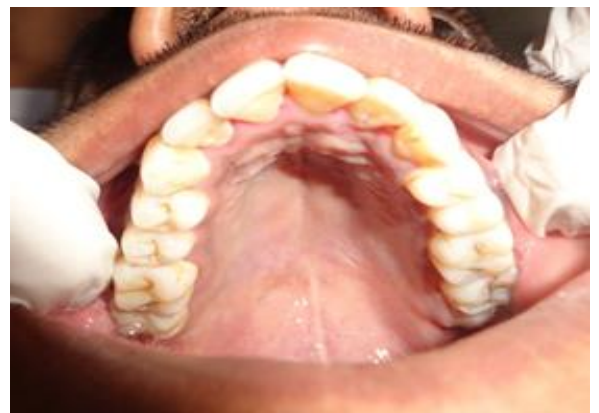

Fig. 5: Post-surgical follow up after a month

Discussion

The term cemento ossifying fibroma has been regarded to be scientifically inaccurate⁽⁷⁾ as the histologic presentation of cemento ossifying fibroma is the same where there is no cementum such as the femur, tibia and skull. Cemento ossifying fibroma is the term used for fibromas having a round basophilic bone particles in the ossifying fibromas randomly been called

as cementicles. Peripheral cementifying fibroma being a reactive lesion is a non-neoplastic lesion having an unknown etiology. Kumar et al (2006) suggested a possible origin from the cells of periodontal ligament. The reason for their hypothesis included the occurrence of POF in the gingiva (interdental papilla) and its proximity to periodontal ligament with presence of oxytalan fibres within mineralized matrix of such lesions. It occurs exclusively on the gingiva, close to the periodontal ligament. Peripheral ossifying fibromas usually contain fibrous connective tissue, endothelial proliferative tissue. The recurrence rate of POF is 7-45% and is considerably high for a benign, reactive growth.⁽⁸⁾ Therefore, complete excision is the preferred management of POF. It is probably due to incomplete initial removal of the lesion, repeated injury and persistence of irritants which leads to possible re-occurrence. Das and Azar 2009 reported the first interval time of reoccurrence to be 12 months. There is a slight female predisposition of POF and most commonly found in the maxillary anterior i.e. inciso-cuspid area and in the second decade of life.⁽⁹⁾ Hormonal imbalance may influence the occurrence in females more which declines with advancing age. (Kenney et al 1989).

It is usually a slow growing nodular mass which is either pedunculated or sessile with a smooth or ulcerated surface and red or pink in colour. It has been reported to occur exclusively on gingiva accounting for 3.1% of all the oral tumors and 9.1% of gingival lesions.⁽¹⁰⁾ Similarity in the clinical appearance of various lesions makes histopathological examination important. Radiographic changes are not apparently seen except for occasional foci of radiopaque material may be seen with overt mineralization. Histologically, reveal non encapsulated masses of cellular connective tissue with randomly distributed calcifications. The mineralized product originates from periosteal cells or periodontal ligaments.⁽¹¹⁾ Farquhar et al 2008 found the mineralized component of peripheral ossifying fibroma to vary from 23% to 75%.

Conclusion

A slowly growing soft tissue mass in the oral cavity of children or young adults present in the anterior region should raise the suspicion of a reactive lesion such as POF, fibroma or a Peripheral giant cell granuloma which are usually associated with poor oral hygiene or periodontal disease. In majority of the cases no underlying bone involvement is seen on a radiograph. Treatment usually includes surgical excision and if left untreated it may interfere with normal chewing. Hence prompt treatment is necessary.

References

1. Bhaskar SN, Jacoway JR. Peripheral fibroma and peripheral fibroma with calcification: report of 376 cases. *J Am Dent Assoc.* 1966;73(6):1312-20.
2. Savetha A, Veerandra K, Deepika J. A Case report on Peripheral cementifying fibroma. *JIADS.* 2011;2(1).
3. Keluskar V, Bayakodi R, Shah N. Peripheral Ossifying fibroma. *J Indian Acad Oral Med Radiology.* 2008;20:54-56.
4. Martins Junior Jc, Keim FS, Kreibich MS. Peripheral ossifying fibroma of the maxilla: a case report. *Int Arch Otolaryngol.* 2008;12:295-99.
5. Delbem A, Cunha R, Silva J, Soubhai A. Peripheral cementifying fibroma in child. A follow up of four years. *Eur J Dent.* 2008;2:134-37.
6. Buchner A, Hansen LS. The histomorphologic spectrum of peripheral ossifying fibroma. *Oral Surg Oral Med Oral Pathol.* 1987;63:452-61.
7. Marx RE, Stern D. *Oral and Maxillofacial pathology: A rationale for diagnosis and treatment.* 2003. Quintessence Publishing. Illinois. 879.
8. Poon CK, Kwan PC, Chao SY. Giant peripheral ossifying fibroma of the maxilla: report of a case. *J Oral Maxillofac Surg.* 1995;53:695-698.
9. Bhaskar SN, Jacoway JR. Peripheral fibroma and peripheral fibroma with calcification: report of 376 cases. *J Am Dent Assoc.* 1966;73(6):2-20.
10. Walters JD, Will JK, Hatfield RD, Cacchillo DA, Rabbe DA. Excision and repair of peripheral ossifying fibroma. A report of 3 cases. *J Periodontol.* 2001;72(7):939-44.
11. Botazzo Delbem AC, Cunha RF, Silva JZ, Pires Soubhia AM. Peripheral Ossifying fibroma in child. A follow up of 4 years. Report of a case. *Euro J Dent.* 2008;2(2):34-7.