

## Synchronous squamous cell carcinoma of the lips: A literature review & case report

Riaz Abdulla<sup>1</sup>, Durbakula Karteek<sup>2</sup>, M. Muhaseena<sup>3</sup>, Mandeep Kaur<sup>4,\*</sup>

<sup>1</sup>Professor, <sup>2,3</sup>PG Student, Dept. of Oral & Maxillofacial Pathology, Yenepoya Dental College, Yenepoya University, Mangalore, Karnataka, <sup>4</sup>Associate Professor & Incharge, Dept. of Oral Medicine & Radiology, Faculty of Dentistry, Jamia Millia Islamia, New Delhi

**\*Corresponding Author:**

Email: drmandeepsandhu@gmail.com

### Abstract

Oral cancer is the sixth most common cancer worldwide accounting for 2–4% of all cancer cases. Second primary tumors (SPT), are considered to be a poor prognostic indicator for overall survival. Synchronous tumors are the SPTs that occur simultaneously or within 6 months of the index tumor. Synchronous squamous cell carcinoma frequently occurs in oral cavity (39%) with incidence rates of the lip ranging from 10 – 18%. SPTs are usually aggressive in nature with early metastasis and therefore require more aggressive treatment. We report a rare case of synchronous oral squamous cell carcinoma occurred in a relatively young patient (< 40 years) involving both upper and lower lips with literature review focusing on the pathogenesis and various studies that reported synchronous Oral Squamous Cell Carcinomas of the lip.

**Keywords:** Squamous cell carcinoma; Second primary tumor; Synchronous tumor; Field cancerization; Patch theory; Vertical recruitment.

### Introduction

Oral cancer is the sixth most common cancer worldwide accounting for 2–4% of all cancer cases.<sup>(1)</sup> In India, Oral Squamous cell carcinoma (OSCC) ranks among the top three cancers and its rate is as high as 20 per 100,000 population and accounts for over 30% of all cancers.<sup>(2)</sup>

Second primary tumors (SPT), are considered to be a poor prognostic indicator for overall survival whose incidence rates varies between 2-30%.<sup>(3)</sup> Synchronous tumors are the SPTs that occur simultaneously or within 6 months of the index tumor while metachronous tumors occur with a time gap of more than 6 months in most of the cases.<sup>(4)</sup> These SPTs are usually aggressive in nature with early metastasis and therefore require more aggressive treatment.<sup>(5)</sup>

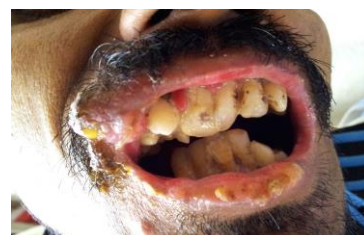We report a rare case of synchronous oral squamous cell carcinoma involving both upper and lower lips.

### Case Report

A 39 year old male patient reported with a chief complaint of painful mass on both upper and lower lips since 2 years. The lesion started as a shallow ulcer on the upper lip which gradually progressed into a proliferative mass. A similar lesion developed 3 months later on the lower lip. The patient also complained of difficulty in eating spicy food, loss of appetite and weight. The history of tobacco chewing habit since 14 years was also given.

General examination revealed that the patient was poorly built and malnourished. Extra oral examination revealed ulcero-proliferative growth on both upper and lower lips with restricted mouth opening (Fig. 1). The lesion on the upper lip measured 4x3 cm in size extending medially 1cm from the right commissure and

the lower lip lesion measured 3x1 cm in size in the midline region. There was a separation of 3 cm normal tissue between the lesions of the upper and lower lip. On palpation, submandibular lymph nodes on both the sides were palpable, soft, non-tender, and mobile measuring 1x1 cm in size. On intra oral examination, the oral hygiene was very poor with staining and calculus deposition. Crowding and malocclusion of the teeth was also noticed.

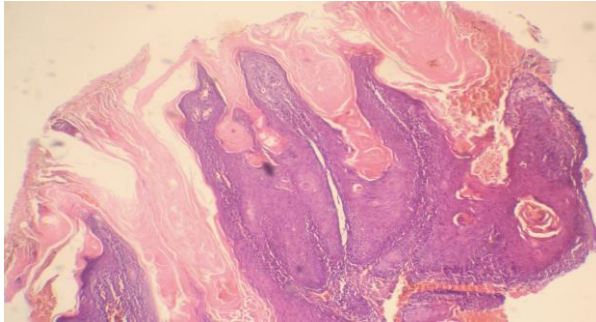


**Fig. 1: Lesions showing ulcero-proliferative growth on upper and lower lips**

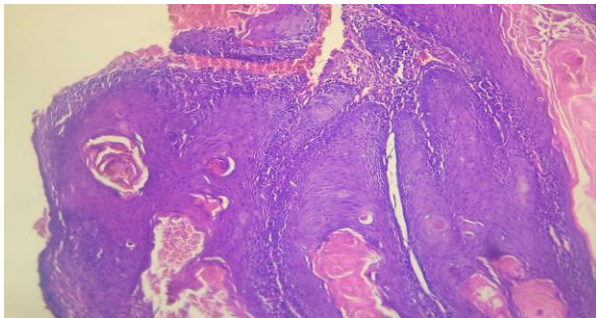
Laboratory investigations were within normal limits. Provisional clinical diagnosis of Squamous cell carcinoma of the lip was given. Biopsies from both the lesions were taken and submitted for histopathological confirmation.

Hematoxylin and eosin stained sections showed stratified squamous epithelium infiltrating into the connective tissue with extensive keratinization in the form of plugging (Fig. 2a, 2b). The epithelium showed dysplastic features like basilar hyperplasia, acanthosis, increased nuclear cytoplasmic ratio and prominent nucleoli. The underlying connective tissue showed chronic inflammatory infiltrate predominantly lymphocytes and plasma cells. Few keratin pearls and mitotic figures were also evident (Fig. 3). Histopathological features confirmed the provisional

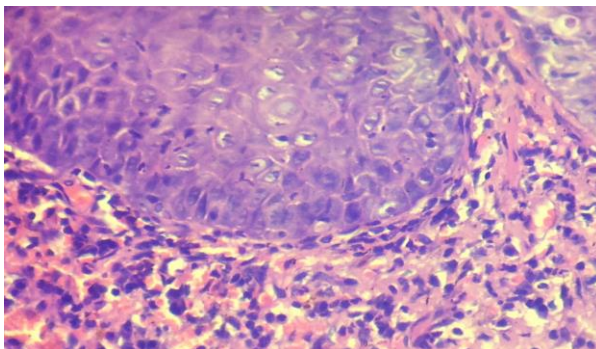
diagnosis of squamous cell carcinoma of the lip and the lesion was graded as moderately differentiated. Based on the histopathological features, anatomical location and the time of occurrence, a final diagnosis of synchronous oral squamous cell carcinoma was given as the second lesion on the lower lip developed within 3 months of duration from the index tumor (upper lip).



**Fig. 2a: Photomicrograph showing extensive keratinization and keratin pearls (H & E x4)**



**Fig. 2b: Photomicrograph showing extensive keratinization and keratin pearls (H & E x10)**



**Fig. 3: Photomicrograph showing basilar hyperplasia and mitotic figures (H & E x40)**

Chemotherapy with methotrexate followed by surgical excision of the lesions (upper & lower lips) was performed. The patient is under regular follow-up from 6 months after the surgery and no signs of recurrence were observed till date.

### Discussion

The incidence, morbidity and mortality of head and neck squamous cell carcinoma remains a serious public health issue. Despite relatively early diagnosis, treatment and accessible anatomical surveillance, Oral

Squamous cell carcinoma (OSCC) continues to have poor outcomes including poor overall survival.<sup>(4)</sup>

The most important risk factors for OSCC are use of tobacco or betel quid and the regular drinking of alcoholic beverages. However, infection with high-risk human papillomavirus (HPV) geno-types, and a diet low in fresh fruits and vegetables have also recently been implicated in the etiopathogenesis of OSCC. The highest incidence and prevalence of OSCC is found in the Indian subcontinent where the risk of developing OSCC is increased by the prevalent habits of chewing tobacco, betel quid and areca nut.<sup>(6)</sup>

The criteria to identify synchronous tumors of any site defined by Warren, Gates and Moertel et al. include the following: (1) all the tumors had to be histologically malignant; (2) all had to be distinct masses separated by normal tissue (at least 2 cm); (3) the possibility that the tumors could be metastatic had to be excluded histologically (4) secondary lung lesions had to be solitary and histologically distinct from the primary tumour.<sup>(7,8)</sup>

Current understanding of the origin of these second tumors is limited. Two possibilities exist: (a) either the tumors arise independently after transforming events in separate cells (the field cancerization theory); or (b) alternatively, the tumors develop from a single clone, with cells migrating to different sites (clonal or patch theory).<sup>(9)</sup>

According to field cancerization theory, large areas of the aero-digestive tissue are affected by long-term exposure to carcinogens leading to the formation of preconditioned epithelium. In this preconditioned epithelium, multifocal carcinomas can develop as a result of independent mutations, which would not be genetically related.<sup>(4)</sup>

As per the clonal or patch theory, a single cell, altered by inactivation of a tumor suppressor gene(s) and/or activation of an oncogene(s), forms a "patch," a clonal unit of altered daughter cells. This patch will transform and give rise to one large, extended, premalignant field by clonal expansion and it gradually replaces the normal mucosa. In this field of various sub-clones, two separate tumors can develop after the accumulation of additional genetic alterations. Thus both the tumors will have the same clonal origin and would share at least one early genetic event, which occurred before the initial clonal expansion.<sup>(4)</sup>

Investigations at the molecular level led to the new terminology 'second field tumors' (SFTs) which are anatomically distinct but demonstrate genetic similarities. SFT is defined as a tumor that has developed from the same field as the index tumor has developed. In case of SPTs, second tumor develops independently from the index tumor while in SFTs, second tumor develops in the same field of first tumor. Thus, SFTs can be differentiated from SPTs.<sup>(10)</sup>

Another possibility can be explained by the theories related to collision tumors where two morphologically distinct tumors arise in contiguity. According to this theory, in experimental animals, 'horizontal recruitment' was proposed. In our case, we would like to propose a possibility of a 'vertical recruitment' where the index tumor (upper lip) induced

tumor formation at the site of transplantation in the lower lip as both the lips are in contiguity.<sup>(11)</sup>

Studies that reported synchronous squamous cell carcinoma which occurred on the lip is given below (Table 1).

**Table 1: Studies reporting synchronous squamous cell carcinoma of the lip**

Sl. No.	Author / Population Studied	Total cases of SPTs (Synchronous & Metachronous)	Site	Age	Gender		Habits	Total cases of synchronous SCC	Cases of synchronous SCC ( ONLY LIP)
					Male	Female			
1.	F. Cianfriglia et al <sup>[8]</sup> Italian population	28	Oropharynx – 5 (17.85%) Oral cavity – 11(39.2%) Lip – 2 (7.14%) Larynx – 2 (7.14%) Stomach – 2 (7.14%) Lung – 3 (10.71%) Kidney – 1 (3.57%) Pancreas – 1 (3.57%) Rectum – 1 (3.57%)	> 65 years - 8 (28.57%) 55 – 64 years – 10 (33.71%) < 55 years – 10 (35.71%)	22 (78.57%)	6 (21.42%)	Yes – 21 (75%) No – 7 (25%)	4 (14.28%)	2(50 %)
2.	C.T. Liao et al <sup>[12]</sup> Taiwan population	30	Tongue - 10 (33.3%) Lip - 4 (13.3%) Buccal - 8 (26.7%) Gum - 2 (6.7%) Hard palate - 2 (6.7%) Retromolar - 2 (6.7%) Soft palate - 2 (6.7%)	>40 years – 27 (90%) < 40 years – 3 (10%)	30 (100%)	0 (0%)	Yes – 27 (90%) No – 3 (10%)	22 (36.14%)	4 (18.18 %)
3.	Dissanayaka et al <sup>[13]</sup> Sri Lankan population	28	Right & left buccal mucosae - 11 (39.3%) Lip & buccal mucosa- 3 (10.7%) Palate & buccal mucosa - 2 (7.1%) Right & left lateral tongue - 2 (7.1%) Commisure & retromolar - 2 (7.1%) Other non- oral regions - 8 (28.6%)	> 40 years – 27 (96.42%) < 40 years – 1 (3.58%)	21 (75%)	7 (25%)	-	28	3 (10.71 %)

Synchronous squamous cell carcinoma frequently occurs in oral cavity (39%) with incidence rates of the lip ranging from 10 – 18%.<sup>(12,13)</sup> In the present case, lesions occurred on the upper and lower lip. There was a male preponderance with a male-to-female ratio of synchronous OSCC as 3:1<sup>(8,12)</sup> which coincides with our case. About 90% of patients with synchronous OSCCs were of an elderly age group<sup>(8,12,13)</sup> which does not correlate with our patient's age, which belonged to a much younger age. Major risk factors for synchronous OSCC includes tobacco and betel quid chewing habits (75-90%)<sup>(8,12)</sup> which coincides with the present case who also had the habit of tobacco chewing.

Clinical differential diagnosis includes actinic keratosis and keratoacanthoma. Actinic keratosis is seen commonly in whites who are exposed to prolonged sunlight. Keratoacanthoma is a self-limiting lesion which is caused mainly due to HPV, prolonged sun exposure and it has a rare occurrence on the lips.<sup>(14)</sup>

Surgical excision is the treatment of choice for Synchronous OSCCs along with chemoradiotherapy.

### Conclusion

Synchronous OSCCs are aggressive in nature with early metastasis. Systematic follow-up and organ checkup are indicated which will help in detecting new tumors when they are in their initial stage of development so that they can be treated with a high likelihood of cure.

### References

1. Markopoulos AK. Current aspects on oral squamous cell carcinoma. *Open Dent J.* 2012;6:126–30.
2. Sankaranayanan R, Ramadas K, Thomas G et al. Effect of screening on oral cancer mortality in Kerala, India: a cluster-randomized controlled trial. *The Lancet* 2005;365(9475):1927-33.
3. Farhadieh et al. *J Cancer Sci Ther* 2011, Second Primary Tumours Of The Head And Neck Are Not Associated With Adverse Overall Survival In Oral Squamous Cell Carcinomas. *J Cancer Sci Ther* 2011;3(2):30-34.
4. Raviraj Jayam. Oral field cancerization: A review. *J IAOMR* 2010;22(4):201-05.
5. Pisani P, Bray F, Parkin DM. Estimates of the world-wide prevalence of cancer for 25 sites in the adult population. *Int J Cancer* 2002;97:72-81.
6. Feller L, Lemmar J. Oral Squamous Cell Carcinoma: Epidemiology, Clinical Presentation and Treatment. *Journal of Cancer Therapy* 2012;3:263-68.
7. Kiran Kumar et al. Synchronous oral squamous cell carcinomas with unusual histopathological feature. *J Oral Maxillofac Pathol* 2012;16(3):420–24.
8. Cianfriglia F, DiGregorio DA, Manieri A. Multiple primary tumours in patients with oral squamous cell carcinoma. *Oral Oncol* 1999;35:157-63.
9. Andrea G. M. et al. Synchronous Oral Carcinomas: Independent or Common Clonal Origin. *Cancer research* 1998;58:2003-06.
10. Braakhuis BJ, Tabor MP, Kummer JA, Leemans CR, Brakenhoff RH. A genetic explanation of Slaughter's

- concept of field cancerization: evidence and clinical implications. *Cancer Res.* 2003;63(8):1727-30.
11. Ravindra K. Vegunta, Raffaella A. Morotti, William E. Shiels II, Amanda Rauck, Gail E. Besner. Collision tumors in children: A review of the literature and presentation of a rare case of mesoblastic nephroma and neuroblastoma in an infant. *Journal of Pediatric Surgery* 2000;35(9):1359–61.
  12. Liao CT, Kang CJ, Chang JT, Wang HM, Ng SH, Hsueh C. Survival of second and multiple primary tumors in patients with oral cavity squamous cell carcinoma in the betel quid chewing area. *Oral Oncol.* 2007;43(8):811-9.
  13. Dissanayaka WL, Jayasooriya PR, Kumarasiri PV, Tilakaratne WM. A histopathologic comparison between synchronous and single primary oral squamous cell carcinomas. *Oral Surg Oral Med Oral Pathol Oral Radiol Endod* 2010;109:732-8.
  14. Wood NK, Goaz PW. *Differential diagnosis of oral and maxillofacial lesions.* 5th ed. Missouri: Mosby; 2006:136-8.